

A Foreign Body Embedded in the Gingiva of the Mandibular Posterior Region in a 13.5-Month-Old Child: A Case Report

F. Behzadpour (DDS)¹ , B. Vahidi (DDS)¹ , M. Ghasempour (DDS, MS)^{*2} 

1. Student Research Committee, Babol University of Medical Sciences, Babol, I.R.Iran.

2. Oral Health Research Center, Health Research Institute, Babol University of Medical Science, Babol, I.R.Iran.

Article Type	ABSTRACT
Case Report	<p>Background and Objective: Children may insert foreign objects into their oral cavity, which can lead to hard and soft tissue injuries. These foreign bodies can act as a potential source of infection and later lead to painful conditions in the child. The purpose of this article is to report an unusual case of oral swelling due to an embedded foreign body.</p> <p>Case Report: The patient is a 13.5-month-old boy who referred with his parents complaining of a bright red swelling measuring about 1×1 cm in the area of the first molar on the right side of the mandible. This bump appeared suddenly, had a firm consistency and a smooth surface and was painless. In the periapical radiograph, the deciduous first molar tooth was seen growing and no abnormality was seen. Due to the strong adhesion of the lesion to the underlying mucosa, the attempt to isolate the lesion using a catheter was not successful. Due to the unusual appearance of the lesion and the child's non-cooperation, a conservative approach was adopted and follow-up for the lesion was considered. In the follow-up within two weeks, the foreign body was separated from the gingival tissue by itself, and the eruption of the lower tooth took place naturally two weeks later.</p> <p>Conclusion: The results of this study show that in clinical conditions with an unusual appearance and unknown etiology, foreign bodies should be considered as a differential diagnosis in children and early invasive treatments should be avoided as much as possible.</p> <p>Keywords: <i>Foreign Body, Cyst, Primary Tooth.</i></p>
Received: Jun 6 th 2023	
Revised: Jul 3 rd 2023	
Accepted: Jul 26 th 2023	

Cite this article: Behzadpour F, Vahidi B, Ghasempour M. A Foreign Body Embedded in the Gingiva of the Mandibular Posterior Region in a 13.5-Month-Old Child: A Case Report. *Journal of Babol University of Medical Sciences*. 2023; 25(1): 365-71.



© The Author(S).

Publisher: Babol University of Medical Sciences

*Corresponding Author: M. Ghasempour (DDS, MS)

Address: Oral Health Research Center, Health Research Institute, Babol University of Medical Science, Babol, I.R.Iran.

Tel: +98 (11) 32291408. E-mail: ma_ghasempour_ir@yahoo.com

Introduction

A wide range of developmental and morphological anomalies can occur in the oral cavity of infants and children (1). The foreign body embedded in the oral cavity has rarely been considered in studies because usually the foreign bodies are superficially placed in the mouth and are easily removed by the patient or parents or the dentist (1, 2). These foreign bodies may get stuck in any of the body cavities, including the nose, ears, throat, and airways (1). The most common place for foreign objects to be hidden is the nasal cavity (3). The results of Francis et al.'s study on 215 children with a history of foreign body embedded in the nose showed that children aged 0-4 years had the highest rate of involvement and most of the foreign bodies embedded in the nose were removed outpatient (80% of cases) without the need for general anesthesia (4).

Other common sites in the oral cavity include the tongue, root canal, hard palate, tonsils, and oropharynx (3). The most common foreign objects embedded in the oral cavity include fish bones, metal objects, and broken pieces of teeth (1, 5). Foreign bodies may be visible based on their proximity to the surface where they are embedded or their inherent radiodensity using radiography. For example, metal objects are opaque in radiography, while wooden and plastic parts are usually not opaque and cannot be detected in radiography (3, 6, 7). Khandelwal et al. reported the embeddedness of pencil lead in the maxillary anterior tooth of a 13-year-old girl, which caused pain and discomfort in patient and was radiopaque in the radiograph (8).

In a report published by the US Poison Control Center, 66,519 cases of foreign body ingestion were reported in children under 5 years of age (9). Foreign body can cause problems such as abscess formation, septicemia, chronic inflammation, severe hemorrhage, and might even lead to distant ambulation. In addition, there is a risk of aspiration in children (3). Aspiration of a foreign body is the cause of 10-20% of morbidity and 7% of accidental death of children under 4 years of age (10). Regardless of the type of embedded foreign body, the foreign body may lead to tissue deformity and worry parents (1). The clinical manifestation of oral mucosa in which the foreign body is embedded varies depending on the type of foreign body and the involved area, and may range from a mucosal discoloration like amalgam tattoo to white and red lesions with or without a lichenoid pattern (as seen in foreign body gingivitis) to the formation of nodules or tumor-like lesions. The lesion may be painful or painless (11). The aim of this report is to present a case of a foreign body embedded in the gingiva with an unusual clinical appearance that made the child's parents concerned.

Case Report

This case is presented after being approved by the ethics committee of Babol University of Medical Sciences with code IR.MUBABOL.HRI.REC.1402.029. The parents of a 13.5-month-old boy brought him to the pediatric dentistry department, Dentistry Faculty of Babol University of Medical Sciences. The main complaint of the child according his mother was sudden appearance of a bright red bump in the posterior region of mandible. The clinical appearance of the lesion caused great concern to the parents. In terms of medical history, the child did not have any systemic disease. According to the mother's statement, this bump suddenly appeared in the child's mouth the night before and was painless, but the child felt a little uncomfortable while feeding. No abnormality was observed in extraoral examination. In the intraoral examination, the central and lateral deciduous teeth of the maxilla and the central deciduous tooth of the mandible were erupted. A swelling with firm consistency and smooth surface, light red in a size of about

1×1 cm was observed in the area of the first primary molar on the right side of the mandible. The gingiva around the lesion had normal color and consistency (Figure 1). In the periapical radiograph, an erupting first molar tooth was observed (Figure 2).

According to the clinical and radiographic characteristics as well as the patient's age, the primary diagnosis was eruption hematoma, but the color of the lesion did not match the usual color of eruption hematoma, which is reddish-purple. The second differential diagnosis was the presence of a foreign body, but the mother did not remember any history of the foreign body. At the same time, an attempt was made to remove this tissue with a dental probe, but due to strong adhesion to the underlying mucosa and the child's lack of cooperation, success was not achieved. Considering the absence of pain and disturbance in the child's nutrition, it was decided to adopt a conservative follow-up process.

A week later, the child was re-examined and no change was observed in the clinical appearance, but the child's feeling of discomfort during feeding was resolved. Due to parents' non-cooperation for face-to-face visits, future follow-ups were done by phone. One week after the first follow-up, the mother stated that a piece of the "Pop It" toy came out of the child's mouth and the gingiva appeared normal (Figure 3). "Pop It" is a kind of toy loved by children, which is made of silicone and reduces the child's stress (Figure 4). Two weeks after the removal of the piece of toy, the primary first molar tooth grew normally. In an examination six months later, the clinical appearance of the gingiva was normal and no special problem was observed (Figure 5).

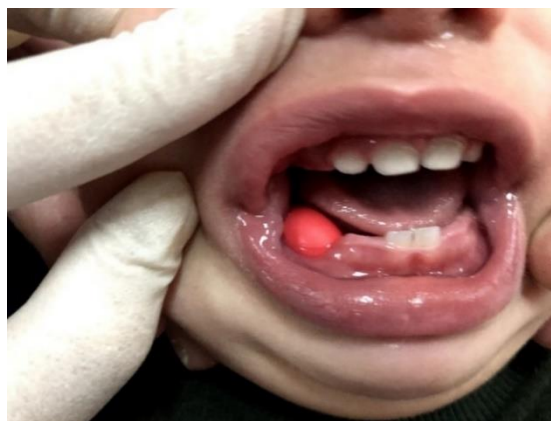

Figure 1. light red swelling in the first molar area

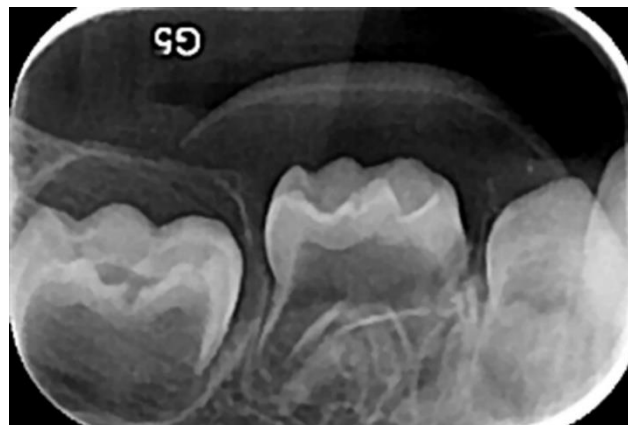


Figure 2. radiography of the first molar area



Figure 3. The piece taken out of the child's mouth



Figure 4. "Pop It" toy

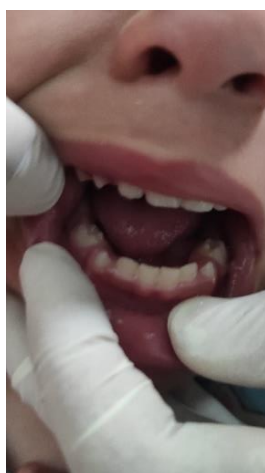


Figure 5. Clinical appearance of the child's mouth in the follow-up six months later

Discussion

In the reported case, due to the child biting on the "pop it" toy, a piece of it was separated and pressed on the child's gingiva and it could not be easily removed, and this made the diagnosis of the presence of a foreign body doubtful. Considering that the age of the child was within the range of the growth time of the mandibular first molar, there was a possibility of eruption hematoma in this area, but eruption hematoma is usually seen in a reddish-purple color. The radiograph prepared from the target area also showed the normal development of the first primary molar tooth without any suspicious cases. Considering the normal appearance of the radiograph and the absence of severe symptoms, it was decided to follow up the lesion on a weekly basis. After two weeks, the embedded object was separated from the gingiva while eating.

Children, especially at a young age, often have the habit of putting foreign objects in their mouths, which can be accidentally embedded in the oral cavity. These objects may be superficially placed in the mouth and can be easily removed by the patient, parents or dentist. On the other hand, there is also possibility of swallowing these objects (1, 2). Syahputra et al. presented a case report of removing an embedded earring from the upper third of the esophagus of a 28-day-old baby under general anesthesia (12). There is also the possibility of foreign objects entering the airway and severe discomfort (1, 2, 7, 13, 14). Goh et al. reported a case of bronchopneumonia in a 2-year-7-month-old girl due to the aspiration of a hazelnut. This foreign body was removed by bronchoscopy (10). Nasir et al., in a review article, stated that 75% of aspiration cases occurred in children under 3 years of age, and the most common clinical symptoms were choking (82%) and stridor (31%). Younger children have longer hospital stays (15).

Foreign bodies that are embedded in the soft tissue of the gingiva or soft palate can cause inflammation, scarring, infection, granuloma formation, pain, abscess, swelling and tumor-like appearance (14). Shahrabi et al. reported a case of recurrent painless swelling in the maxillary anterior vestibule in a 50-year-old man. The lesion was present for two years. After removing the lesion and histological evaluation, it was found that a fragment of an explosive bullet entered the gingival tissue and led to formation of a cyst-like nodule in the patient's mouth (11). Vegesna et al. reported the presence of a plastic ring-like foreign body around the central mandibular teeth of a 15-month-old child, which led to severe inflammation of the periodontium and loosening of the involved teeth (7). According to previous studies, it seems that due to curiosity and tendency to put foreign bodies in the mouth, children have a higher risk for trauma caused by embedded foreign bodies (7, 10, 12, 16, 17).

In the present study, according to the mentioned conditions and the fact that eruption hematoma was considered as one of the differential diagnoses, a decision was made to periodically evaluate and prevent unnecessary invasive treatment. In the study of Tavargeri et al., a lesion with an unusual clinical appearance was observed in the maxillary tuberosity area of a 6-month-old child. Due to the suspicion of hemangioma and the child's non-cooperation, general anesthesia was performed to evaluate this lesion, and the foreign body (plastic toy) was eventually removed from the area (16). In a study by Abramowsky, an abnormal lesion was observed in the palate of a 6-month-old baby, which was initially mistakenly diagnosed as a tumor-like lesion, but finally, after histological examination, the final diagnosis was the presence of a foreign body (17). In many reports, artificial nails and pistachio skin embedded in the palate were wrongly diagnosed as tumors (18-21). According to the results of these studies, it seems that in children, especially at a young age, it is necessary to act conservatively as much as possible in the treatment of lesions with unknown etiology.

The results of this study show that in clinical conditions with unusual appearance and unknown etiology, foreign bodies should be considered as a differential diagnosis in children and early invasive treatments should be avoided as much as possible. Parents should remove small objects from the reach of children as

much as possible and be more careful in choosing toys. Anticipatory guidance can be useful in preventing emergency cases and timely intervention.

Acknowledgment

The colleagues of the Department of Oral and Maxillofacial Surgery and Oral and Dental Pathology of Babol University of Medical Sciences are hereby thanked for their valuable consultation.

References

1. Anthonappa RP, King NM. An unusual white lesion in a 10-month-old child. *Dent Update*. 2010;37(2):110-4.
2. Tseng E, Woolley AL. Foreign body simulating a hard palate lesion in a child. *Int J Pediatr Otorhinolaryngol*. 1996;38(2):169-74.
3. Ali FM, Moafa MI, Khadhi AH, Korairi SA, Khardali AJ, Zangot A, et al. Self-Inflicted Foreign Body Impaction in the Mucobuccal Fold of Maxillary Posterior Region in the Oral Cavity: A Case Report. *Saudi J Oral Dent Res*. 2021;6(11):523-5.
4. Francis PM, Adekanye AG, Mgbe RB, Offiong ME, Enyuma CO. Paediatric nasal foreign body in Calabar: A review of 5 -years experience. *Niger J Med*. 2020;29(1):20-3.
5. Cao L, Chen N, Chen Y, Zhang M, Guo Q, Chen Q, et al. Foreign body embedded in the lower esophageal wall located by endoscopic ultrasonography: A case report. *Medicine (Baltimore)*. 2018;97(26):e11275.
6. Verma A, Singla S, Ahmaed S. Foreign body in the mandibular buccal sulcus: a case report. *Int J Appl Dent Sci*. 2019;5(3):101-2.
7. Vegesna M. An Unusual Foreign Object Encircling Primary Teeth: A Case Report. *Dent*. 2021;4(2):128-30.
8. Khandelwal D, Kalra N, Tyagi R, Khatri A. Accidental diagnosis of a foreign body embedded in maxillary anterior tooth. *J Sci Soc*. 2019;46(3):103-5.
9. Agha RA, Franchi T, Sohrabi C, Mathew G, Kerwan A, Thoma A, et al. The SCARE 2020 Guideline: Updating Consensus Surgical CAse REport (SCARE) Guidelines. *Int J Surg*. 2020;84:226-30.
10. Goh PL, Lim EH, Teo DSHM, Sairin ME. Challenges in Diagnosing Foreign Body Aspiration in Children. *Cureus*. 2022;14(1):e21519.
11. Shahrabi-Farahani S, Atarbashi-Moghadam S, Lotfi A, Atarbashi-Moghadam F. Oral cyst-like nodule caused by a long standing unusual embedded foreign object: Report of a case. *Trauma Case Rep*. 2020;25:100261.
12. Syahputra DA, Kusmayadi DD, Indriasari V, Kusumowidagdo F. Unusual esophageal foreign body in neonates: A case report. *Int J Surg Case Rep*. 2021;85:106236.
13. Azodo CC, Erhabor P, Chukwumah NM, Ogordi P. Intraoral foreign body: A case report and review of literature. *Indian J Multidiscip Dent*. 2015;5(2):97-9.
14. Chandran N, Sudeep CB, Johnny J, Yerragudi N. Foreign body in maxillary deciduous first molar—a case report. *Int J Contemp Med Res*. 2020;7(6):F4-F5.
15. Nasir ZM, Subha ST. A Five-Year Review on Pediatric Foreign Body Aspiration. *Int Arch Otorhinolaryngol*. 2021;25(2):e193-e9.
16. Tavargeri AK, Rao CB, Thakur S. Foreign body in the mouth and the dilemma in diagnosis: a case report. *J Calif Dent Assoc*. 2010;38(7):512-3.
17. Abramowsky ZL. Foreign body on the palate of an infant: report of case. *J Am Dent Assoc*. 1971;83(6):1329.
18. Johnson JT, Mink JR. Acrylic artificial fingernail embedded in the palate of an 11-month-old: a case report. *J Dent Child (Chic)*. 2005;72(3):107-8.
19. Vogeley E. Danger of artificial nails. *Pediatrics*. 1999;104(1 Pt 1):132.
20. Sobol SE, Jacobs IN, Levin L, Wetmore RF. Pistachio nutshell foreign body of the oral cavity in two children. *Int J Pediatr Otorhinolaryngol*. 2004;68(8):1101-4.
21. Gupta S, Mehra M, Grover R, Gupta T. Foreign Body Embedded in Gingiva of Maxillary Anterior Region in A 2 Year Old Child: A Case Report. *Indian J Compr Dent Care (IJCDC)*. 2014;4(2):467-9.