

A Case Report of Tuberculosis with Extrapulmonary Manifestations

S. Gazeran (MD)¹, M. Emami (MD)¹, F. Zemorshidi (MD)^{*1}

1. Department of Neurology, Faculty of Medicine, Mashhad University of Medical Sciences, Mashhad, I.R. Iran

J Babol Univ Med Sci; 21; 2019; PP: 378-82

Received: Apr 21st 2019, Revised: June 22nd 2019, Accepted: July 10th 2019.

ABSTRACT

BACKGROUND AND OBJECTIVE: *Mycobacterium tuberculosis* affects millions of people in the world and Iran is one of the endemic areas. This disease has a wide range of manifestations, which is pulmonary in 80 – 85% of cases and extrapulmonary in 15 – 20% of cases. The most notable extrapulmonary infection sites are lymph nodes, pleura, genitourinary system and digestive system. Considering the prevalence of tuberculosis in Iran, familiarity with the uncommon manifestations of this infection seems to be essential for timely diagnosis and treatment. Therefore, a rare extrapulmonary manifestation of tuberculosis is reported here.

CASE REPORT: The patient was a 64 – year – old woman who was hospitalized due to fever, icterus, decreased consciousness and progressive asymmetrical weakness of the limbs. Symptoms of focal neurologic deficits and heart murmurs were found in examinations. During the tests, including brain and spinal imaging, cerebrospinal fluid analysis, computed tomography of the abdomen and pelvis, and echocardiography, extrapulmonary tuberculosis (cerebral abscess, spondylitis, liver and spleen abscess, psoas muscle abscess, and possible endocarditis) was confirmed. Four-drug regimen including isoniazid, rifampin, ethambutol, and pyrazinamide with vitamin B6 was started for two months, and two-drug regimen continued for 10 months. At the end of the course of treatment, the patient was able to walk with the cane in good general condition.

CONCLUSION: Considering the reported case, paying attention to some of the more uncommon manifestations of the disease can prevent mortality and disability.

KEY WORDS: *Mycobacterium Tuberculosis, Extrapulmonary, Spondylitis, Psoas Abscess.*

Please cite this article as follows:

Gazeran S, Emami M, Zemorshidi F. A Case Report of Tuberculosis with Extrapulmonary Manifestations. J Babol Univ Med Sci. 2019; 21: 378-82.

*Corresponding Author: F. Zemorshidi (MD)

Address: Department of Neurology, Qaem Hospital, Mashhad University of Medical Sciences, Mashhad, I.R. Iran.

Tel: +98 51 38429828

E-mail: ZemorshidiF@mums.ac.ir

Introduction

Tuberculosis is the most common cause of death from single – agent infectious diseases in the world, and despite medical advances it is still one of the major health problems. It is the tenth most common disease worldwide and is projected to rise to seventh rank by year 2020. Given the priority of tuberculosis control programs, the World Health Organization has set targets for disease control, the most important of which is to reduce the prevalence of tuberculosis in the world to 50% of its prevalence in 1990 – 2015, and to reduce the rate of mortality due to active tuberculosis (TB) to 1/1,000,000 people by 2050 (1, 2).

According to the Ministry of Health, 14.4/100,000 people in Iran are infected with tuberculosis every year (3). In 2017, 8819 people had different forms of tuberculosis in Iran; 46% were female patients and 14.7% were non-Iranian patients. The highest incidence of tuberculosis was in the age group of 65 years and above, and 2362 people had extrapulmonary tuberculosis. Tuberculosis is divided into categories of pulmonary and extrapulmonary, and extrapulmonary tuberculosis involves organs such as the lymph node, nervous system, digestive system, joints, bones and other organs (4). Tuberculosis has a wide range of clinical manifestations, including 80 – 85% pulmonary and 15–20% extrapulmonary. The most common extrapulmonary sites of tuberculosis are lymph nodes, peripheral membranes, genitourinary system, digestive system and central nervous system (5 – 7).

Involvement of central nervous system is one of the most destructive manifestations of tuberculosis, which includes tuberculous meningitis and, more uncommonly, tuberculous encephalitis, intracranial tuberculosis or tuberculous brain abscess (8). Given the prevalence of tuberculosis in Iran, familiarity with the uncommon manifestations of this infection seems necessary for timely diagnosis and treatment. Therefore, a rare extrapulmonary manifestation of tuberculosis is reported here.

Case Report

The patient is a 64-year-old female resident of Kalateh village of Torbat-e Jam who underwent treatment in Taleqani Hospital with the differential diagnosis of hepatic encephalopathy (considering the

increased liver enzymes) due to limb weakness, fever, decreased level of consciousness and urinary retention about two weeks ago. After discharge, she was referred to Qaem Hospital in Mashhad due to exacerbation of symptoms. At the time of admission, the heart rate was 88 per minute and respiratory rate was 25 per minute and body temperature was 38 °C.

Systemic examinations found scleral icterus, systolic heart murmur in the mitral valve, decreased lung sounds, and cervical spine tenderness. On examination of the nervous system, the patient was confused and unaware of the place and time. Slight asymmetrical nasolabial folds in the left side, decreased limb strength in the left side, decreased deep tendon reflexes, and bilateral extensor plantar reflex were also found. In initial tests, peripheral blood leukocyte counts were reported to be 6200 per μ l with 84% neutrophils, 10 g / dl hemoglobin, 120,000 per μ l platelet, and red blood cell sedimentation of 70. Total bilirubin was 3.2 mg/dl and direct bilirubin was 1.4 mg/dl, aspartate aminotransferase and alanine aminotransferase were respectively 30 and 47 units per liter, and alkaline phosphatase was 545 units per liter. Three times of blood cultures were reported negative.

Chest X-ray and CT scan showed increased cardiothoracic ratio and ascending aortic arch and mild bilateral pleural effusion with the prominence of the left side. Pleural fluid paracentesis confirmed transudate fluid and negative culture and smear. After gadolinium injection along with leptomeningeal uptake, a few lesions had nodular and annular uptake patterns. MRI of the cervical spinal cord revealed edema and signal changes in the C6–C7 and C3 – C4 discs, with increased uptake of the contrast agent by disc and epidural in the posterior vertebral body line without significant compressive effect suggesting spondylodiscitis. Due to multiple lesions with cyclic and annular uptake, infectious causes, especially tuberculosis and metastatic lesions, were among the top differential diagnoses. The patient underwent lumbar puncture with a leukocyte count of 175 and 70% mononuclear cells, 7,500 red blood cells per cubic millimeter, 406 mg/dl protein and 25 mg/dl glucose. PCR sample was positive for tuberculosis. In triple-phase abdomen and pelvis computed tomography, a focus with irregular margins of 16 × 30 mm in liver segment VII in isodense form was observed in contrast-free and arterial phase and

hypodense was observed in the portal phase, while increased uptake of contrast in annular form was observed in delayed post-contrast phase, which suggested tuberculosis abscess. Several abscess foci were found in the spleen. Multilocular hypodense masses with liquid density and increased uptake of parietal contrast in the psoas muscles on both sides of the abscess were observed (Fig 1). Psoas abscess was drained under ultrasound guidance and PCR and culture of tuberculosis were positive. Considering the psoas abscess and the possibility of its extension, lumbar spondylosis of the lumbar spine was evaluated, and narrowing intervertebral disc space and anterior wedging were found in lumbar vertebrae L3 and L4. Changes in hip osteoarthritis were also observed regarding tuberculosis.

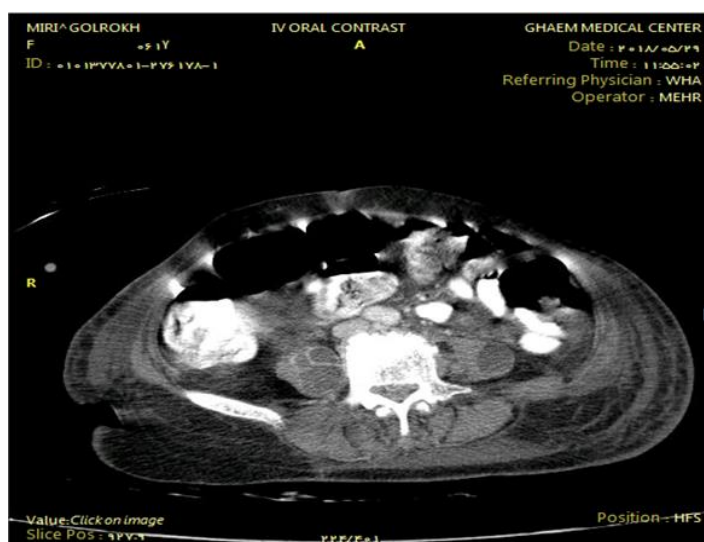


Figure 1. Bilateral Psoas Muscle Abscess in CT Scan Image

In transthoracic echo, evidence of mitral valve insufficiency as well as removable mass was observed that primarily indicated ruptured chordae and less likely showed vegetation. Cardiac surgery consultation was done, but due to inappropriate clinical status and patient's dissatisfaction with surgery, drug treatment was recommended. Considering the results of the examinations as well as positive PCR of cerebrospinal fluid (Fig 2), the patient was diagnosed with disseminated extrapulmonary tuberculosis with manifestations of cerebral abscess, spondylitis, liver and spleen abscess, psoas muscle abscess, hip osteoarthritis and possible endocarditis. Four-drug regimen including

isoniazid, rifampin, ethambutol, and pyrazinamide with vitamin B6 was started for two months, and two-drug regimen continued for ten months. At the end of the course of treatment, the patient was able to walk with the cane in good general condition.

Test Name	Result	Unit	Reference Value
TR-PCR			
PCR Process For	Mycobacterium tuberculosis (MTBC)		
Results:	Mycobacterium Tuberculosis Complex DNA Was Detected.		
Comment 1:	This assay shows the presence of Mycobacterium tuberculosis complex DNA. But does not necessarily indicate the presence of viable organisms. Routine culture is recommended.		
	Lab Director		Page 1 of 1

Figure 2. Positive PCR of cerebrospinal fluid

Discussion

The MRI of the reported patient showed multiple foci of signal enhancement at the T2 and FLAIR sequences in the left cerebellar hemisphere, right basal ganglia, and multiple involvements of fronto-parieto-occipital cortex and subcortical regions in both hemispheres, some of which had diffusion restriction. One case of cerebral abscess reported by Ansari was a 17-year-old teenager who underwent surgical drainage due to compressive effect on the cerebellar hemisphere and the size of the abscess (1).

However, our patient did not undergo surgical drainage because of the multiplicity and size of the lesions and the lack of significant compressive effects. Muscular tuberculosis is a rare complication of infection that spreads from the primary focus due to lymphatic or hematogenous spread. This is usually the focus of osteomyelitis of the lumbar spine. Muscle involvement is rare due to high lactic acid content, lack of reticuloendothelial / lymphatic tissue and muscle perfusion. Diagnosis of psoas muscle abscess is often difficult due to the onset of ventricular and nonspecific manifestations and delayed diagnosis may lead to high pathogenicity.

Complications of psoas abscesses include septic shock, deep vein thrombosis due to pressure on the iliac veins, hydronephrosis and ileus (10, 11). Two cases of tuberculosis-induced psoas abscess were reported by Lombardi et al. and Shokouhi et al., who underwent

standard drainage and anti-tuberculosis treatment, and similar to our patient, responded to appropriate treatment (11, 12).

Most cases of tuberculous endocarditis have been reported in patients with miliary tuberculosis. There are two major advances in the diagnosis of tuberculous endocarditis that have led to the development of this complication, including the ability to find tuberculosis bacilli from the patient's heart valve after surgery and the use of echocardiography. Echocardiography is the first imaging device for all suspected cases of infectious endocarditis. Finding vegetation or mitral valve dysfunction may suggest endocarditis. Like all types of infectious endocarditis, definitive diagnosis is based on a set of clinical assessments, blood tests, imaging findings, and tissue culture.

This patient was also examined in terms of other infectious endocarditis, which was repeatedly negative for other organisms. Therefore, considering the sum of the patient's symptoms, tuberculosis endocarditis seemed likely. Positive echocardiographic findings, valve vegetation, positive tuberculosis culture in the

patient with clinical signs of endocarditis are enough to diagnose tuberculous endocarditis. Treatment of tuberculous endocarditis involves surgical replacement of the valve and treatment with anti-tuberculosis drugs (13). In one case, tuberculous endocarditis with involvement of three valves was reported by Shaikh et al., and the patient underwent valve replacement surgery and drug therapy (14), but in our patient no cardiac surgery was performed due to medical condition and patient dissatisfaction.

Tuberculosis is one of the most important infectious diseases of the last century which, despite the higher prevalence of pulmonary involvement, tends to affect other organs of the body. Therefore, given the prevalence of the disease in the region, more familiarity with the rarer manifestations of the disease will contribute to timely diagnostic and therapeutic measures.

Several uncommon extrapulmonary manifestations were found through systematic review in this study, and the symptoms of this patient improved dramatically with appropriate treatment.

References

1. Nasehi M, Mirhaghani L. National guide to tuberculosis control. Tehran: Andishmand Pub; 2009. p.5-21. [In Persian].
2. World Health Organization. Tuberculosis: WHO fact sheet no. 104 (Arabic, Chinese, English, French, Russian, Spanish). Available from: <https://www.who.int/en/news-room/fact-sheets/detail/tuberculosis>
3. World Health Organization. Global tuberculosis report. 2012. Available from: https://apps.who.int/iris/bitstream/handle/10665/75938/9789241564502_eng.pdf?sequence=1
4. Lee JY. Diagnosis and Treatment of Extrapulmonary Tuberculosis. *Tuberc Respir Dis (Seoul)*. 2015; 78(2): 47–55.
5. Pang Y, An J, Shu W, Huo F, Chu N, Gao M, et al. Epidemiology of extrapulmonary tuberculosis among Inpatient, China, 2008-2017. *Emerg Infect Dis*. 2019;25(3):457-64
6. Qian X, Nguyen DT, Lyu J, Albers AE, Bi X, Graviss EA. Risk factors for extrapulmonary dissemination of tuberculosis and associated mortality during treatment for extrapulmonary tuberculosis. *Emerg Microbes Infect*. 2018;7(1):102.
7. Kim JH, Kim ES, Jun KI, Jung HG, Bang JH, Choe PG, et al. Delayed diagnosis of extrapulmonary tuberculosis presenting as fever of unknown origin in an intermediate-burden country. *BMC Infect Dis*. 2018;18(1):426.
8. Rock RB, Olin M, Baker CA, Molitor TW, Peterson PK. Central Nervous System Tuberculosis: Pathogenesis and Clinical Aspects. *Clin Microbiol Rev*. 2008; 21(2): 243–61.
9. Ansari MK, Jha S. Tuberculous brain abscess in an immunocompetent adolescent. *J Nat Sci Biol Med*. 2014;5(1):170-2.
10. Masavkar S, Shanbag P, Inamdar P. Pott's Spine with Bilateral Psoas Abscesses. *Case Rep Orthop*. 2012;2012:208946.
11. Shokouhi Sh, Kazempour M, Bahrami-Motlagh H, Bidari Zerehpooosh F, Azhari V, Ebrahimi M. Delay in Diagnosis of Extra-Pulmonary Tuberculosis by Its Rare Manifestations: A Case Report. *Arch Clin Infect Dis*. 2015;10(4):e29874.
12. Lombardi R, Pelusi S, Airaghi L, Fargion S. Extrapulmonary tuberculosis: an unusual presentation in an immunocompetent patient. *BMJ Case Rep*. 2015; 6:2015. pii: bcr2014207146.
13. Liu A, Nicol E, Hu Y, Coates A. Tuberculous endocarditis. *Int J Cardiol*. 2013;167(3):640-5.
14. Shaikh Q, Mahmood F. Triple valve endocarditis by mycobacterium tuberculosis: a case report. *BMC Infect Dis*. 2012;12:231.