

An Evaluation of Changes in the Upper Lip Following Depressor Septi Nasi Muscle Resection in Rhinoplasty

S. H. Mousavi (DDS, MS)¹ , A. Babaei Darzi (DDS, MS)² , S. A. Seyedmajidi (PhD)³ ,
R. Foroughi (DDS, MS)^{*3} , M. Mansouri Zeyni (DDS, MS)¹ 

1. Student Research Committee, Babol University of Medical Sciences, Babol, I.R.Iran.

2. Oral Health Research Center, Health Research Institute, Babol University of Medical Sciences, Babol, I.R.Iran.

3. Dental Materials Research Center, Health Research Institute, Babol University of Medical Sciences, Babol, I.R.Iran.

*Corresponding Author: R. Foroughi (DDS, MS)

Address: Department of Oral & Maxillofacial Dentistry, School of Dentistry, Babol University of Medical Sciences, Babol, I.R.Iran.

Tel: +98 (11) 322291408. E-mail: raminomfs99@yahoo.com

Article Type

ABSTRACT

Research Paper

Background and Objective: The ability to predict the effect of different rhinoplasty techniques on changes in facial features is important. The present study was conducted to predict possible changes in the upper lip following depressor septi nasi muscle resection in order to make appropriate choices in rhinoplasty.

Methods: In this cross-sectional study, 22 rhinoplasty candidates who underwent surgery in hospitals and private clinics in Babol in 2022 were examined regarding changes in the upper lip after depressor septi nasi muscle resection. The length of the upper lip (from the columella to the upper edge of the vermilion of the upper lip), the vermilion view (from the upper edge of the vermilion to the lower end of the upper lip), and the anterior teeth (the lower edge of the vermilion to the lower incisor edge of the maxillary central incisors), and the gingival view (from the lower edge of the vermilion of the upper lip to the gingival zenith of the maxillary central incisors) were examined and compared between the time intervals before surgery, 14 days, 1, and 3 months after surgery using repeated measurements.

Findings: The mean length of the upper lip was 17.82 ± 3.05 mm before surgery, which significantly increased to 20.77 ± 3.22 mm 3 months after surgery ($p < 0.001$). The mean vermilion view also significantly increased from 6.50 ± 2.12 mm before surgery to 7.44 ± 2.30 mm 3 months after surgery ($p < 0.001$). The mean anterior teeth projection 3 months after surgery was 2.14 ± 1.13 mm, which was a significant decrease compared to 2.58 ± 1.43 mm before surgery ($p < 0.001$).

Conclusion: The results of the study showed that depressor septi nasi muscle resection increases the length of the upper lip and the view of vermilion, and reduces the view of the anterior teeth at rest and the gingiva when smiling. Therefore, a smile analysis is recommended for each individual before undergoing rhinoplasty.

Keywords: Rhinoplasty, Upper Lip, Depressor Septi Nasi Muscle, Muscle Resection, Anterior Teeth, Vermilion.

Received:

Jul 31st 2023

Revised:

Nov 22nd 2023

Accepted:

Dec 30th 2023

Cite this article: Mousavi SH, Babaei Darzi A, Seyedmajidi SA, Foroughi R, Mansouri Zeyni M. An Evaluation of Changes in the Upper Lip Following Depressor Septi Nasi Muscle Resection in Rhinoplasty. *Journal of Babol University of Medical Sciences*. 2025; 27: e62.

Introduction

The desire of every physician and the desire of every patient to have an attractive smile have led specialists to study the complex features of facial structures and their integrity. Smiling involves voluntary changes in facial muscles that convey social expressions of happiness, greeting, and pleasure. The essentials of a beautiful smile include the harmonious relationship of the teeth with facial structures such as the lip frame and the gingival framework. The presence of proportional external facial structures as well as appropriate proportion of natural teeth and gingival tissue are integral components of an attractive smile (1). Rhinoplasty alone or in combination with septoplasty is one of the fundamental management techniques in facial plastic surgery. However, plastic surgeons often focus on the cosmetic changes to the nose and ignore the effects of this procedure on the patient's upper lip and smile. Management of a gummy smile includes procedures such as orthodontic treatment, botulinum toxin injections into the relevant muscles, and surgery on the upper lip (2).

Smiling and facial expressions play an important role in how people communicate with their environment. Excessive or insufficient display of the maxillary incisors when smiling can disrupt facial harmony. Gummy smile is defined as more than 2 mm of visible gum tissue during smiling and may be considered aesthetically unpleasing. The ideal position of the upper lip is considered to be a gingival protrusion of 1 to 2 mm in full smile for women and less for men. Botulinum toxin treatment and injections are often used to manage a gummy smile. Rhinoplasty can resolve aesthetic problems with the nose and improve overall facial balance in patients with a gummy smile (3).

The depressor septi nasi muscle is a muscle located primarily within the columella, originating from the medial crural footplates and the caudal septum, and has variable attachment patterns in the orbicularis oris and nasal septum. The muscle is active during facial expressions such as speaking and smiling. During smiling, a functional unit is activated, resulting in downward rotation of the nasal tip and upward base of the nose, and shortening of the upper lip (2). In some patients, the function of depressor septi nasi muscle results in a change commonly referred to as “smile deformity,” which is characterized by a transverse crease located in the mid-philtrum area below the nose, shortening of the upper lip, and lowering of the nasal tip. Not all components are necessarily present in all cases. Instead, there is a spectrum of severity. A minor change in smile shape involves only lowering of the nasal tip. A moderate smile deformity involves movement of the nasal tip and shortening of the upper lip. A severe deformity involves all three components. The classification of smile deformity is directly related to the degree of hyperactivity of the depressor septi nasi muscle (1). The degree of tooth visibility is determined definitively by the muscle position at rest, while during a smile it is determined by the dynamic muscle position of the lips. It depends on the position of the upper and lower lips (4).

In rhinoplasty, surgeons usually focus on the shape of the nose and thus neglect the assessment of facial harmony and overall patient satisfaction. Structural harmony and facial balance are assessed based on the facial skeleton and adjacent soft tissue. The dentofacial complex is composed of the frontal and sagittal planes with static and dynamic muscle positions (5). The main aim of this study was to investigate the changes in the upper lip following depressor septi nasi muscle resection in rhinoplasty.

Methods

After approval by the Ethics Committee of Babol University of Medical Sciences with the code IR.MUBABOL.HRI.REC.1401.150, this cross-sectional study was conducted on 22 patients who were rhinoplasty candidates and underwent surgery in hospitals and private clinics in Babol in 2022. These

patients were assessed in terms of upper lip changes following depressor septi nasi muscle resection. The rhinoplasty procedure was performed in the same way in all patients, which was open rhinoplasty procedure. In order to access the depressor septi nasi muscle after transcolumellar and nasal skeleton incision, the nasal domes were divided, and the muscle was separated from the lower part of the septum and the muscle was removed. All surgeries were performed by the same surgeon.

This study is based on extraction of data and parameters recorded in the patient files, which included measuring and recording variables at different time periods. Parameters were evaluated before surgery, at the end of 14 days, after removal of sutures and external nasal splint on the seventh day and reduction of initial edema, at the end of one month and disappearance of initial tissue edema, and after three months at the time of final nasal shape and its effect on the upper lip. Furthermore, the examined studied parameters included length of the upper lip at rest (from the columella area to the upper edge of the vermilion of the upper lip), size of the vermilion view at rest (from the upper edge of the vermilion to the lower tip of the upper lip), size of the anterior teeth view at rest (lower edge of the vermilion to the lower edge of the maxillary central incisors), and gingival view (from the lower edge of the vermilion of the upper lip to the gingival zenith of the maxillary central incisors).

Patients aged 18 to 28 who underwent primary rhinoplasty for the first time in hospitals and private clinics in Babol in 2022 were included in the study. Patients with congenital defects of the lip and nose area, such as cleft lip and palate, people with a history of severe injuries in the midface, especially the upper lip and nose area, people with significant deviation and deformity in the lip and nose area, the middle part of the nose, and any cosmetic intervention in the target area, such as gel and filler injections, were excluded from the study.

Due to the patients' inability to smile, the degree of gingival view during smiling was not recorded 14 and 30 days after the operation. The required information was measured by the maxillofacial surgeon with an INSIZE caliper (with an accuracy of 0.1 mm) and demographic characteristics, including age and gender, were entered into the checklist through an interview. Finally, the data were analyzed with SPSS version 22. Data were presented using descriptive statistics indicators in the form of tables and graphs. To compare the mean value of the studied variables between the follow-up periods and before the operation compared with each of the follow-up periods, repeated measures and paired t-test were used if parametric conditions were met, and $p < 0.05$ was considered significant.

Results

In this cross-sectional study, 22 patients who were candidates for rhinoplasty and underwent surgery in hospitals and private clinics in Babol in 2022 were examined for changes in the upper lip following depressor septi nasi muscle resection. 11 patients (50%) were male and 11 patients (50%) were female. The mean age of men (23.73 ± 2.41 years) was higher than the mean age of women (20.09 ± 2.84 years) ($p = 0.004$). The mean length of the upper lip before surgery was 17.82 ± 3.05 mm, which significantly increased to 20.77 ± 3.22 mm 3 months after surgery ($p < 0.001$). Also, the mean length of the upper lip 14 days and one month after surgery was 23.23 ± 3.12 and 22.09 ± 3.04 mm, respectively.

The mean vermilion view also increased significantly from 6.50 ± 2.12 mm before surgery to 7.44 ± 2.30 mm 3 months after surgery ($p < 0.001$) (Table 1). The mean anterior tooth view during the study periods is shown in Table 2. The mean incisor view 3 months after surgery (2.14 ± 1.13 mm) was significantly reduced compared to before surgery (2.58 ± 1.43 mm) ($p < 0.001$) (Figure 1). The mean gingival view 3 months after surgery (1.35 ± 0.68 mm) was also significantly reduced compared to before surgery (1.57 ± 0.71 mm) ($p < 0.001$).

Table 1. Comparison of vermillion view between follow-up times

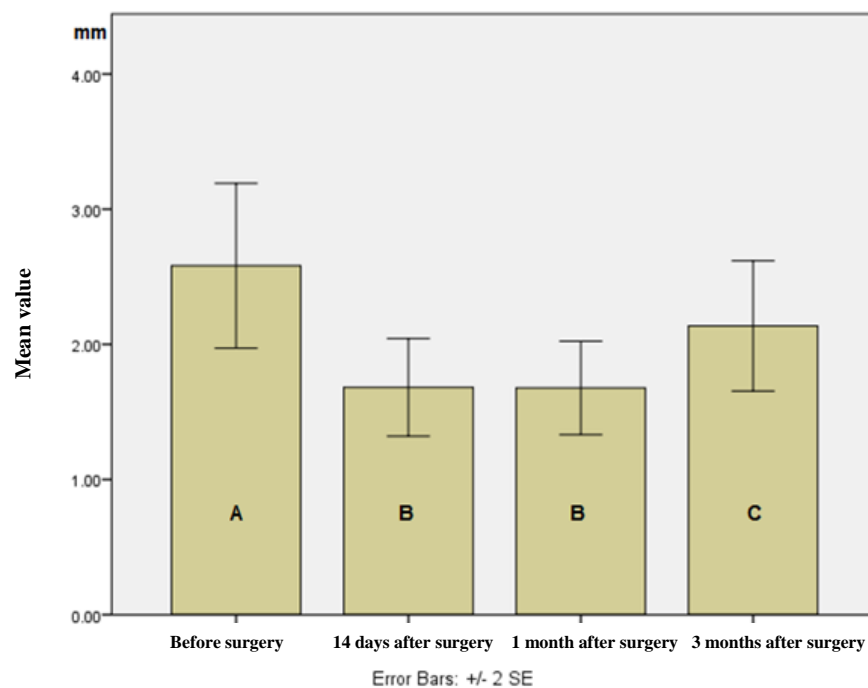
Follow-up times Variable	Before surgery Mean±SD	14 days after surgery Mean±SD	1 month after surgery Mean±SD	3 months after surgery Mean±SD	p-value*
Vermilion view (mm)	6.50±2.12	7.08±2.13	7.30±2.24	7.44±2.30	<0.001

*Using Repeated Measurements test

Table 2. Comparison of incisor view between follow-up times

Follow-up times Variable	Before surgery Mean±SD	14 days after surgery Mean±SD	1 month after surgery Mean±SD	3 months after surgery Mean±SD	p-value*
Incisor view (mm)	2.58±1.43	1.68±0.85	1.68±0.81	2.14±1.13	<0.001

*Using Repeated Measurements test

**Figure 1. Comparison of incisor view between follow-up times.** *Different letters in the chart indicate statistically significant differences between follow-up times.

Discussion

The results of our study showed that the length of the upper lip and the degree of vermillion view increased after depressor septi nasi muscle resection. Of course, the increase in the length of the upper lip was observed to be the highest until the fourteenth day after surgery, but from the fourteenth day until 3 months after surgery, the length of the upper lip decreased. However, it was still greater than before surgery. The evaluation of the effect of depressor septi nasi muscle resection on the upper lip and smile is limited to a few studies, and the present study is one of the first studies conducted in Iran in this area.

The results of the present study showed that the degree of anterior tooth view at rest and gingival view during smiling decreased after surgery. According to studies conducted on the function of the depressor septi nasi muscle, the activity of this muscle is associated with pulling the tip of the nose down, increasing the degree of gingival view in the upper jaw, and shortening the length of the upper lip (5, 6). By cutting this muscle, it is expected that the length of the lip will increase and the gingival view will decrease.

Most studies on changes in nasal parameters that affect the smile have shown similar findings. Similar to the present study, Pi et al. found that the release of depressor septi nasi muscle can increase the length of the upper lip and reduce the degree of maxillary anterior teeth view (7). Cerrati et al. also stated that the position of the upper lip and the vermilion view are effective indicators of facial and smile aesthetics that are affected by rhinoplasty (8).

In a study by Tosan et al., it was found that depressor septi nasi muscle resection leads to a raised vermilion and an increase in the length of the upper lip (2), which is consistent with the findings of our study. The ideal position of the upper lip is about 1 to 2 mm from the gum line in a deep smile, which is slightly less than the stated distance in men. Excessive resection causes a gummy smile, while the so-called long lip is due to insufficient resection of the depressor septi nasi muscle (9). On the other hand, some studies have shown findings different from our study. In a study by Sinno et al., it was reported that resection or transposition of the muscle improves the aesthetic results in rhinoplasty, such as raising the nasal tip, increasing the smile line, and overall facial beauty (10). Ahmad et al. also stated that the length of the upper lip is reduced in both resection or transposition techniques (11).

Kalantar-Hormozi et al. reported that the height of the upper lip is reduced following resection or transposition of the depressor septi nasi muscle (12). Ho et al. concluded that resection of the depressor septi nasi muscle has an unpredictable but small effect on the length of the upper lip at rest. In some cases, it causes a decrease and in others, it causes an increase in the length of the upper lip (13). The reason for the differences in the results of the studies could be clinical variables such as surgical technique or anatomical deviations.

The results of the present study show that depressor septi nasi muscle resection increases the length of the upper lip and vermilion view and reduces the display of the anterior teeth at rest and the gums in the smile position. According to the obtained results, it is recommended that a smile analysis be performed for each individual before rhinoplasty to determine the appropriate approach to dealing with the depressor septi nasi muscle.

Acknowledgment

We would like to express our gratitude to the Vice Chancellor for Research of Babol School of Dentistry and the Vice Chancellor for Research and Technology of Babol University of Medical Sciences, who helped us in conducting and improving the quality of this research.

References

1. Kolte AP, Kolte RA, Samarth GK. Association of the nasolabial angle and lip length with the gingival and interdental smile line-A gender based evaluation. *J Esthet Restor Dent*. 2021;33(3):503-9.
2. Tosan F, Esmaeelinejad M, Ghorbani R. Effects of open rhinoplasty on upper lip position in profile and frontal views. *Br J Oral Maxillofac Surg*. 2021;59(2):174-8.
3. Sabri R. The eight components of a balanced smile. *J Clin Orthod*. 2005;39(3):155-67.
4. Arli C, Bilgic F, Kaya A, Arpag OF. Effects of Rhinoplasty on Smile Esthetic and Gingival Appearance. *J Craniofac Surg*. 2020;31(3):689-91.
5. Rohrich RJ, Huynh B, Muzaffar AR, Adams Jr WP, Robinson Jr JB. Importance of the depressor septi nasi muscle in rhinoplasty: anatomic study and clinical application. *Plast Reconstr Surg*. 2000;105(1):376-83.
6. Beiraghi-Toosi A, Rezaei E, Jabbari Nooghabi M, Izadpanah S. Effect of depressor septi nasi muscle activity on nasal lengthening with time. *Aesthetic Plast Surg*. 2013;37(5):984-8.
7. Pi H, Kurlander DE, Guyuron B. Effects of the Rhinoplasty Maneuvers on Upper Lip Position and Incisor Show. *Aesthetic Plast Surg*. 2017;41(1):135-9.
8. Cerrati EW, Dayan SH. Association of Increasing Nasal Tip Projection With Lip Position in Primary Rhinoplasty. *JAMA Facial Plast Surg*. 2017;19(4):323-6.
9. Brito ÍM, Avashia Y, Rohrich RJ. Evidence-based Nasal Analysis for Rhinoplasty: The 10-7-5 Method. *Plast Reconstr Surg Glob Open*. 2020;8(2):e2632.
10. Sinno S, Chang JB, Chaudhry A, Saadeh PB, Lee MR. The role of depressor septi nasi manipulation in rhinoplasty: a systematic review. *Plast Reconstr Surg*. 2014;134(4S-1):134-5.
11. Ahmad J, Rohrich RJ. Discussion: smile analysis in rhinoplasty: a randomized study for comparing resection and transposition of the depressor septi nasi muscle. *Plast Reconstr Surg*. 2014;133(2):269-71.
12. Kalantar-Hormozi A, Beiraghi-Toosi A. Smile analysis in rhinoplasty: a randomized study for comparing resection and transposition of the depressor septi nasi muscle. *Plast Reconstr Surg*. 2014;133(2):261-8.
13. Ho Y, Deeb R, Westreich R, Lawson W. Effect of depressor septi resection in rhinoplasty on upper lip length. *JAMA Facial Plast Surg*. 2014;16(4):272-6.