



Urgent Coronary Artery Bypass Graft Surgery in a Patient with Post-Cardiac Injury Syndrome: A Very Rare Case Report

B. Askari (MD)^{*1} , K. Askari ² 

1. Department of Cardiovascular Surgery, School of Medicine, Urmia University of Medical Sciences, Urmia, I.R.Iran.

2. School of Medicine, Lokman Hekim University, Ankara, Turkey.

Article Type	ABSTRACT
Case Report	<p>Background and Objective: Coronary artery bypass surgery in a patient with post-cardiac injury syndrome (PCIS or severe pericarditis following myocardial infarction) is very rare and extremely difficult. The risk of incomplete and unsuccessful revascularization and cardiac damage is high. Incomplete surgery can lead to increased mortality and postoperative complications. A case of emergency coronary artery bypass surgery in a patient with post-cardiac injury syndrome is reported.</p> <p>Case Report: A 64-years-old man was admitted to Seyed-al-Shohada Heart Center of Urmia with chest pain and exertional dyspnea from two weeks before. His comorbidities included diabetes mellitus (type II), hypertension, smoking and obesity. The electrocardiogram showed atrial fibrillation with rapid ventricular response. Echocardiographic study demonstrated 50% ejection fraction and mild to moderate pericardial effusion. In laboratory tests, low hemoglobin and high serum creatinine were seen. Coronary angiography showed 50% distal stenosis of left main coronary artery as well as involvement of three heart vessels. During urgent coronary artery bypass surgery, we found severe and diffuse inflammation of cardiac surface and thickening of the pericardium. In the probable coronary artery route, limited release of visceral pericardial adhesions was performed. Coronary artery bypass graft surgery was performed. Weaning from cardiopulmonary bypass (CPB) was done with normal sinus rhythm and low dose inotrope. The only postoperative complication of the patient was exacerbation of preoperative renal failure. So, hemodialysis was performed once on the second postoperative day. The patient was discharged from the hospital on the 8th postoperative day. Follow up examination on the 12th months following operation revealed no clinical problems and echocardiographic study showed no pericardial effusion.</p> <p>Conclusion: Based on the results of our report, limited and carefully release of inflammatory epicardial adhesions should be done to find the target coronary arteries and to avoid heart failure.</p> <p>Keywords: <i>First Case, Myocardial Infarction, Left Main Coronary Artery, Pericardial Adhesions.</i></p>

Received:

Nov 6th 2022

Revised:

Jan 21st 2023

Accepted:

Mar 15th 2023

Cite this article: Askari B, Askari K. Urgent Coronary Artery Bypass Graft Surgery in a Patient with Post-Cardiac Injury Syndrome: A Very Rare Case Report. *Journal of Babol University of Medical Sciences*. 2023; 25(1): 281-7.



© The Author(S).

Publisher: Babol University of Medical Sciences

***Corresponding Author: B. Askari (MD)**

Address: Department of Cardiovascular Surgery, Seyed-al-Shohada Heart Center, 17 Shahrivar Blvd, Urmia, I.R.Iran.

Tel: +98 (44) 32375907. **E-mail:** askaribehnam@ymail.com

Introduction

Following a myocardial infarction (MI), patients are at risk for a variety of cardiac complications, including pericardial complications (1, 2). Even in some cases, the incidence of stroke after coronary artery bypass surgery has been reported (3). Post-cardiac injury syndrome has an estimated incidence of less than 5% in patients as peri-infarction pericarditis (PIP) and in less than 1% of patients as late post-myocardial infarction pericarditis. The symptoms of late pericarditis or Dressler's Syndrome tend to occur 2-3 weeks after MI (4). Other causes of Dressler's Syndrome include post-pericardiotomy syndrome (after cardiac surgeries) and post-traumatic pericarditis. In contrast to late type, early post-MI pericarditis occurs during the first 1 to 3 days and no more than a week after myocardial infarction. It develops in 1.2% of all patients and due to transmural necrosis with inflammation affecting the adjacent visceral and parietal pericardium. It is a benign process that does not independently affect in-hospital mortality (5).

Coronary artery bypass grafting (CABG) is the most routine daily surgical procedure in the most heart centers (6). However, severe pericardial inflammation and adhesion can make the CABG surgery difficult and useless. Finding the target coronary arteries in the presence of thick and inflamed epicardia is extremely difficult. Incomplete surgery can lead to unsuccessful weaning from cardiopulmonary bypass and the patient's death in the operating room or myocardial infarction, heart failure in the postoperative period and reducing the chance of patient survival.

In the review of scientific literature, the only similar report was presented by Doble et al. (7) in 1986. Considering the rarity of simultaneous pericarditis after heart attack and coronary artery bypass surgery, possible risks and challenges of surgery, and in order to present our experiences to other heart surgeons and cardiologists, this case of emergency coronary artery bypass surgery in a patient with Dressler's syndrome and left main coronary artery disease with extensive pericardial inflammatory adhesions is reported.

Case Report

This case report was approved by the Ethics Committee of Urmia University of Medical Sciences with code IR.UMSU.REC.1401.372. A 64-year-old male patient presented with chest pain and shortness of breath and was diagnosed with Anterior ST Elevation Myocardial Infarction (anterior STEMI). His comorbidities included type 2 diabetes, high blood pressure, smoking, obesity (body mass index of 35) and a history of cataract surgery and lumbar disc surgery.

The electrocardiogram showed atrial fibrillation with rapid ventricular response. On the chest x-ray, the lung fields were clear and there were appearances suggestive of pericardial effusion (Figure 1). Blood analysis findings were as follows: hemoglobin 10.2 g/dL, white blood cell count of 9900/dl with neutrophil count of 74.4%, creatinine 1.76mg/dL and non-elevated erythrocyte sedimentation rate (ESR).

Echocardiographic study demonstrated 50% ejection fraction, mild to moderate mitral regurgitation and mild to moderate pericardial effusion. Coronary angiography showed 50% distal stenosis of left main coronary artery, multiple significant proximal stenosis of the left anterior descending (LAD) artery and patent circumflex artery. The right coronary artery (RCA) was a small vessel and 60% proximal stenosis.

Patient was candidate for urgent coronary artery bypass surgery (CABG) and after rate control of atrial fibrillation and nephrology consultation was transferred to operation room. Median sternotomy was performed. A very important intraoperative finding was severe and diffuse inflammation of cardiac surface and thickening of the pericardium. In the pericardial cavity, acute inflammatory process and relatively dense fibrous adhesions were seen. The severity of these inflammations and adhesions was such that it seemed impossible to locate the target coronary arteries (Figure 2).

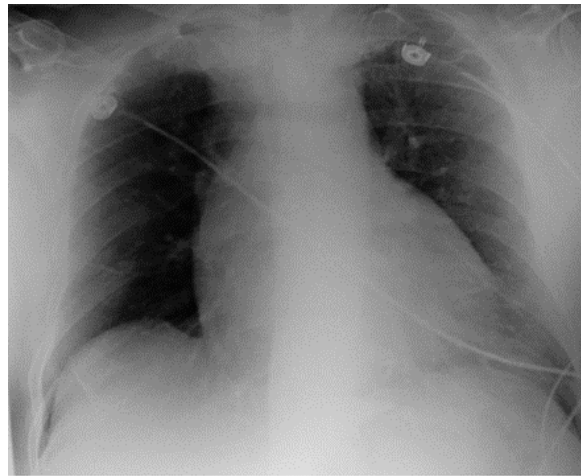


Figure 1. Chest X-ray (PA view) shows increased cardiothoracic ratio

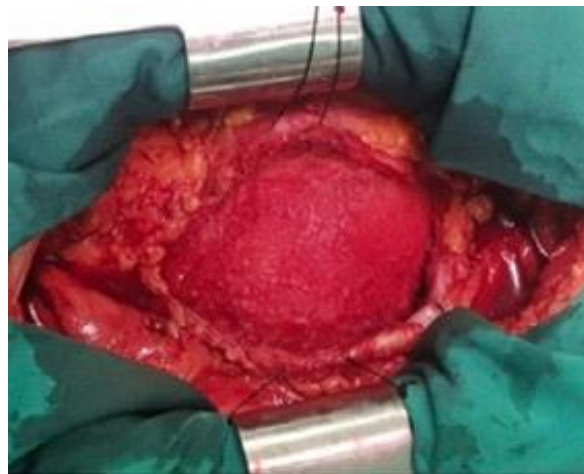

Figure 2. Intraoperative cardiac view shows severe and diffuse epicardial and pericardial inflammation

Adhesions were relatively severe at the parietal pericardial surface and very severe at the visceral pericardial surface. The adhesion was more severe at the inferior surface of the heart. After adhesion releasing and heparinization, the aorta and right atrium were cannulated. The release of adhesions and removal of fibrinous materials continued during cardiopulmonary bypass (Figure 3). Patient blood was cooled to 30 °C and cardiac arrest was achieved with retrograde and antegrade cardioplegia.

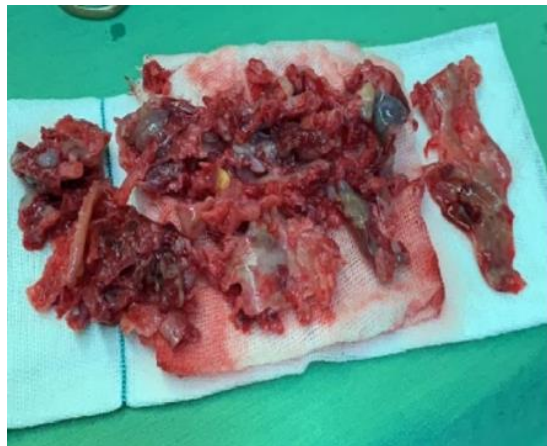

Figure 3. Removing a lot of fibrinous materials

In the probable coronary artery route, limited release of visceral pericardial adhesions was performed (Figure 4). A small perforation was made in the inferior part of the right atrium which was repaired with a plegetted suture. Saphenous vein was grafted to obtuse marginal (OM) and left internal mammary artery (LIMA) was grafted to the LAD. Due to the severe adhesion in the RCA territory and its small size and adjacent right atrium perforation, we did not find RCA and so was left non-revascularized. The total cardiopulmonary bypass pump (CPB) time and cross clamp time was 150 and 80 minutes, respectively. CPB weaning was done with NSR (normal sinus rhythm) and low dose inotrope.

During Intensive care unit (ICU) admission, the patient did not show any respiratory, neurological, cardiac, arrhythmia and other postoperative complications. The only complication of the patient was exacerbation of preoperative renal failure, and hemodialysis performed once on the second postoperative day with a serum creatinine level of 3.9 mg/dL. From the third postoperative day, urine was restored and creatinine decreased gradually. Due to mediastinal drainage and control echocardiography, the mediastinal drain was removed 5 days after the operation.

The patient was discharged from the hospital on the 8th postoperative day with NSR and creatinine level of 1.65 mg/dL. Follow up examination on the 12th months following operation revealed no clinical problems and echocardiographic study showed no pericardial effusion. Histology of the pericardium showed acute fibrinous pericarditis with granulation tissue and fibrin deposition.

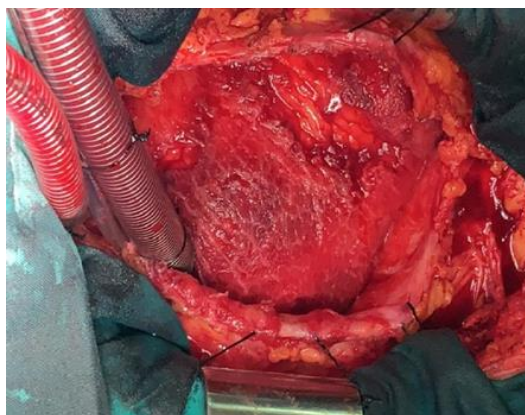


Figure 4. Limited release of visceral pericardial adhesions for LAD finding

Discussion

Post-cardiac injury syndrome or Dressler's syndrome can make the CABG surgery difficult and useless because of the high probability of incomplete and unsuccessful revascularization and cardiac (cavities and coronary artery) damage. In this case report, we present the second successful case of coronary artery bypass graft surgery in the presence of Dressler's syndrome. In all previous reports and similar articles, Dressler syndrome was presented in post-cardiac surgery patients, post-cardiac trauma patients or post- MI in non-surgical patients.

Post-cardiac injury syndrome was first described after myocardial infarction by Dressler in 1956 (8). In a cohort study in Finland in patients undergoing cardiothoracic surgery, post-cardiac injury syndrome developed in 1.7 percent of all patients (9).

Dressler's syndrome is believed to have an autoimmune etiology. In contrast to early post-MI pericarditis, inflammation is diffuse and not localized to the myocardial injury site. Dressler's syndrome usually occurs 3 to 4 weeks after infarction (2). In our study, the patient had no symptoms of fever, friction rub (FR), high ESR, and ECG changes. One study showed the incidence of symptoms as follows: chest pain (56%), fever (54%), FR (32%), and ECG changes (24%) (10). The reason for the absence of fever and high ESR in our patient may be due to the relatively low interval between myocardial infarction and the patient's surgery.

As in other studies, only pericardial effusion was reported in echocardiography and no mention of pericarditis was reported (1, 10). Therefore, the possibility of pericarditis should be considered in patients with myocardial infarction and pericardial effusion who are candidates for surgery. Imazio et al. (10) has shown that patients after cardiac surgery had significantly pericardial effusion in cases of Dressler's syndrome compared to those without it (89% vs. 5%).

We did not find any similar case in our search. In the only relatively similar case, Doble et al. in 1986 reported a 43-year-old man with previous myocardial infarction who was hospitalized with a third and extensive antero-lateral myocardial infarction. The patient underwent 3 grafts coronary artery bypass surgery and pericardiectomy (7). In a recent study by Imazio et al., pericardiectomy is generally considered a therapeutic option of doubtful efficacy in recurrent idiopathic pericarditis and should be considered only in exceptional cases (11).

In similar studies where the patient had evidence of Dressler's syndrome after myocardial infarction, no surgery was performed and only diagnostic studies and medical or PCI treatments were performed (2, 12). In previous studies related to surgical treatment, the first case of Dressler's syndrome following TAVI (Transcatheter aortic valve implantation) and minimally invasive surgery was reported (13, 14). In other words, other studies have addressed the challenge of diagnosing, excluding differential diagnoses and medical treatment of Dressler's syndrome, but our report has shown a challenge during surgery caused by Dressler's syndrome itself.

We should consider the diagnosis of Dressler's syndrome as an intraoperative challenge during emergency coronary artery bypass in patients with ST elevation MI and pericardial effusion. Limited and carefully release of inflammatory epicardial adhesions should be done to find the target coronary arteries and to avoid heart damage.

Acknowledgment

The staff of heart surgery rooms, the intensive care unit and heart surgery department of Seyed-al-Shohada Heart Center of Urmia are hereby thanked.

References

1. Widimský P, Gregor P. Pericardial involvement during the course of myocardial infarction. A long-term clinical and echocardiographic study. *Chest*. 1995;108(1):89-93.
2. Gao Y, Bishopric NH, Chen HW, Li JT, Huang YL, Huang HX. Post-cardiac injury syndrome in acute myocardial infarction patients undergoing PCI: a case report and literature review. *BMC Cardiovasc Disord*. 2018;18(1):234.
3. Mir Mohammad Sadeghi SM, Hadipour M, Molavi Vardanjani H. Incidence of Postoperative Stroke after Coronary Artery Bypass Surgery and its Risk Factors. *J Babol Univ Med Sci*. 2011;13(3):74-9. [In Persian]
4. Imazio M, Hoit BD. Post-cardiac injury syndromes. An emerging cause of pericardial diseases. *Int J Cardiol*. 2013;168(2):648-52.
5. Lador A, Hasdai D, Mager A, Porter A, Goldenberg I, Shlomo N, et al. Incidence and Prognosis of Pericarditis After ST-Elevation Myocardial Infarction (from the Acute Coronary Syndrome Israeli Survey 2000 to 2013 Registry Database). *Am J Cardiol*. 2018;121(6):690-4.
6. Askari B, Babakan R, Nurinejad F, Mahoori A. Prevalence of coronary artery disease risk factors in patients undergoing coronary artery bypass surgery in West Azerbaijan province. *J Shahrekord Univ Med Sci*. 2019;21(4):181-6.
7. Doble N, Westaby S, Goodwin JF. Urgent coronary artery bypass surgery in the presence of Dressler's syndrome. *Clin Cardiol*. 1986;9(3):125-7.
8. Dressler W. A post-myocardial infarction syndrome; preliminary report of a complication resembling idiopathic, recurrent, benign pericarditis. *J Am Med Assoc*. 1956;160(16):1379-83.
9. Lehto J, Kiviniemi T, Gunn J, Airaksinen J, Rautava P, Kytö V. Occurrence of Postpericardiotomy Syndrome: Association With Operation Type and Postoperative Mortality After Open-Heart Operations. *J Am Heart Assoc*. 2018;7(22):e010269.
10. Imazio M, Brucato A, Rovere ME, Gandino A, Cemin R, Ferrua S, et al. Contemporary features, risk factors, and prognosis of the post-pericardiotomy syndrome. *Am J Cardiol*. 2011;108(8):1183-7.
11. Imazio M, Spodick DH, Brucato A, Trinchero R, Adler Y. Controversial issues in the management of pericardial diseases. *Circulation*. 2010;121(7):916-28.
12. Macedo TA, Dantas Junior RN, De Barrose Silva PG, Sampaio MC. Dressler Syndrome: A Case Report. *Iran Red Crescent Med J*. 2015;18(11):e28697.
13. Llubani R, Bohm M, Imazio M, Fries P, Khreish F, Kindermann I. The first post-cardiac injury syndrome reported following transcatheter aortic valve implantation: a case report. *Eur Heart J Case Rep*. 2018;2(4):yty107.
14. Fletcher C, Ostergaard C, Menzies R. Dressler syndrome after minimally invasive coronary artery bypass surgery. *J Am Board Fam Pract*. 2004;17(3):230-2.