

Comparative Evaluation of the Mast Cells between Oral and Cutaneous Squamous Cell Carcinoma

E. Mohammadnia Sarvi (DDS)¹, S. Siadati (PhD)², A. Mohammadpour (PhD)³, H. Abbaszadeh(PhD)^{4*}

1.Student Research Committee, Faculty of Dentistry, Babol University of Medical Sciences, Babol, I.R.Iran

2.Department of Pathology, Faculty of Medicine, Babol University of Medical Sciences, Babol, I.R.Iran

3.Pharmaceutical Research Center, Faculty of Pharmacy, Mazandaran University of Medical Sciences, Sari, I.R.Iran

4.Cellular and Molecular Biology Research Center, Health Research Institute, Babol University of Medical Sciences, Babol, I.R.Iran

J Babol Univ Med Sci; 19(4); Apr 2017; PP: 36-40

Received: Dec 19th 2016, Revised: Jan 25th 2017, Accepted: Feb 22th 2017.

ABSTRACT

BACKGROUND AND OBJECTIVE: It has been mentioned that mast cells may help to tumor invasion. According to different aggressive behavior of oral squamous cell carcinoma (OSCC) compared to cutaneous SCC (CSCC), the aim of this study was to compare mast cells count between OSCC and CSCC to understand the role of them in different biologic behavior of these two tumors.

METHODS: This cross-sectional study consisted of 90 samples including 30 cases of OSCC, 30 cases of CSCC, 15 cases of normal skin and 15 cases of normal oral mucosa (as control groups). Number of mast cells was counted under light microscope in 10 successive fields in invasive front of OSCCs and CSCCs at 400X magnification and mean mast cells count/mm² were calculated and compared between studied groups using one way ANOVA statistical test.

FINDINGS: Mean mast cells count in CSCC, OSCC, normal skin and normal oral mucosa groups were 20.31±14.67, 10.41±8.01, 5.10±8.67 and 4.87±2.68, respectively. There were significant differences in mast cell count between CSCC and normal skin groups (p<0.001) and between CSCC and OSCC groups (p=0.002). This difference wasn't significant between OSCC and normal oral mucosa groups (p=0.337).

CONCLUSION: Lower level of mast cells in OSCCs may reflect less need for activation of mast cells in order to increase angiogenesis in OSCCs. Increase in mast cell density in CSCCs suggests a possible role for mast cell in tumor progression of CSCCs.

KEY WORDS: *Oral Squamous Cell Carcinoma, Cutaneous Squamous Cell Carcinoma, Mast cell.*

Please cite this article as follows:

Mohammadnia Sarvi E, Siadati S, Mohammadpour A, Abbaszadeh H. Comparative Evaluation of the Mast Cells between Oral and Cutaneous Squamous Cell Carcinoma. J Babol Univ Med Sci. 2017;19(4):36-40.

*Corresponding author: H. Abbaszadeh (PhD)

Address: Department of Oral and Maxillofacial Pathology, Faculty of Dentistry, Babol University of Medical Sciences, Iran.

Tel: +98 11 32291408

E-mail: hamidabbasade@yahoo.com

Introduction

Oral squamous cell carcinoma (OSCC) and cutaneous squamous cell carcinoma (CSCC) are two epithelial malignancies; OSCC is the most common oral malignancy, and CSCC is the second most common skin cancer (1,2). In solid tumors, such as squamous cell carcinoma, a combination of the effects of cancer cells and stromal cells (i.e., fibroblasts, endothelial cells and inflammatory cells) have been implicated in coordinating tumor progression, angiogenesis, local invasion and metastasis (3). Mast cells are one of the immune defense cells that are involved in allergic, inflammatory and immune responses (4).

It has been proven that the activation of mast cells results in many biological outcomes, including mitogenesis, extracellular matrix decompression, angiogenesis, increased permeability in small vessels, and the invasion of inflammatory cells including macrophages. It is known that angiogenesis is required to invade and spread tumors (4). It has been reported that mast cells may play a role in tumor invasion and metastasis by increasing angiogenesis (5).

On the other hand, the invasive and biological behavior of OSCC and CSCC is different, and these different invasive and biological behaviors may be related to some of the factors, including the activity of mast cells (6-9). Regarding the role of mast cells in invasion and metastasis and their effect on invasive and biological behavior of tumors, the study of these inflammatory cells seems necessary in order to assess their effect on the invasive and biological behavior of OSCC and CSCC.

In previous studies, there is a contradiction in the number of mast cells between OSCC and normal oral mucosa, so that a number of studies reported relative reduction of number of mast cells in OSCC than normal oral mucosa (4, 10). While other studies show a significant increase in the number of mast cells in OSCC compared to normal mucus (11-18).

The only study in the study of mast cells in CSCC supports the role of these cells in the progression and invasion of the CSCC (19). Also, in the context of the difference in the number of mast cells between OSCC and CSCC, only one study was conducted where the mean density of mast cells in CSCCs was significantly higher than that of OSCCs (5). Therefore, considering the contradictions in previous studies and the existing studies on comparing the number of mast cells between OSCC and CSCC, the purpose of this study

was to evaluate the difference in the number of mast cells between OSCC and CSCC with normal tissues (control groups) and also between the squamous cell carcinoma of the mouth and the skin in order to detect the mast cell proliferation in the invasive OSCC and CSCC, as well as the invasive and biological behavior of these two tumors.

Methods

This cross-sectional study was conducted after obtaining permission from the Ethics Committee of Babol University of Medical Sciences with the code 1395.88 Mubabol.REC on 30 cases of squamous cell carcinoma (Well-differentiated) and 30 cases of squamous cell carcinoma (Well-differentiated type, which was recovered from the paraffin blocks found in the pathology department of the Babol Dental School and the Shahid Beheshti Hospital, Babol, Iran. 15 cases of normal oral mucosa (gingival tissue resulting from surgery of increasing the crown length that does not have inflammation or have minimal inflammation) and 15 non-tumor skin samples (such as skin pigmentation and hypertrophic scars) as control group were used. Sample size was selected based on similar studies (4,5,10-19).

4 micron sections were prepared from blocks and stained by histochemistry method with toluidine blue staining in a pathology lab. Toluidine blue staining was done with Toluidine blue 1% solution (Merck, Darmstadt, Germany), diluted in phosphate buffer (PH: 4-6) in 45 seconds. After observing the same initial steps for coloring the hematoxylin and eosin, the sections prepared in Toluidine Blue Blot were immersed for 2-3 minutes and washed in three dishes of distilled water. Subsequently, by using 90% alcohol and two alcoholic beverages 100% were depleted (10 drops per dish, as the excess color quickly disappears in alcohol). The sections were then cleaned in doses of xylene each time for 3 minutes and fitted with the DPX mounting material (10).

Mast cell cytoplasm contains metachromatic granules composed of heparin and histamine. Sulphate proteoglycans in the secretory granules of mast cells have a metachromatic characteristic that is colored by Toluidine blue. Toluidine blue is staining mast cells as red-purple (metachromatic staining) and the field is blue (orthochromatic staining), therefore mast cells can be detected (11). Two pathologists performed the mast cell count, and the number of ultimate mast cells was

obtained for each sample from the mean of the two reported ones. The count of mast cells was performed with an optical microscope Olympus CX21 (Olympus corporation, Tokyo, Japan) at a magnification of 400×. To count the number of mast cells, for each sample at low magnification, hot spots (regions with the highest number of mast cells) were detected and in 10 hot-spot areas at a magnification of 400× (corresponding to an area of about 1mm²), the number of mast cells was counted. For the counting of mast cells, granular and degranular types of mast cells were considered (12). Data were analyzed using SPSS software using One Way ANOVA, Kruskal-Wallis and Mann-Whitney tests and $p < 0.05$ was considered significant.

Results

In this study, the number of mast cells was counted on the invasive front of OSCC and CSCC (Fig 1, 2). The average number of mast cells in HMM-1 in the groups of CSCC, OSCC, normal skin and normal oral mucosa were 20.31 ± 14.67 , 10.41 ± 8.01 , 10.5 ± 8.67 , 4.87 ± 2 , respectively. The highest number of mast cells was observed in the CSCC group and the lowest number of mast cells in the normal oral mucosal group. There was a significant difference between normal skin and CSCC in terms of the average number of mast cells per square meter ($p < 0.001$). OSCC showed more mast cells than normal oral mucosal group, but their difference was not significant. CSCCs had significantly more mast cells than OSCCs ($p = 0.005$).

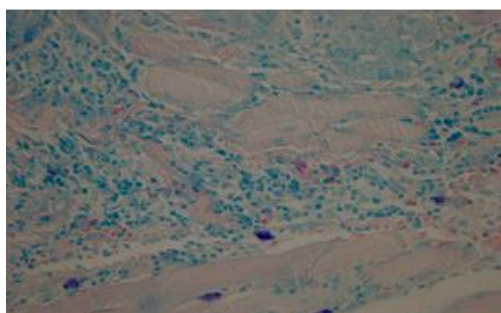


Figure 1. Mast cells on the invasive front of the OSCC

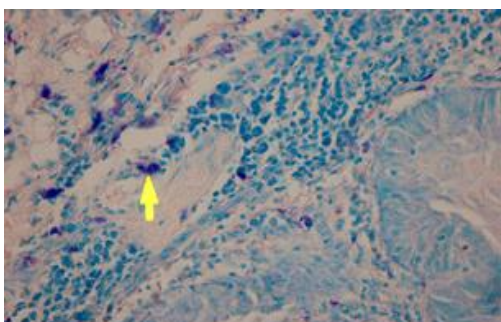


Figure 2. Mast cells on the invasive front of the CSCC

Discussion

The results showed that in CSCCs, the mean number of mast cells was significantly higher than OSCCs. In our study, OSCCs showed a higher number of mast cells than normal oral mucosal group but their difference was not meaningful. This finding shows an increase in the migration of these cells to the OSCC stroma, which is negligible.

It can also be argued that this finding suggests that although mast cells may play a role in the progression of the tumor, OSCCs may possibly be triggered by angiogenesis, but this role is negligible. In many studies, the number of mast cells in OSCC was significantly higher than normal oral mucosa (11-18). The higher levels of mast cells in OSCCs in their studies are in agreement with our result, but this difference with normal oral mucosa was not significant in our study, which could be due to the small number of samples in this study. Some of these studies showed a positive correlation between microvessel density (MVD) and mast cell density (MCD), so that the increase in vascular density was associated with increased mast cell density (13,14,18).

Therefore, they concluded that mast cells contributed to the progression of OSCC through increased angiogenesis. The remaining studies showed no correlation between MVD and MCD (16, 15, 12, 11). Therefore, they conclude that mast cells are involved in the progression of OSCC through increased angiogenesis. In other studies, the mean number of mast cells in OSCC was lower than normal oral mucosa (4,10).

In our study, the number of mast cells in OSCC was higher than normal oral mucosa, which contrasted with their outcome, although the increase in mast cell numbers in OSCCs was not significant in our study. The results of their studies support the hypothesis that mast cells do not play a role in the progression of the OSCC tumor. This conclusion agrees with our conclusion. In the above studies, the reduction in the number of mast cells in OSCC was attributed to defective migration of these cells in comparison with normal oral mucosa.

In our study, there was a significant difference between normal skin and CSCC in terms of the number of mast cells. This finding suggests that mast cells play an important role in tumor progression and invasion of CSCCs, possibly by stimulating angiogenesis. Ch'ng and his colleagues studied skin cancers, including CSCC, and concluded that mast cell may play an important role in the progression of these

tumors due to the rich source of vascular endothelial growth factor (19). This result is in accordance with our study because our higher levels of CSCc in our study support their role in the development of CSCC. In our study, the number of mast cells was significantly higher in CSCCs than OSCCs. This finding shows that mast cell plays an important role in the biological behavior of these two tumors.

Lower levels of mast cells in OSCCs may reflect less need for activating mast cells to enhance angiogenesis in OSCCs. The higher levels of mast cells in CSCCs also reflect the need for more activation of mast cells in CSCCs. If we accept the hypothesis of the association of mast cells with angiogenesis in CSCCs, the need for activating mast cells in CSCCs as compared to OSCC may be attributed to their role in increasing the angiogenesis in CSCCs. In the study of Pariziri et al., in CSCCs, the mean density of mast cells was significantly higher than OSCCs, which is consistent with our results (5). In the study, lower mast cell levels in OSCC were associated with less need for activation of these cells in

oral cancer. In the study of Kalra et al., a significant reduction was observed in terms of the mean number of mast cells from well-differentiated OSCC to OSCC with poor differentiation (20). Considering that the number of mast cells in our study in CSCC stroma was significantly higher than OSCC, this significant difference in the number of mast cells could indicate the role of mast cells in different biological behavior of OSCC and CSCC. Considering the significant increase in the number of mast cells in the CSCC relative to normal skin and in the OSCC relative to normal oral mucosa, the findings support the potential role of mast cells in the progression of CSCCs.

Acknowledgments

Hereby, we would like to thank the Vice-Chancellor for Research and Technology of Babol University of Medical Sciences for supporting this research, as well as Mr. Mohammadi and Aghajani and all dear ones who helped us in accomplishing this study.

References

1. Lambert R, Sauvet C, de Camargo Cancela M, Sankaranarayanan R. Epidemiology of cancer from the oral cavity and oropharynx. *Eur J Gastroenterol Hepatol*. 2011;23(8):633-41.
2. Kane CL, Keehn CA, Smithberger E, Glass LF. Histopathology of cutaneous squamous cell carcinoma and its variants. *Semin cutan med surg*. 2003;23(1):54-61.
3. Rajabi-Moghaddam M, Abbaszadeh-Bidokhty H, Bijani A. Comparison of mast cells count in odontogenic cysts using histochemical staining. *Iran J Pathol*. 2015;10(2):105-10.
4. Dastpak M, Nafarzadeh S, Khafri S. A comparative study on the mast cells count in oral squamous cell carcinoma and normal oral mucosa. *Caspian J Dental Res*. 2015;4(1):17-22.
5. Parizi ACG, Barbosa RL, Parizi JLS, Nai GA. A comparison between the concentration of mast cells in squamous cell carcinomas of the skin and oral cavity. *Anais Brasileiros De Dermatologia*. 2010;85(6):811-8.
6. Hadler-Olsen E, Wetting HL, Rikardsen O, Steigen SE, Kanapathipillai P, Grénman R, et al. Stromal impact on tumor growth and lymphangiogenesis in human carcinoma xenografts. *Virchows Arch*. 2010;457(6):677-92.
7. Narendra H, Tankshali R. Prevalence and pattern of nodal metastasis in pT4 gingivobuccal cancers and its implications for treatment. *Indian J Cancer*. 2010;47(3):328.
8. Khalili J. Oral cancer: risk factors, prevention and diagnostic. *Exp Oncol*. 2008;30(4):259-64.
9. Sklenicka S, Gardiner S, Dierks EJ, Potter BE, Bell RB. Survival analysis and risk factors for recurrence in oral squamous cell carcinoma: does surgical salvage affect outcome?. *J Oral Maxillofac Surg*. 2010;68(6):1270-5.
10. Oliveira-Neto HH, Leite AF, Costa NL, Alencar RC, Lara VS, Silva TA, et al. Decrease in mast cells in oral squamous cell carcinoma: possible failure in the migration of these cells. *Oral oncol*. 2007;43(5):484-90.
11. Tahir A, Nagi AH, Ullah E, Janjua OS. The role of mast cells and angiogenesis in well-differentiated oral squamous cell carcinoma. *J Cancer Res Ther*. 2013;9(3):387.
12. Jaafari-Ashkavandi Z, Moshref M, Mashhadi-Abbas F, Sargolzaie S, Taghavi N. Evaluation of CD31 expression and mast cell count in dysplastic lesions and squamous cell carcinoma of the oral cavity. *Iran Red Crescent Med J*. 2010;2010(3):272-6.
13. Sharma M, Sah P, Sharma SS, Radhakrishnan R. Molecular changes in invasive front of oral cancer. *J Oral Maxillofac Pathol*. 2013;17(2):240-7.
14. Mohtasham N, Babakoochi S, Salehinejad J, Montaser-Kouhsari L, Shakeri MT, Shojaei S, et al. Mast cell density and angiogenesis in oral dysplastic epithelium and low-and high-grade oral squamous cell carcinoma. *Acta Odontologica Scandinavica*. 2010;68(5):300-4.
15. Jahanshahi G, Sabaghian M. Comparative immunohistochemical analysis of angiogenesis and mast cell density in oral normal mucosa and squamous cell carcinoma. *Dent Res J*. 2012;9(1):8-12.
16. Anuradha A, Kiran Kumar Naik B, Vijay Srinivas G, Devi RS, Puneet H. Incidence of mast cells in oral squamous cell carcinoma: A short study. *J Oncol*. 2014;2014(1):1.
17. Ramsridhar S, Narasimhan M. Immunohistochemical evaluation of mast cells in leukoplakia and oral Squamous cell carcinoma. *J Clin Diagn Res*. 2016;10(8): 100.
18. Ingaleswar PS, Pandit S, Desai D, Redder CP, Shetty AS, Mithun K. Immunohistochemical analysis of angiogenesis by CD34 and mast cells by toluidine blue in different grades of oral squamous cell carcinoma. *J Oral Maxillofac Pathol*. 2016;20(3):467.
19. Ch'ng S, Wallis RA, Yuan L, Davis PF, Tan ST. Mast cells and cutaneous malignancies. *Modern Pathol*. 2006;19(1):149-59.
20. Kalra M, Rao N, Nanda K, Rehman F, Girish K, Tippu S, et al. The role of mast cells on angiogenesis in oral squamous cell carcinoma. *Med Oral Patol Oral Cir Bucal*. 2012;17(2):e190-6.