

Comparison of Nd:YAG Laser Posterior Capsulotomy Techniques: Cruciate Versus Circular

R. Rezaei (MD)^{*1}, A. Almasi-Hashani (MSc)², M. Khorrambakht (MD)³, A. Khosravi (PhD)⁴

1.Department of Ophtalmology, Arak University of Medical Sciences, Arak, I.R.Iran

2.Reproductive Epidemiology Research Center, Biology and Medical Sciences Institute of Jahad Daneshgahi, Royan Institute, Tehran, I.R.Iran

3.Faculty of Medicine, Arak University of Medical Sciences, Arak, I.R.Iran

4.Center for Health-Related Social and Behavioral Sciences Research, Shahroud University of Medical Sciences, Shahroud, I.R.Iran

J Babol Univ Med Sci; 18(12); Dec 2016; PP: 7-12

Received: Jun 2nd 2016, Revised: Jul 27th 2016, Accepted: Sep 27th 2016.

ABSTRACT

BACKGROUND AND OBJECTIVE: Nd:YAG laser posterior capsulotomy is a standard method for treatment of posterior capsule opacification (PCO) in adults. However, there is not enough information available regarding the advantages and disadvantages of its conventional techniques. This study aims to compare cruciate and circular techniques of Nd: YAG laser posterior capsulotomy.

METHODS: In this clinical trial, 100 eyes of patients with posterior capsule opacification after cataract surgery were randomly divided into two groups. Cruciate capsulotomy was performed for the first group and circular capsulotomy was performed for the second group. Visual acuity, intraocular pressure, lens shifting, uveitis, macular hole and retinal detachment were examined. In addition, the energy used for rupturing the capsule was recorded. IRCT: 201207037466N4.

FINDINGS: The energy used in circular capsulotomy (345 ± 68.53) was significantly more than the energy used in cruciate capsulotomy (284.4 ± 46.78) ($p=0.001$). Results showed that there is no significant difference between the two groups in terms of average visibility ($p=0.859$) and intraocular pressure ($p=0.097$). Nevertheless, these two variables increase significantly through time ($p=0.001$). Moreover, there is no significant difference between the two groups in terms of percentage of halo.

CONCLUSION: Since improvement in visual acuity and intraocular pressure was similar in the two groups but the energy used in circular capsulotomy was more than cruciate capsulotomy, cruciate technique is the preferred method.

KEY WORDS: *Posterior capsulotomy, Cruciate technique, Circular technique, Visual acuity.*

Please cite this article as follows:

Rezaei R, Almasi-Hashani A, Khorrambakht M, Khosravi A. Comparison of Nd:YAG Laser Posterior Capsulotomy Techniques: Cruciate Versus Circular. J Babol Univ Med Sci. 2016;18(12):7-12.

*Corresponding author: R. Rezaei (MD)

Address: Department of Ophtalmology, Faculty of Medicine, Arak University of Medical Sciences, Arak, I.R.Iran

Tel: +98 86 33127297

E-mail: dr.rezarezaei@arakmu.ac.ir

Introduction

Improvements in cataract surgery techniques have made this method increasingly safe. Nevertheless, posterior capsular opacification is still the most common complication of cataract surgery and insertion of intraocular lenses (1) and this may occur in 17 to 51% of patients during a five-year period after cataract surgery (2).

Several studies have discussed the mechanism for development of posterior capsule opacification (3-6) and having knowledge about its pathogenesis can improve the techniques of cataract surgery and the design of lenses, leading to the reduction of posterior capsule opacification (7, 8).

Posterior capsule opacification can significantly weaken eyesight and cause disorders related to contrast, light scattering and monocular double vision (9). Nd:YAG laser posterior capsulotomy is a standard method for treatment of posterior capsule opacification (PCO) in adults. Based on this method, laser ruptures the capsule in the anterior vitreous by creating pressure waves (10) and provides the possibility to remove the created pathology without opening the eye and is one of the safest and most effective methods for treatment of posterior capsule opacification (9).

Although Nd:YAG laser posterior capsulotomy improves the visual function, it may be accompanied by several complications such as increased intraocular pressure, damage to the intraocular lens, lens dislocation, cystoid macular edema caused by uveitis, macular hole and retinal detachment (11-13). There are different laser techniques to treat patients with posterior capsule opacification and currently the two methods of Nd:YAG laser posterior capsulotomy including cruciate and circular are used. In cruciate method, laser treatment is done by creating a horizontal off-axis line passing the center and after that a vertical line in the form of a cross. However, in circular method, the laser is used according to a round pattern (14). Several studies have been dedicated to the complications of these two methods. However not previous study has compared these two methods. Therefore, this study aims to compare cruciate and circular techniques of Nd:YAG laser posterior capsulotomy.

Methods

This triple-blind clinical trial was carried out with registration number of IRCT: 201207037466N4. After

receiving permission from the university ethics committee (code: 176-8), obtaining written consent from patients and compliance with the Declaration of Helsinki, the study was conducted among patients referred to Imam Reza Eye Clinic in Arak who suffered from posterior capsule opacification after phacoemulsification cataract surgery. 50 patents were selected as sample size according to the mean best modified level of visual acuity in both groups of cruciate and circular posterior capsulotomy with 5% alpha error and 20% beta error. Patients were divided into two groups through balanced block randomization. Quadruple blocks were used four this purpose. The online application "Sealed Envelope" was used to divide the patients into two groups (15). Due to random allocation, distribution of potential confounding variables was the same for the two groups and their confounding role was controlled.

Patients with history of phacoemulsification cataract surgery with acrylic intraocular lens and over 10 years old were included the study. Patients with history of non-cataract surgeries, history of glaucoma, uveitis, retinal problems, cataracts caused by trauma, systemic diseases such as diabetes, lack of participation in follow-ups, non-acrylic intraocular lens and presence of any complication during or after surgery were excluded from the study.

First, all patients underwent complete eye examinations including Snellen visual acuity and intraocular pressure measurement using tonometry method (Goldman and Fundoscopy) and their posterior capsule opacification was determined using Sellman and Lindstrom categorization (Grade 1: lack of PCO or minor PCO without red reflex reduction and without a pearl view in the edge of the IOL; Grade 2: mild PCO with red reflex reduction and with Elschnig pearl view in the edge of the IOL; Grade 3: relative fibrosis with Elschnig pearl view in the edge of the IOL without involvement of visual axis and Grade 4: severe fibrosis or Elschnig pearl view with involvement of visual axis and severe red reflex reduction) (16).

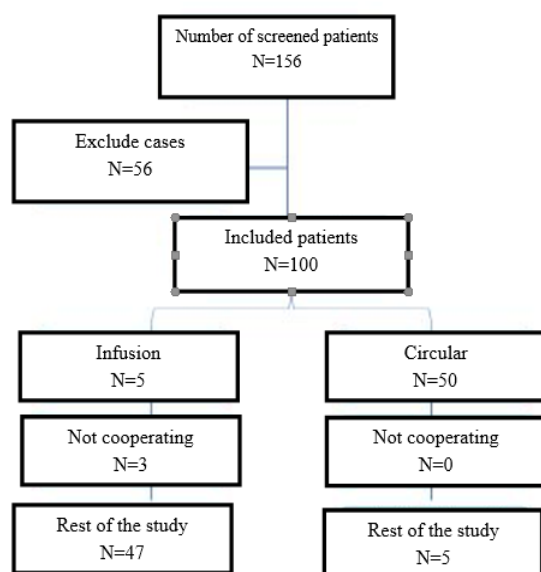
Then, patients were divided into two groups through balanced block randomization. For the first group, cruciate Nd:YAG laser posterior capsulotomy was performed and for the second group circular Nd:YAG laser posterior capsulotomy was performed. In Posterior capsulotomy, energy starts from 0.8 mj and increases until the posterior capsule is ruptured 3-4 cm and then the visual acuity, intraocular pressure, lens dislocation, uveitis, macular hole and retinal

detachment were evaluated one day, one week and one month later. Moreover, the energy used for capsular rupture was recorded. All operations were performed by one eye surgeon and the data were collected and recorded by a person unaware of categorizations.

Statistical methods: Data analysis was done using Shapiro-Wilk test to assess normality, Chi-Square test, T-Test, generalized estimating equation (GEE) and Repeated measure ANOVA. The software used here was Stata V. 13 and $p < 0.05$ was considered significant.

Results

In this study, 156 patients were screened and 100 patients entered the two groups (cruciate and circular). In circular capsulotomy group, 3 patients were excluded because of unwillingness to continue the study and not participating in periodic examinations (Fig 1).



The two groups were almost identical at the beginning of the study and there was no significant difference in any of the variables (Table 1). The mean energy used for the two groups was different in this study. Accordingly, mean energy used in circular group (345 ± 68.53) was significantly higher than cruciate group (284.4 ± 46.78) ($p = 0.001$). No sign of intraocular inflammation, macular edema, ocular displacement and retinal detachment was observed in any of the groups at difference times. The vision between the two groups was not significantly different (Table 2), where changes in vision increased significantly over time ($p = 0.001$), but the interaction

between the group and time was not significant; i.e. the changing process in vision was not different between the two groups (Fig 2).

Table 1. Comparison of baseline variables according to each of the two groups

Variable		Cruciate (50 eyes) Mean±SD	Circular (47 eyes) Mean±SD	P-value
Gender N(%)	Female	31(62)	32(68.09)	0.530
	Male	19(38)	15(31.91)	
Pitting N(%)	Yes	16(8)	7(14.86)	0.880
	No	42(84)	40(85.11)	
age		66±14.43	67.23±12.97	0.659
Capsule volume		5.85±0.79	5.93±0.98	0.685
The period between cataract surgery and incidence of capsular opacification		30.80±37.28	32.61±33.16	0.772
Mean vision		2.48±1.69	2.55±1.58	0.826
Mean intraocular pressure		17.44±1.16	17.42±1.47	0.957

Table 2. Comparison of vision and intraocular pressure before capsulotomy and one day, one week and one month after capsulotomy between the two groups

Group		Mean±SD	CI-95% Min Max	
Cruciate	Vision			
	Before capsulotomy	2.48±1.69	2.14	2.81
	One day	1.28±1.45	2.94	3.61
	One week	5.84±1.85	5.50	6.17
	One month	6.56±0.70	6.22	6.89
Circular	Before capsulotomy	2.55±1.58	2.21	2.89
	One day	3.21±1.45	2.87	3.55
	One week	5.87±1.19	5.53	6.21
	One month	6.65±0.84	6.31	7.00
Cruciate	Intraocular pressure			
	Before capsulotomy	17.44±1.19	17.23	17.64
	One day	17.84±0.99	17.63	18.04
	One week	18.00±1.01	17.79	18.20
	One month	18.00±0.72	17.79	18.20
Circular	Before capsulotomy	17.42±1.47	17.21	17.63
	One day	18.38±1.15	18.17	18.59
	One week	18.40±0.97	18.19	18.61
	One month	18.23±0.83	18.02	18.44

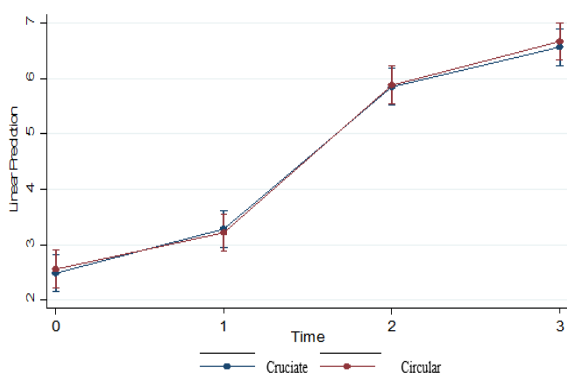


Figure 2. Comparison of vision before capsulotomy and one day, one week and one month after capsulotomy between the two groups.

Moreover, analysis of variance with repeated data demonstrated that the mean difference in intraocular pressure between the two groups was not significant, whereas mean changes in intraocular pressure increased significantly over time ($p=0.001$). However, the interaction between group and time was not significant; i.e. the changes in intraocular pressure was not different between the two groups (Fig 3). Moreover, there was no significant difference between the two groups in terms of percentage of halo (specified by GEE).

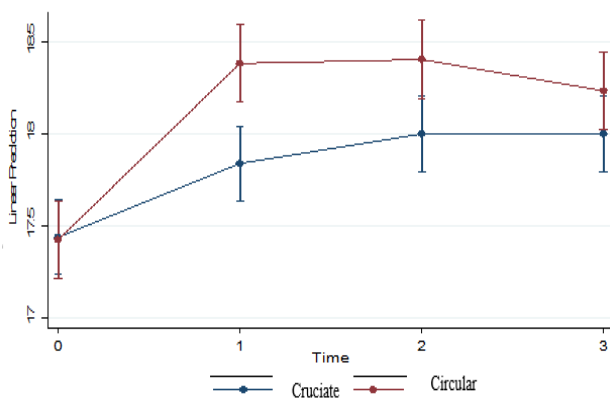


Figure 3. Comparison of intraocular pressure before capsulotomy and one day, one week and one month after capsulotomy between the two groups

Discussion

Results of this study indicated that there is not a significant difference between the two methods of Nd:YAG laser posterior capsulotomy in terms of visual acuity improvement. Moreover, intraocular pressure was also the same in the two groups. However, the consumed energy in cruciate method was

significantly lower than circular method. This study also revealed that in both methods of Nd:YAG laser posterior capsulotomy, visual acuity improved in one month and there was not a significant difference between the two methods. Several studies have been dedicated to the effect of Nd:YAG laser posterior capsulotomy on visual acuity improvements and changes in intraocular pressure.

Kara et al. did not report a statistically significant difference between the two groups in terms of visual acuity improvement (14). These results are in line with the results of the present study. Contrary to our study, Mortazavi et al. found that posterior capsulotomy improves visual acuity, however, sensitivity to contrast and the light source of visual acuity is not related to the type of lens used (17). It was also found that increased intraocular pressure, which is a complication of laser capsulotomy, during the first day and first week was more in circular group.

However, this difference is not clinically significant and considering that energy consumption in circular method is more than cruciate method (similar to the study of Kara et al.), using cruciate can be of higher priority. Kara et al. also did not observe a significant difference in intraocular pressure between the two groups (14).

Mechanisms of IOP increase after Nd:YAG include debris accumulation in the trabecular network, papillary block, inflammation of ciliary objects or iris root associated with angle closure. The presence of halo in the visual range was more in cruciate method, but the difference was only significant on the first day after surgery. Regarding other complications such as pitting, macular edema, retinal separation, intraocular inflammation and intraocular displacement, there was not a significant difference between the two methods. Some studies the presence of cystoid macular edema and some others did not find a significant difference in macular thickness after Nd:YAG.

The possible mechanism of macular edema include the release of inflammatory elements such as prostaglandin from the anterior chamber, which pass through the vitreous to reach the retina and cause leakage from capillary blood vessels around the yellow stains and finally cause edema and increase in macular thickness. Kara et al. did not observe significant changes in macular thickness in the two groups. In addition, they found that incidence of flutter in circular method was significantly higher than cruciate method (14). Goma et al. found that 47% of surgeons use

cruciate method, 27.3% use circular method, 23.5% use both methods and 2.3% use other methods (18). This indicates the priority of cruciate method compared with other methods.

One of the limitations of this study was small sample size and it is suggested that future studies use bigger sample size in a multicenter setting and longer follow-up to provide the possibility for secondary studies and more accurate conclusion. The impossibility of longer follow-up and observing the complications for a longer period due to time and financial limitations were other limitations of this

study. None of the two methods of Nd:YAG is preferred over the other method in terms of visual acuity improvement. However, the cruciate method is a better option due to lower energy consumption and fewer changes in intraocular pressure.

Acknowledgments

Hereby, we express our deepest sense of gratitude and indebtedness to Arak University of Medical Sciences for their financial support and all the patients who participated in this study.

References

1. Cai JP, Cheng JW, Wei RL, Ma XY, Jiang F, Zhu H, et al. Prophylactic use of timolol maleate to prevent intraocular pressure elevation after Nd-YAG laser posterior capsulotomy. *Int ophthalmol*. 2008;28(1):19-22.
2. Schaumberg DA, Dana MR, Christen WG, Glynn RJ. A systematic overview of the incidence of posterior capsule opacification. *Ophthalmol*. 1998;105(7):1213-21.
3. Apple DJ, Solomon KD, Tetz MR, Assia EI, Holland EY, Legler UF, et al. Posterior capsule opacification. *Surv Ophthalmol*. 1992;37(2):73-116.
4. Gwon A. Lens regeneration in mammals: a review. *Surv Ophthalmol*. 2006;51(1):51-62.
5. Findl O, Neumayer T, Hirschnall N, Buehl W. Natural course of Elschnig pearl formation and disappearance. *Invest Ophthalmol Vis Sci*. 2010;51(3):1547-53.
6. Neumayer T, Findl O, Buehl W, Sacu S, Menapace R, Georgopoulos M. Long-term changes in the morphology of posterior capsule opacification. *J Cataract Refract Surg*. 2005; 31(11):2120-8.
7. Thompson AM, Sachdev N, Wong T, Riley AF, Grupcheva CN, McGhee CN. The Auckland Cataract Study: 2 year postoperative assessment of aspects of clinical, visual, corneal topographic and satisfaction outcomes. *Br J Ophthalmol*. 2004; 88(8):1042-8.
8. Dholakia SA, Vasavada AR. Intraoperative performance and longterm outcome of phacoemulsification in age-related cataract. *Indian J Ophthalmol*. 2004;52(4):311-7.
9. Cinal A, Demirok A, Yasar T, Yazicioglu A, Yener HI, Kilic A. Nd:YAG laser posterior capsulotomy after pediatric and adult cataract surgery. *Ann Ophthalmol*. 2007;39(4):321-6.
10. Murrill CA, Stanfield DL, Van Brocklin MD. Capsulotomy. *Opto Clin: Offic Pub Pren Soc*. 1995;4(4):69-83.
11. MacEwen CJ, Dutton GN. Neodymium-YAG laser in the management of posterior capsular opacification--complications and current trends. *Trans Ophthalmol Soc UK*. 1986;105(3):337-44.
12. Javitt JC, Tielsch JM, Canner JK, Kolb MM, Sommer A, Steinberg EP. National outcomes of cataract extraction. Increased risk of retinal complications associated with Nd:YAG laser capsulotomy. The Cataract Patient Outcomes Research Team. *Ophthalmology*. 1992;99(10):1487-97.
13. Hu CY, Woung LC, Wang MC, Jian JH. Influence of laser posterior capsulotomy on anterior chamber depth, refraction, and intraocular pressure. *J Cataract Refrac Surg*. 2000;26(8):1183-9.
14. Kara N, Evcimen Y, Kirik F, Agachan A, Yigit FU. Comparison of two laser capsulotomy techniques: cruciate versus circular. *Sem Ophthalmol*. 2014;29(3):151-5.
15. Sealed Envelope Ltd. 2015. Create a blocked randomisation list. [Online] Available from: <https://www.sealedenvelope.com/simple-randomiser/v1/lists> [Accessed 2 Sep 2015].
16. Sellman TR, Lindstrom RL. Effect of a plano-convex posterior chamber lens on capsular opacification from Elschnig pearl formation. *J Cataract Refrac Surg*. 1988;14(1):68-72.
17. Mortazavi SA, Eslami F, Atarzadeh H, Nasrollahi K, Ghoreishi SM. Evaluation of visual function improvement after ND: YAG laser posterior capsulotomy in patient with posterior capsule opacification. *J Isfahan Med School*. 2008;26(88):62-9.[In Persian]
18. Goma A, Liu C. Nd: YAG laser capsulotomy: a survey of UK practice and recommendations. *Eur J Ophthalmol*. 2011;21(4):385.