Journal of
Babol University of Medical Sciences
JBUMS
e-ISSN: 2251-7170 p-ISSN: 1561-4107

An Evaluation of the Effect of Lettuce Seed Oil on Buccal Mucosa Healing

N. B. Kamil (PhD)[*1]

1.Department of Oral Diagnosis, College of Dentistry, University of Baghdad, Baghdad, Iraq.

•Corresponding Author: N. B. Kamil (PhD)
Address: Department of Oral Diagnosis, College of Dentistry, University of Baghdad, Baghdad, Iraq.
Tel: -. **E-mail:** nawar.bahjat@codental.uobaghdad.edu.iq

Article Type

Research Paper

Received:
Jul 7th 2024
Revised:
Sep 23rd 2024
Accepted:
Oct 12nd 2024

ABSTRACT

Background and Objective: The oral mucosa acts as a barrier against pathogens, and in cases of trauma, we are looking for a way to accelerate their recovery. Since lettuce seed oil has antibacterial, anti-inflammatory, and antioxidant effects, this study was conducted to evaluate the effect of lettuce seed oil on the repair of buccal mucosa in rats.

Methods: In this experimental study, 24 adult male rats were used. Incisional wound with a length of about 1 cm was created by a sharp knife on the left and right side of the buccal mucosa in each rat. The total number of wounds was 48 and the rats were randomly divided into two groups: Control group included 12 rats and 24 wounds that were divided into three healing periods (1, 3 and 7 days) left without treatment. The experimental group included 12 rats and 24 wounds which were treated with 5µL of lettuce oil applied by micropipette and they were divided into three healing periods (1, 3 and 7 days). The specimens were prepared and stained with hematoxylin and eosin as well as Masson's trichrome and they were evaluated.

Findings: Compared with the control group, the rate of epithelial regeneration increased in the experimental group. After 24 hours, there was a significant difference between the control and experimental groups in inflammatory cells (9.82±0.96 vs. 28.39±5.01) (p=0.000). After 72 hours, the experimental groups recorded higher mean epithelial thickness (9.58±1.23), blood vessels (8.51±0.75) and collagen fiber density (38.62±4.01) compared to the control group (4.67±0.08, 3.47±0.79 and 15.85±2.57, respectively). There was a significant difference in inflammatory cells, epithelial thickness and collagen fiber intensity (p=0.000). After the seventh day, there was a significant difference in all parameters between the control and experimental groups except blood vessels (p=0.000).

Conclusion: Lettuce seed oil has an effective role in acceleration of buccal mucosa healing in rats.

Keywords: *Lettuce Seed Oil, Masson's Trichrome Staining, Healing*.

Cite this article: Kamil NB. An Evaluation of the Effect of Lettuce Seed Oil on Buccal Mucosa Healing. *Journal of Babol University of Medical Sciences*. 2026; 28: e4.

Copyright © 2026 Babol University of Medical Sciences. Published by Babol University of Medical Sciences. This work is licensed under a Creative Commons Attribution-NonCommercial 4.0 International license (https://creativecommons.org/licenses/by-nc/4.0/). Noncommercial uses of the work are permitted, provided the original work is properly cited.

Introduction

The present study was conducted to find a method to accelerate buccal mucosa healing using a natural product because oral mucosa acts as a barrier against pathogen through its composition of superficial epithelium and underlying basement membrane (1), so it must repair at a shorter time. The epithelium is made up of densely packed epithelial cells with varied degrees of differentiation. The undifferentiated cells found in the basal cells divide continuously, and then move up through layers of supra basal cells and undergo different morphological and biochemical changes based on the type and region of mucosa (2). The oral epithelium, particularly the keratinized oral mucosa, is composed of several layers, including the basal layer, spinous layer, granular (keratinized epithelium) or intermediate layer (non- keratinized epithelium), and the superficial layer (non-keratinized epithelium) (3).

Oral mucosa healing is characterized by the following steps: hemostasis, inflammation, proliferation and maturation (4). Hemostasis occurs immediately after injury, and when blood vessels are damaged, the immune system is activated within seconds to reduce the level of injury (5). Inflammatory phase peak occurs within 24 to 48 hours and improves the removal of debris and pathogen through activation of immune system (6). The proliferation phase occurs within several days after injury, which is characterized by the onset of re-epithelialization from wound edges in response to cytokines and growth factors. The last phase of wound healing is the maturation phase, which means tissue repair and may continue up to two years (7).

Lettuce oil is extracted from the seeds of lettuce plant and is characterized by high levels of linoleic and oleic acids. It is known for its potential benefits, including effective performance and immunity in various studies. It includes a variety of vital components for human health, including potassium, salt, calcium, and vitamin A. It also serves as a small source for a number of other vitamins and minerals (8). Moreover, it contains phenolic compound, which acts as an antimicrobial and anti-fungal agent. It also benefits from anti-oxidant effects due to its composition of ascorbic acid and polyphenol compound. In addition to being a great source of iron and folic acid, lettuce is a major source of vitamin K and has high beta-carotene content (9). The pharmacological activities of lettuce include hypoglycaemic activity, anxiolytic activity, sedative activity, antiaging activity, antimicrobial activity, protective activity, neuroprotective activity, analgesic, anti-depressant and anticoagulant activity (10). The purpose of the present study is to evaluate the effect of lettuce seed oil on oral mucosa healing, as well as its anti-inflammatory, antioxidant, and anti-bacterial properties.

Methods

This in vivo study was approved by the University of Baghdad College of Dentistry with the ethical committee code 916, Project No. 916724 in 12-5-2024. Lettuce seeds were collected and ground using an electric mill and were mixed twice with methanol and chloroform (2:1 volume) in a thermal blender. The resulting extract was dried with anhydrous sodium sulfate and the filtrate was subjected to a rotary evaporator under reduced pressure at 50°C for solvent extraction. Until the time of experiments, the oil samples were stored in hermetically sealed containers at 0°C to prevent autoxidation (11).

Study samples: 24 adult male rats weighting 300-500 gram and aged 7-9 months were used in this study. Rats were randomly divided into two groups: Control group and the experimental group, each group containing 12 rats. Therefore, the total number of incisional wounds was 24 in each group and they were divided into three healing periods (1, 3 and 7 days).

Surgical process and slide preparation: Rats were put to sleep using a general anesthetic administered by inhalation. Incisional wounds were created by a sharp knife on the left and right side of the buccal mucosa on each rat with a length of about one centimeter (12). The control group was left without treatment at the left side. The experimental group was treated with 5µL lettuce oil, which was applied by micropipette inside the wound at the right side.

After each healing period (8 rats), the buccal mucosa from the incisional wound (n=16) was taken and put in 10% formalin. The specimens were then processed through routine histological techniques. Each paraffin embedded sample was cut into 5µm sections (13). Each slide was stained with H&E and Masson's trichrome chemical stain (14). Masson's trichrome technique was performed by re-fixing and leaving in Boun's solution at 56ºC for one hour. Each specimen was rinsed under running water for five minutes to get rid of the picric acid. The specimen was then stained for ten minutes in a working solution of Weigert's iron hematoxylin. Next, it was rinsed for five minutes under running water and then rinse with distilled water for a minimum of five minutes using Biebrich Scarlet - Acid Fuchsin Solution. After about ten minutes, phosphotungstic/phosphomolybdic acid was disposed of.

Then, the slide was emptied and switched to the Aniline Blue for histological analysis of wound healing (15). A light microscope was used to examine each slide to evaluate the collagen fiber, which had a blue color. Histological analysis of wound healing was done in all healing periods. Epithelial thickness was measured in µm by Image J under power 40 in a 1.92×1.40 mm field by taking the mean of two readings of the distance at the wound's borders between the uppermost layer and its innermost basal layer (16). A field dimension of 1.90×1.44 mm was used in calculating inflammatory cells and blood vessels. Inflammatory cell count was calculated under power 40 in five fields and the mean number of the cells and the number of blood vessels were calculated under power 40 (14). Collagen fiber density percentage (%) analysis was done by Masson's trichrome staining in 3 and 7 days under power 40 using the Image J program through applying the following equation: average collagen intensity under wound / average collagen intensity in normal lamina propria multiplied by 100 (17).

The SPSS 25 program was used to examine the data. Descriptive analysis and ANOVA for variance analysis were used, and $p<0.05$ was statistically significant.

Results

After one day: Infiltration of inflammatory cells was seen in both groups. Proliferation of basal cells at the cutting edge and regeneration of epithelial layer were also seen in the experimental group. Necrotic tissue and new blood vessel are also visible, as shown in Figure (1: A, B). The experimental group recorded a higher mean value in all parameters compared to the control group (Figure 2). There was a highly significant difference between them in inflammatory cells count and a significant difference in the epithelial thickness and blood cell count (Table 1).

After three days: Decrease in the number of inflammatory cells in experimental group was visible and new epithelial tissues were formed. The control group showed regeneration of epithelial layer at the cutting edge and remnant of necrotic tissue. Blood vessels and fibroblast cells were formed in both groups (Figure 1: C, D). The experimental group recorded a higher mean value in the epithelial thickness, blood vessels account and in the collagen fiber density compared to the control group, while the control group recorded a higher mean value in the inflammatory cells count compared to the experimental group (Figure 2). There was a highly significant difference in the inflammatory cells, epithelial thickness and collagen fiber intensity, but there was a significant difference in the blood vessel between the control group and the experimental group (Table 1).

After seven days: Complete formation of epithelial layer and collagen fiber formation in the experimental group were visible but in the control group, the epithelial layer still had incomplete formation, and blood vessels and fibroblast cells can be seen in (Figure 1: E, F). The experimental group recorded a higher mean value in the epithelial thickness and collagen fiber density than the control group, but the control group recorded a higher mean value in the inflammatory cells count than the experimental group (Figure 2). There was a highly significant difference in the epithelial thickness, inflammatory cells and collagen fiber intensity, while there was a non-significant difference in the blood vessel count between the control and experimental groups (Table 1).

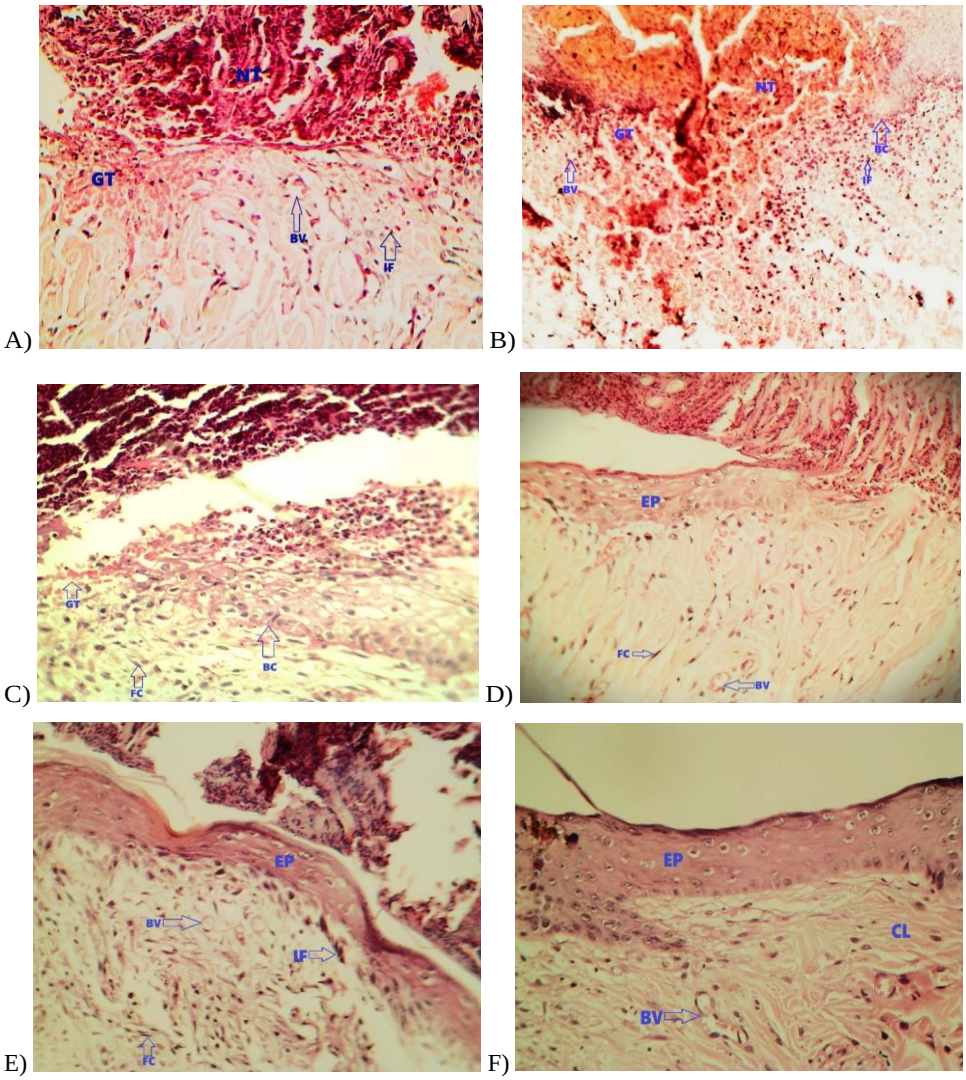

Figure 1. Histological view of defective area in H&E staining (X20). A) After 24 hours, Control group showed NT: Necrotic tissue, GT: Granulation tissue, BV: Blood vessel and IF: Inflammatory cells. B) After 24 hours, Experimental group showed NT: Necrotic tissue, GT: Granulation tissue, BV: Blood vessel, IF: Inflammatory cells and BC: Basal cells proliferation. C) After 72 hours, Control group showed GT: Granulation tissue, FC: Fibroblast cells and BC: Basal cells proliferation. D) After 72 hours, Experimental group showed FC: Fibroblast cells, BV: Blood vessel and EP: Epithelial layer. E) After 7 days, Control group showed EP: Epithelial layer, FC: Fibroblast cells, BV: Blood vessel and IF: Inflammatory cells. F) After 7 days, Experimental group showed EP: Epithelial layer, CL: Collagen fiber and BV: Blood vessel.

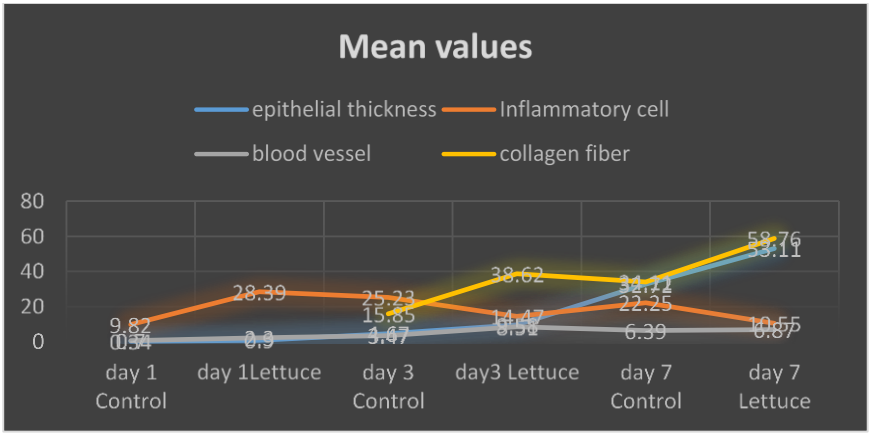

Figure 2. Mean values of epithelial thickness, inflammatory cell, blood vessel and collagen fiber

Table 1. Mean, standard deviation, standard error and p value for all parameter in different periods

Parameter	Group	N	Mean	SD	SE	p-value
Day 1						
Epithelial thickness	C	8	0.34	0.07	0.01	0.03
	L	8	0.9	0.43	0.12	
Inflammatory cells	C	8	9.82	0.96	0.09	0.000
	L	8	28.39	5.01	0.59	
Blood vessel	C	8	0.70	0.73	0.26	0.02
	L	8	2.30	0.41	1.13	
Day 3						
Epithelial thickness	C	8	4.67	0.08	0.15	0.000
	L	8	9.58	1.23	1.02	
Inflammatory cells	C	8	25.23	3.17	0.81	0.01
	L	8	14.47	3.84	1.13	
Blood vessel	C	8	3.47	0.79	0.31	0.02
	L	8	8.51	0.75	0.28	
Collagen fiber density	C	8	15.85	2.57	1.29	0.000
	L	8	38.62	4.01	1.77	
Day 7						
Epithelial thickness	C	8	32.72	2.46	1.09	0.000
	L	8	53.11	1.76	0.72	
Inflammatory cells	C	8	22.25	3.68	1.66	0.000
	L	8	10.55	1.73	0.62	
Blood vessel	C	8	6.39	1.16	0.41	0.07
	L	8	6.87	0.61	0.21	
Collagen fiber density	C	8	34.11	3.69	1.56	0.000
	L	8	58.76	2.88	1.34	

0.05≥p>0.01=significant

p≤0.01=highly significant

Findings of Masson's trichrome staining: after 72 hours, the control group showed little fibrin in the incisional area and blood vessels which contributes to fibroblast cell migration. The experimental group showed fine collagen fiber formation and matrix deposition (Figure 3:A,B). After one week, collagen fiber formation was seen in both groups but more intensity in the experimental group (Figure 3: C, D).

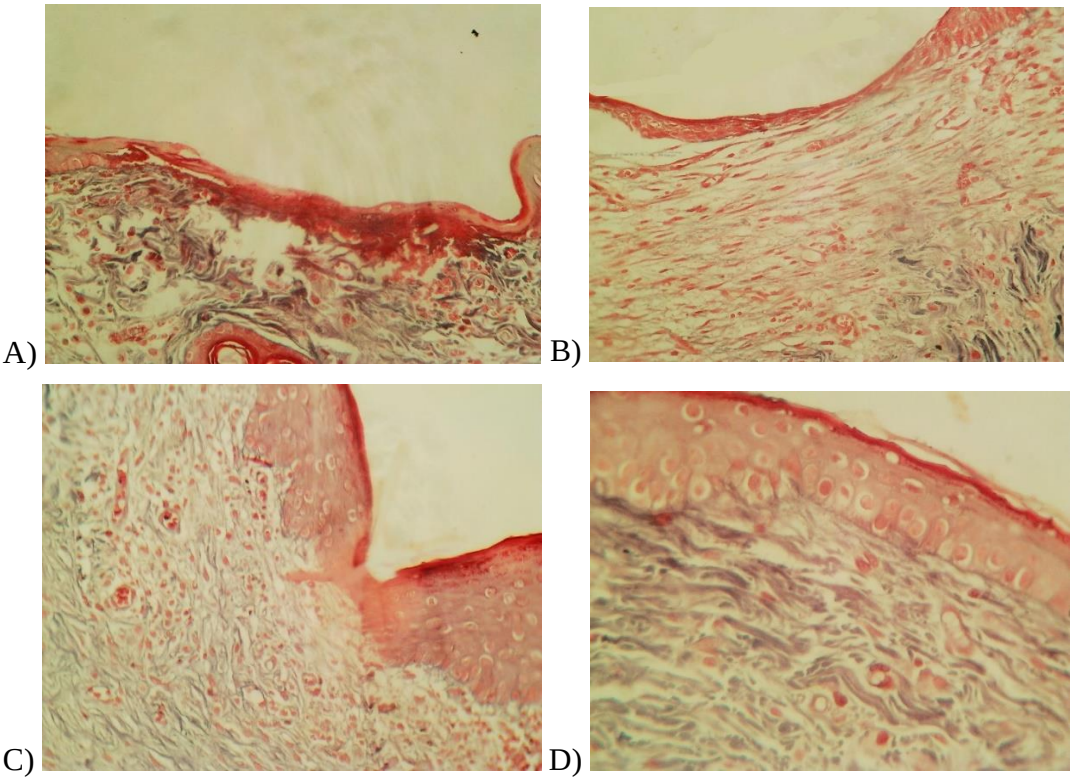

Figure 3. Viewing of defect area by Masson's trichrome staining under light microscope x20; red color indicated epithelial layer and blood vessel and blue color indicated collagen fiber. A) Control group after 72 hours. B) Experimental group after 72 hours. C) Control group after 7 days. D) Experimental group after 7 days.

Discussion

The current study showed that after 24 hours, the number of inflammatory cells in the experimental group was higher than the control group but after 72 hours and 7 days, the number was higher in the control group compared to the experimental group. This explained the acceleration in inflammatory process in the experimental group compared to the control group. This was due to the anti-inflammatory effect of lettuce oil, which contains 14-Dihydroxy-11, 8-Tigloyl-15-Deoxylactusin and 13-dihydrocostulenolide (Compound 1) working as antibiotic (10), and accelerates healing process in the experimental group. This result agreed with Al-Zubaid (17) who studied the effect of local application of Opuntia ficus-indica/Punica granatum oils on cutaneous wound healing which showed acceleration in inflammatory process in the experimental group compared to the control group.

Epithelial regeneration occurs at early stage by proliferation of the basal and sub-basal layer of the cutting edge. Immune cells produce cytokines and enhance proliferation of cells (18). The present study illustrated that epithelial regeneration increased with time in both groups but the experimental group recorded a higher mean value compared to the control group in all healing periods. This may be related to the immunological

effect of lettuce oil, which leads to the release of growth factors that promote inflammatory phase and reaction of immune cells with non-immune cells to remove debris and pathogens that guide tissue regeneration (19). Lettuce oil group showed almost complete re-epithelialization on day 7 but it was still incomplete in the control group. This was consistent with study of Ali et al (12) who showed that buccal mucosa healing accelerated with combined topical application of pomegranate and Aloe vera gel in comparison with the control group.

In the present study, the experimental group showed early process of angiogenesis compared to the control one at all healing periods. This may be related to the beta-carotene, quercetin and ascorbic acid compounds found in lettuce oil, which have an anti-oxidant effect (20). Antioxidant materials have an ability to enhance the activity of fibroblast growth factor, vascular endothelial growth factor, angiogenin, angiopoietin, and human mast cell tryptase, all of which activate angiogenic activity (21). The mean value of blood vessel count recorded on day 7 was lower in both groups compared to days 1 and 3, which is because of collagen fiber deposition; this agrees with a study by Kamil et al (14) who evaluated the effect of Myrrh oil on healing of the oral mucosa ulcer in rats, which showed early angiogenesis process in the experimental group compared to the control group.

In the present study, collagen fiber density recorded higher mean value in the experimental group compared to the control group on days 3 and 7, and recorded a highly significant difference. This is because lettuce oil is rich in vitamin, mineral and enzyme (20); lettuce also has antimicrobial, anti-inflammatory (22) and anti-oxidant effects (8). Because of these properties, lettuce oil showed acceleration in cell proliferation and differentiation, which in turn generated contraction forces that facilitate wound closure. Type III collagen 96% is deposited at the wound site by myofibroblasts, which also determine the fibril diameter of type I collagen and provide the tensile strength. This agrees with the study of Al-Zubaidy et al (17), who studied the effect of local application of Opuntia ficus-indica/Punica granatum oils on cutaneous wound healing, which showed acceleration in collagen fiber deposition in the experimental group compared to the control group. Lettuce oil has an effective role in oral mucosa healing by accelerating the healing time through regeneration of epithelium without any side effect and suggested application in osseointegration and bone healing defect.

Funding: This study was not supported by any organization.
Declaration of interest: The author state that there are no conflicts of interest in publishing this research.

Acknowledgment

The author would like to thank the professors in oral histology at the college of dentistry, university of Baghdad, Iraq, for their cooperation in this study.

References

1.Cho SK, Mattke S, Gordon H, Sheridan M, Ennis W. Development of a Model to Predict Healing of Chronic Wounds Within 12 Weeks. Adv Wound Care (New Rochelle). 2020;9(9):516-24.

2.Groeger S, Meyle J. Oral Mucosal Epithelial Cells. Front Immunol. 2019;10:208.

3.Wang SS, Tang YL, Pang X, Zheng M, Tang YJ, Liang XH. The maintenance of an oral epithelial barrier. Life Sci. 2019;227:129-36.

4.Politis C, Schoenaers J, Jacobs R, Agbaje JO. Wound Healing Problems in the Mouth. Front Physiol. 2016;7:507.

5.Eming SA, Martin P, Tomic-Canic M. Wound repair and regeneration: mechanisms, signaling, and translation. Sci Transl Med. 2014;6(265):265sr6.

6.Glim JE, Beelen RH, Niessen FB, Everts V, Ulrich MM. The number of immune cells is lower in healthy oral mucosa compared to skin and does not increase after scarring. Arch Oral Biol. 2015;60(2):272-81.

7.Wietecha MS, DiPietro LA. Therapeutic Approaches to the Regulation of Wound Angiogenesis. Adv Wound Care (New Rochelle). 2013;2(3):81-6.

8.Soliman MS, Qattan SYA, Reda FM, Mohamed LA, Mahgoub SA, Othman SI, et al. Does dietary supplementation with lettuce seed oil enhance broiler performance, immunity, lipid profile, liver and kidney functions, antioxidant parameters, and intestinal microbiota?. Poult Sci. 2024;103(3):103409.

9.Mohammed HA, Razaaq SR. Effect of additive garlic, black seeds and lettuce leaves in diet of local layers hen on performance, carcass qualities characteristic and chemical composition. Plant Arch. 2020;20(2):1685-90.

10.Oladimeji AV, Kumar AB. Therapeutic profile of lettuce: Leafy vegetable for moderate consumption (A review). Int J Adv Biochem Res. 2023;7(2):254-8.

11.El-Mallah MH, El-Shami SM. Evaluation of the oil Produced from lettuce crop cultivated under three irrigation conditions. Grasas Y Aceites. 2012;63(4):423-31.

12.Ali ZM, Jamil BA. In Vivo Histological Evaluation of the Effect of Pomegranate and Aloe Vera and a Combination of Both on Wound Healing of Buccal Mucosa. J Nat Sci Res. 2016;6(14):41-55.

13.Kanber AA, Kadhim EF. Efficacy of Locally Applied K-Carrageenan on the Healing of Thermal Burn in Rat-Experimental Model: Histological Study. J Res Med Dent Sci. 2022;10(9):160-5.

14.Kamil NB, Al-Ghaban NM. Evaluation of effect of local exogenous application of Myrrh oil on healing of wound incisions of facial skin (Histochemical, Histological and Histomorphometrical study in rabbits). J Bagh Coll Dent. 2019;31(4):71-8.

15.Meinen S, Barzaghi P, Lin S, Lochmüller H, Ruegg MA. Linker molecules between laminins and dystroglycan ameliorate laminin-alpha2-deficient muscular dystrophy at all disease stages. J Cell Biol. 2007;176(7):979-93.

16.Abed AT, Al-Ghaban NM. Acceleration of Ulcer Healing by Local Application of Myrrh Oil: An Experimental Study. Al-Anbar Med J. 2023 Jul 1;19(2):128-34.

17.Al-Zubaidy EY, Ghani BA. Ibrahim NR. Local application of Opuntia ficus-indica / Punica granatum oils on cutaneous wound healing: a histochemical study. J Bagh Coll Dent. 2023;35(4):28-34.

18.Guenin-Mace L, Konieczny P, Naik S. Immune-Epithelial Cross Talk in Regeneration and Repair. Annu Rev Immunol. 2023;41:207-28.

19.Cioce A, Cavani A, Cattani C, Scopelliti F. Role of the Skin Immune System in Wound Healing. Cells. 2024;13(7):624.

20.Abdel-Magied N, Ahmed AG. The Protective Role of Lettuce oil (Lactuca sativa) against Radiation induced Biological Hazards in male rats. J Rad Res Appl Sci. 2011;4(3):923-38.

21.Tonnesen MG, Feng X, Clark RA. Angiogenesis in wound healing. J Investig Dermatol Symp Proc. 2000;5(1):40-6.
22.Araruna K, Carlos B. Anti-inflammatory activities of triterpene lactones from Lactuca sativa. Phytopharmacology. 2010;1(1):1-6.