Journal of
Babol University of Medical Sciences
JBUMS
e-ISSN: 2251-7170 p-ISSN: 1561-4107

Comparing the Effect of Squalane Oil and Rosehip Oil on Facial Wound Healing of Rats Using H&E and Mason Trichrome Stain

J. A. Mohammed Saeed (DDS)[*1], E. Fadhil Kadhim (DDS, MS)[1]

1.Department of Oral Diagnosis, College of Dentistry, University of Baghdad, Baghdad, Iraq.

***Corresponding Author: J. A. Mohammed Saeed (DDS)**
Address: Department of Oral Diagnosis, College of Dentistry, University of Baghdad, Baghdad, Iraq.
Tel: +964 (781) 8285100. **E-mail:** jwan.arkan2106m@codental.uobaghdad.edu.iq

Article Type

Research Paper

Received:
Apr 23rd 2024
Revised:
Jul 20th 2024
Accepted:
Aug 6th 2024

ABSTRACT

Background and Objective: The healing process is necessary for the preservation of the barrier function of the skin. Today, the global medical trend is moving from chemical drugs towards herbal medicines. Squalane can influence the immunomodulation of macrophages which helps the "last stage remodeling and wound closure" because of its anti-inflammatory properties and rosehip oil can shorten epithelialization time and reduce inflammatory cell infiltration. Therefore, the present study was conducted to examine and compare the effectiveness of squalene oil and rosehip oil separately in the healing process of facial skin wounds in rats.

Methods: In this controlled trial, 28 male Albino rats, aged 4-6 months old and weighing 200-350g underwent surgical incisions on their facial skin using a surgical blade applied to the cheek. The animals were categorized into the following groups: In the control group, where the number of rats was equal to the experimental group, an incision was made on the left cheek and the rats were left to heal spontaneously without any treatment. In the experimental group, an incision was made on the right cheek and they were divided into the following groups: Group 1: 14 rats were treated daily with 30µl of squalene oil using a micropipette. Group 2: 14 rats were treated daily with 30µl of rosehip oil using a micropipette. Then each group was subdivided into 2 subgroups (7 rats for each) according to healing intervals of 3 and 7 days. The samples were collected and processed for histological analysis using H&E stain to evaluate the thickness of the epithelial layer and the number of inflammatory cells. Additionally, the histochemical examination was conducted using Masson's trichrome stain to examine the intensity of collagen fibers. Wound contraction was also evaluated clinically on the 3rd and 7th day after wounding.

Findings: Significant differences in wound contraction were seen on day 7. The group that received squalane oil exhibited the greatest level of wound contraction, with an average wound diameter of 0.70±0.112 mm. In contrast, the rosehip oil group had the lowest average value of 1.0000±0.114 mm, p=0.004. Regarding the number of inflammatory cells on day 3, the control group had the greatest number of inflammatory cells, with a mean value of 52.83±10.24, whereas the squalane oil group had the lowest mean value (28.89±11.24) (p=0.02). On day 3, the control group exhibited the highest epithelial thickness, with a mean value of 114.89±33.63µm, while the squalane oil group had the lowest thickness (74.99±16.11µm) (p=0.046). On day 7, the squalane oil group had the highest intensity of collagen fibers, with a mean value of 118.50±12.88, while the control group had the lowest intensity (102.97±4.94) (p=0.03).

Conclusion: The study's findings demonstrated that the use of squalane oil resulted in enhanced wound contraction, decreased presence of inflammatory cells, and increased production of collagen. Nevertheless, the thickness of the epithelial layer was similar to that of the control group. Rosehip oil demonstrated a decrease in inflammatory cells and an increase in collagen fibers when compared to the control group. However, the wound required additional time for the process of wound contraction, and the thickness of the epithelial layer was similar to that of the control group.

Keywords: *Squalane Oil, Rosehip Oil, Wound Healing, Herbal Medicine*.

Cite this article: Mohammed Saeed JA, Fadhil Kadhim E. Comparing the Effect of Squalane Oil and Rosehip Oil on Facial Wound Healing of Rats Using H&E and Mason Trichrome Stain. *Journal of Babol University of Medical Sciences*. 2025; 27: e54.

Copyright © 2024 Babol University of Medical Sciences. Published by Babol University of Medical Sciences. This work is licensed under a Creative Commons Attribution-NonCommercial 4.0 International license (https://creativecommons.org/licenses/by-nc/4.0/). Noncommercial uses of the work are permitted, provided the original work is properly cited.

[DOI: 10.22088/jbums.27.1.54]

Introduction

The skin functions as a protective barrier against external factors; however, extensive damage can lead to severe consequences, underscoring the necessity of an efficient wound-healing system to restore tissue integrity and functionality (1). Globally, medicine is shifting from synthetic to herbal, a trend called "return to nature". Although herbal medicines have been shown to have medical benefits, their usage is still disputed due to a lack of basic research, a small sample size, and rigorous analytical procedures. The benefits of herbal oils require further research, particularly basic investigations to understand their mechanisms (2, 3).

Squalene is a colorless, odorless liquid oil. It came from shark liver oil, but later it was also found in several plant extracts such as olive oil and amaranth oil. Squalene is also found in many organs and tissues of the human body. The liver synthesizes squalene and directs it into the systemic circulation. Squalene makes up around 12% of human skin surface lipids, likely because human skin is less hairy than other mammals and needs more ways to counteract UV radiation' photo-oxidative effect (4). Squalene is used to treat various malignancies and lower cholesterol and triglyceride levels. The chemical is highly sought after due to its increasing use in the cosmetic, nutraceutical, and pharmaceutical sectors (5). Squalane is the saturated form of squalene which is more stable and less likely to undergo oxidation, which is why it is preferred in personal care products (6).

Rosehip oil is applied in the pharmaceutical, cosmetics, and food sectors. The oil is derived from the rosehip (Rosa canina L.) plant and mostly contains linolenic acid, linoleic acid, and oleic acid (7). The anti-cancer effect is one of the most well-recognized health-promoting properties of rosehip oil. Rosehip oil has become popular recently for cosmetic use due to its therapeutic impact on skin treatments (8). The objective of this study was to assess the impact of using squalane oil and rosehip oil topically on skin wounds and their advantages in the healing process by clinical, histological, and histochemical techniques.

Methods

In this controlled animal trial, after being approved by the ethics committee for utilizing animals in research, as outlined by the College of Dentistry/University of Baghdad (Reference Number: 704 on 1/12/2022, project number: 704722), 28 male Albino rats (Rattus norvegicus albinus) were chosen, which aged 4-6 months and weighed 200-350g. All rats were maintained under controlled ventilation conditions, temperature, housing and feeding, and were given a standard diet (pellet) with an easy access to tap water. The rats were housed in plastic cages at a temperature of 23±2°C for a week before the surgical procedure. Before the experiment, the rats were examined by a veterinary doctor to assess their health and ensure that only healthy animals were included in the study. This was all done at the Iraqi Center for Cancer Research and Medical Genetics.

A total number of 28 rats were subjected to facial skin wounds on the right and the left cheek. The animals were categorized into the subsequent groups:

A. The control group, in which wound was created on the left cheek and followed the number of the experimental group and left for spontaneous healing without any treatment.

B. The experimental group, in which wound was located on the right cheek and was subdivided into the following groups: Group 1: 14 rats were administered a daily dose of 30µl of squalene oil using a micropipette. Group 2: 14 rats were administered a daily dose of 30µl of rosehip oil using a micropipette.

[DOI: 10.22088/jbums.27.1.54]

Then, each group was subdivided into 2 subgroups (7 rats for each) according to healing intervals of 3 and 7 days. The samples were collected and processed for histological analysis using H&E stain and histochemical evaluation using Masson's trichrome stain to evaluate the intensity of collagen fibers.

Materials and surgical process: All surgical instruments were sterilized by heating in an autoclave at 150ºC for one hour to ensure they were free from contamination. General anesthesia solution was administered, which contained 80% ketamine (at a dose of 40 mg/kg) and 20% xylazine (at a dose of 5 mg/kg) (9). The hair on the cheeks was removed. Then, using surgical blade no.11, a full-thickness skin incision 1.5 cm in length was made externally on both sides of the cheeks of the rats according to the groups mentioned above.

Histological method: The rats were anesthetized, and a full-thickness skin biopsy was performed. The specimens were immersed in a 10% formaldehyde solution for 24 hours to undergo processing. Subsequently, they were embedded in standard paraffin blocks and sliced into sections with a thickness of 4μm. These sections were then mounted on glass slides for staining with H&E and Mason trichrome (10, 11).

Wound healing assessment: Wound healing assessment was conducted using the following methodologies:

1.Assessment of wound contraction.

2.Histological assessment:

a) Epithelial thickness parameter.

b) Inflammatory cell count.

3.Histochemical assessment using mason trichrome stain.

Assessment of Wound contraction: On the third and seventh days, the rats received general anesthesia, and their wounds were evaluated using a Vernier caliper, measuring the extent of wound contraction in millimeters.

The calculation of wound closure was determined using the following formula:

Wound closure percentage= [(D0-Dd)/D0]*100. Where D0 is the initial wound diameter (1.5 cm). Dd is the wound diameter on measurement day (day 3 or day 7) (12).

Histological analysis: According to Holzer-Geissler et al (13), an optical microscope with a square grid in the eyepiece was used to analyze tissue samples. Five random fields were picked under 40x magnification and an average count of inflammatory cells was taken (14). The measurement of epithelial thickness was conducted using a light microscope at a magnification of X40. The distance between the outermost layer of keratin and the innermost basal layer of the epidermis at the wound edges was determined using Image J software version 1.54 (15).

Histochemical analysis: The collagen fiber intensity was measured with an x40 light microscope. The density of collagen beneath the wound was compared to that of the normal dermis. The average of the collagen values tested in the dermis of healthy persons was established as 100. The average collagen density beneath the lesion region for each group was quantified as a percentage relative to the collagen density of the healthy dermis.

Ratio= (Average collagen intensity under wound \ Average collagen intensity of normal dermis) × 100 (16, 17).

Statistical analysis: Statistics were utilized to analyze the data in this study. SPSS version 26 was used to characterize each variable thoroughly. The data were represented using statistical measures such as the mean, standard deviation, and range (minimum and maximum values). The independent groups were

[DOI: 10.22088/jbums.27.1.54]

compared using the analysis of variance (ANOVA) and post hoc testing, which included the least significant difference (LSD) test. A significance standard of 0.05 was employed to assess statistical significance at a confidence level of 95%.

Results

Wound contraction: The wound contraction examination revealed no significant changes between groups on day 3, but a substantial significance was found on day 7. On day 3, the rosehip oil group had the largest wound diameter (1.263±0.130 mm), while the control group had the smallest (1.110±0.108 mm). The rosehip oil group had the largest wound diameter on day 7, while the squalane oil group had the smallest as presented in (Table 1).

Inflammatory cell count: All study groups' mean inflammatory cell counts were evaluated throughout each healing period. Table 1 displays descriptive statistics for inflammatory cell count data gathered throughout different healing times. The control group had a considerably higher inflammatory cell count on day 3 compared to the squalane oil and rosehip oil groups, as indicated by the inflammatory cell parameter as seen in (Table 1). However, on day 7, no significant differences were detected.

Table 1. The descriptive statistics of wound contraction in millimeters (mm) and the inflammatory cells count for each group and healing duration

Wound contraction (mm)					
Variables	**Control group Mean±SD**	**Squalane oil group Mean±SD**	**Rosehip oil group Mean±SD**	**F test**	**p-value**
Day 3	1.110±0.108[a]	1.200±0.185[a]	1.263±0.130 [a]	1.46	0.247
Day 7	0.8133±0.068[a]	0.7014±0.112[b]	1.0000±0.114 [c]	6.135	0.004
Inflammatory cells count					
Variables	**Control group Mean±SD**	**Squalane oil group Mean±SD**	**Rosehip oil group Mean±SD**	**F test**	**p-value**
Day 3	52.83±10.24[a]	28.89±11.24[b]	31.35±8.99[c]	3.941	0.02
Day 7	45.33±5.69[a]	52.63±18.77[a]	38.13±11.28[a]	2.330	0.1

Epithelial thickness parameter: In general, the study concluded that the thickness of the epithelial layer increased with time in all of the groups. Table 3 provides descriptive statistics for the mean, median, and standard deviation of epithelial thickness at various healing periods for both the experimental and control groups. The results indicated that the thickness of the epithelium was substantially higher in the control group than in the squalane oil group on day 3. No significant differences were detected on day 7, as presented in (Table 2).

Collagen fiber intensity: The results showed that there was a consistent increase in collagen fibers in all groups throughout the healing period. Table 4 gives descriptive statistics for the median of epithelial thickness at different healing periods for both experimental and control groups. The results indicate that there were no notable variations between the groups on day 3. However, on day 7, the squalane oil group exhibited a considerably higher amount of collagen fiber compared to the control group, as shown in (Table 2).

[DOI: 10.22088/jbums.27.1.54]

Table 2. Descriptive statistics for epithelial thickness and collagen fiber intensity for each group during each healing period

Variables	Control group Mean±SD	Squalane oil group Mean±SD	Rosehip oil group Mean±SD	F test	p-value
	Epithelial thickness(µm)				
Day 3	114.89±33.63[a]	74.99±16.11[b]	82.35±26.41[c]	3.716	0.046
Day 7	244.72±25.02[a]	260.78± 36.42[a]	294.01±77.07[a]	1.262	0.308
	Collagen fiber intensity				
Day 3	90.693±3.302[a]	90.0805±4.373[a]	92.66± 5.297[a]	0.658	0.531
Day 7	102.97±4.94[a]	118.50±12.88[b]	117.156± 4.733[b]	4.360	0.030

Histological findings (H&E stain and Masson's Trichrome chemical stain):

Three-day duration: The histological images of the control group indicate the presence of granulation tissue, inflammatory cells (IC), and blood vessels (BV) surrounding the wound defect. The histological analysis of the experimental groups reveals the presence of a new epithelial layer (NE), keratinocyte migration (K), and inflammatory cells (IC) in granulation tissue, including new blood vessels (BV) and hair follicles (HF) as presented in (Figure 1A). The Masson's Trichrome stain of the control group reveals minimal new collagen synthesis at the wound's edge. However, in the experimental groups, the histochemical images clearly display prominent new collagen fibers, as depicted in (Figure 1B).

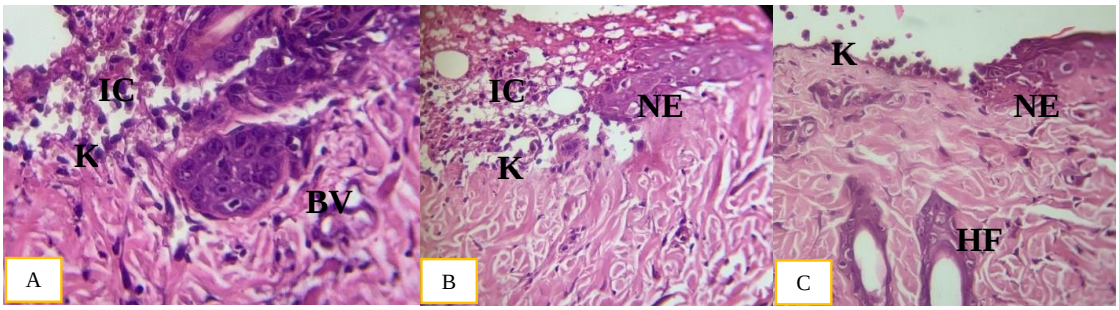

A

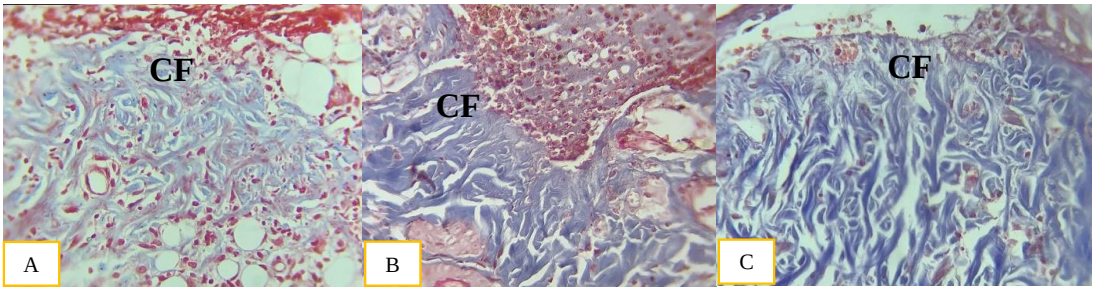

B

Figure 1. Histological (A) and histochemical (B) picture at the wound edge on day 3 of the A) control group, B) squalane oil group, C) rosehip oil group, H&E X40

[DOI: 10.22088/jbums.27.1.54]

Seven-day duration: By the seventh day, the histological analysis of the control group showed that the wound edges were not fully closed and there was granulation tissue with a significant presence of inflammatory cells, fibroblasts, and collagen fibers; in contrast, the experimental groups' histological pictures show some cases with complete closure of the epithelium (E) with obvious thickening of the epithelial cell layer. There are also numerous new blood vessels within the newly formed connective tissue and newly remodeled collagen fibers as presented in (Figure 2A). Masson's trichrome staining reveals the presence of newly formed collagen fibers (CF) that extend into the granulation tissue in both the control and experimental groups, as depicted in (Figure 2B).

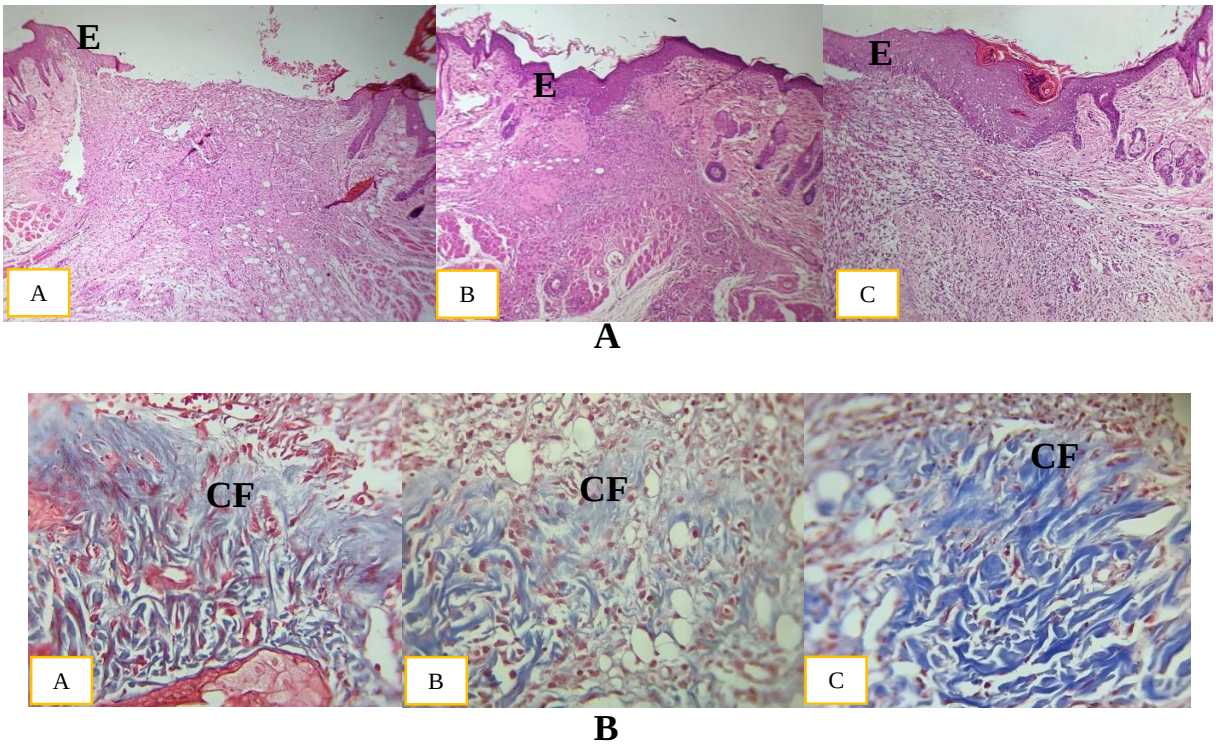

Figure 2. Histological (A) and histochemical (B) picture of the wound on day 7 that shows the new epithelium of the A) control group, B) squalane oil group, C) rosehip oil group, H&E X40 & MT stain X40

Discussion

The study demonstrated that the squalane oil group exhibited the highest level of wound contraction on day 7, whereas the rosehip oil group showed the lowest level of wound contraction. The anti-inflammatory properties of squalene oil may contribute to its ability to promote faster wound healing. This aligns with a study conducted by Sánchez-Quesada et al (18) which suggests that squalene oil can effectively regulate wound healing by modulating the innate immune response mediated by macrophages. However, the rosehip oil has a somewhat delayed action which agrees with a study conducted by da Costa Cavalcante et al (19) where they observed that the most evident effects of rosehip oil were mostly noticeable after the 14th day of the experiment.

[DOI: 10.22088/jbums.27.1.54]

The study findings indicate that the control group had higher mean values of inflammatory cell count compared to the experimental groups on day 3. However, on day 7, no significant difference was seen between the groups. The findings were comparable to a study conducted by Ulrikh et al, which aimed to assess the anti-inflammatory and wound-healing characteristics of squalene (20). They discovered that squalene regulates inflammation by modulating pro- and anti-inflammatory signals, including promoting wound healing and reducing edema. No significant difference was observed between the squalane oil group and the control group on day 7, possibly because the oil was consistently used at high quantities. This aligns with the same study conducted by Ulrikh et al (20) where they discovered that as the concentration of the substance reaches 10 -100 μM, its therapeutic properties are diminished and it promotes inflammation instead (at a concentration of 100 μM). The findings of the present study also indicated that rosehip oil effectively decreases the number of inflammatory cells on day 3 in comparison to the control group. The study yielded similar findings to a study that investigated the impact of rosehip oil on the healing of excisional wounds. It was observed that on the second day, the control group exhibited a higher concentration of inflammatory cells infiltrating the wounds compared to the group treated with rosehip oil (21).

The results of the present investigation revealed a marginal elevation in the thickness of the epithelium in the control group compared to the experimental groups on day 3. While on day 7, the squalane oil and rosehip oil groups showed a small increase in epithelial thickness compared to the control group. The findings were supported by a study conducted to assess the impact of a squalene-loaded topical agar-based emulgel scaffold on wound healing in a full-thickness burn model. On the 12th day of the study, it was confirmed that the tissue sections treated with the squalene-loaded emulgel scaffold showed outstanding reepithelization activity (22). In relation to rosehip oil, the findings align with a study conducted to enhance the healing of surgical wounds using rosehip oil. The study revealed that wounds treated with rosehip oil healed quickly and the time taken for epithelialization, the process of forming new skin, was reduced compared to the control group (21).

The findings indicated that there was no discernible disparity in collagen fiber intensity on day 3 between the group treated with squalane oil, the group treated with rosehip, and the control group. However, on day 7, both the squalane oil group and the rosehip group exhibited a notable rise in collagen fiber intensity compared to the control group. This is consistent with a study conducted by Sánchez-Quesada et al, in which they showed that Squalene promotes the remodeling process and triggers signals for tissue healing, along with chemicals that attract neutrophils (18). The same goes for the results of rosehip which coincide with a study done by Lei et al, where they found that after seven days, wounds treated with rosehip exhibited significant growth of fibroblasts and collagen formation. In contrast, the untreated control group had only a few blood vessels, and inflammatory cells were still present in high numbers (21).

The study's findings demonstrated that the use of squalane oil resulted in enhanced wound contraction, decreased presence of inflammatory cells, and increased production of collagen. Nevertheless, the thickness of the epithelial layer was similar to that of the control group.

Rosehip oil demonstrated a decrease in inflammatory cells and an increase in collagen fibers when compared to the control group. However, the wound required additional time for the process of wound contraction, and the thickness of the epithelial layer was similar to that of the control group.

[DOI: 10.22088/jbums.27.1.54]

Acknowledgment

The specialized veterinary doctors at the cancer research center are acknowledged for their support, and Dr. Noor Sami for his effort in the statistical analysis.

References

1.Nanci A, Wazen RM. Repair and regeneration of oral tissue. In: Nanci A, editors. Ten Cate's Oral Histology: Development, Structure, and Function, 9th ed. Elsevier; 2017. p. 244-320.

2.Khan MSA, Ahmad I. Herbal medicine: current trends and future prospects. In: Khan MSA, Ahmad I, Chattopadhyay D, editors. New look to phytomedicine: Advancements in Herbal Products as Novel Drug Leads. Elsevier; 2019. p. 3-13.

3.Mori HM, Kawanami H, Kawahata H, Aoki M. Wound healing potential of lavender oil by acceleration of granulation and wound contraction through induction of TGF-β in a rat model. BMC Complement Altern Med. 2016;16:144.

4.Micera M, Botto A, Geddo F, Antoniotti S, Bertea CM, Levi R, et al. Squalene: More than a Step toward Sterols. Antioxidants (Basel). 2020;9(8):688.

5.Senbagalakshmi P, Muthukrishnan S, Jebasingh T, Kumar TS, Rao M, Kumar TS, et al. Squalene, biosynthesis and its role in production of bioactive compounds, a proper scientific challenge—a review. J Emerg Technol Innov Res. 2019;6:505-26.

6.Oliveira ALS, Valente D, Moreira HR, Pintado M, Costa P. Effect of squalane-based emulsion on polyphenols skin penetration: Ex vivo skin study. Colloids Surf B Biointerfaces. 2022;218:112779.

7.Belkhelladi M, Bougrine A. Rosehip extract and wound healing: A review. J Cosmet Dermatol. 2024;23(1):62-7.

8.Kiralan M, Yildirim G. Rosehip (Rosa canina L.) oil. In: Ramadan MF, editors. Fruit Oils: Chemistry and Functionality. Springer; 2019. p. 803-14.

9.Ali SH, Ghani BA, Kamil NB. In Vivo Histological Assessment of Local Application of Fenugreek Seed Oil on Cutaneous Wound Healing. Medico-legal Update. 2022;22(2):167-75.

10.Suvarna KS, Layton C, Bancroft JD. Bancroft's theory and practice of histological techniques, 8th ed. Elsevier; 2018. p. 69-186.

11.Hadi RJ, Kamil NB, AL-Ghaban NMH, Ghani BA, Izzat AW. Vascular Endothelial Growth Factor Expression in Pulp Regeneration Treated By Hyaluronic Acid Gel in Rabbits. Iraqi J Pharm Sci. 2023;32(3):156-64.

12.Al Zamely ZR, Kadhim EF. Evaluation of the effect of local exogenous application of osteopontin on wound healing in rats. J Bagh Coll Dent. 2018;30(2):23-8.

13.Holzer-Geissler JCJ, Schwingenschuh S, Zacharias M, Einsiedler J, Kainz S, Reisenegger P, et al. The Impact of Prolonged Inflammation on Wound Healing. Biomedicines. 2022;10(4):856.

14.Kamil NB, Al-Ghaban NM. Evaluation the effects of local exogenous application of a mixture of Myrrh and Sage oil on incisional wound healing on the skin of the face (Histological, Histochemical and Histomorphpmetrical study in rabbits). J Pharm Sci Res. 2018;10:1030-5.

15.Mukhopadhyay A, Rajput M, Barui A, Chatterjee SS, Pal NK, Chatterjee J, et al. Dual cross-linked honey coupled 3D antimicrobial alginate hydrogels for cutaneous wound healing. Mater Sci Eng C Mater Biol Appl. 2020;116:111218.

16.Kamil NB, Al-Ghaban NM. Evaluation of effect of local exogenous application of Myrrh oil on healing of wound incisions of facial skin (Histochemical, Histological and Histomorphometrical study in rabbits). J Bagh Coll Dent. 2019;31(4):71-8.

17.Al-Zubaidy EY, Ghani BA, Ibrahim NR. Local application of Opuntia ficus-indica / Punica granatum oils on cutaneous wound healing: a histochemical study. J Bagh Coll Dent. 2023;35(4):28-34.

18.Sánchez-Quesada C, López-Biedma A, Toledo E, Gaforio JJ. Squalene Stimulates a Key Innate Immune Cell to Foster Wound Healing and Tissue Repair. Evid Based Complement Alternat Med. 2018;2018:9473094.

[DOI: 10.22088/jbums.27.1.54]

19.da Costa Cavalcante LC, Pessôa TC, Júnior RF, Yasojima EY, Soares RH, Brito MV, et al. Healing incisional surgical wounds using Rose Hip oil in rats. Int Arch Med. 2017;10.
20.Ulrikh EV, Smolovskaya OV. Evaluation of anti-inflammatory and wound healing properties of Squalene: An important phytochemical component of amaranth oil. Int J Chem Biochem Sci. 2022;21:54-60.
21. Lei Z, Cao Z, Yang Z, Ao M, Jin W, Yu L. Rosehip Oil Promotes Excisional Wound Healing by Accelerating the Phenotypic Transition of Macrophages. Planta Med. 2019;85(7):563-9.
22.Shanmugarajan TS, Selvan NK, Uppuluri VNVA. Development and Characterization of Squalene-Loaded Topical Agar-Based Emulgel Scaffold: Wound Healing Potential in Full-Thickness Burn Model. Int J Low Extrem Wounds. 2021;20(4):364-73.

[DOI: 10.22088/jbums.27.1.54]