Journal of
Babol University of Medical Sciences
JBUMS
e-ISSN: 2251-7170 p-ISSN: 1561-4107

The Effects of Hypertensive Disorders on Syncytiotrophoblast Cells and Spiral Artery Remodeling in Pregnancy

T. H. Khudir (MD)[*1], R. H. Lateef (MD)[1], I. A. Salih (MD)[1]

1.College of Science for Women, University of Babylon, Babylon, Iraq.

***Corresponding Author: T. H. Khudir (MD)**
Address: College of Science for Women, University of Babylon, Babylon, Iraq.
Tel: +964 (780) 3678193. **E-mail:** haliru.aa@gmail.com

Article Type
Research Paper

Received:
Apr 6th 2024
Revised:
Jun 15th 2024
Accepted:
Jul 7th 2024

ABSTRACT

Background and Objective: The major effect of the placenta is caused by the change of angiogenic factors in hypertensive disorders, which leads to chronic hypoxic changes in the placenta. The main objective of this research is to investigate the effect of blood pressure on the placenta and fetus during pregnancy and to identify its causes and complications.

Methods: This cross-sectional study included 60 women with hypertension disorder and 60 normal pregnant women from the AL-Imam AL-Sadiq hospital, aged fifteen and older. Maternal, fetal, and delivery characteristics were extracted through the questionnaire. The main comparison of "maternal and fetal outcomes" was determined among patients with hypertensive disorders. Normal groups were used to determine the levels of PGF, estrogen and progesterone hormones in serum. Placenta biopsy was obtained for histopathological examination.

Findings: The results of the study showed an increase in preterm delivery, low Apgar score, low birth weight and low placental weight in hypertensive groups. The findings of electron microscope examination (SEM) were related to the severity of hypertensive disorders such as vasculopathy, diffuse placental thrombosis, infarction, calcification, vasculosyncytial membrane thickness, and dysfunction of syncytiotrophoblast cells ($p<0.05$). In primigravid women, preeclampsia was observed in 17 people (85%) and in multigravida, it was observed in 3 people (15%) ($p<0.05$). The presence of two or more obstetric risks increased premature delivery by 7 people (35%), 8 people (40%) and 1 person (5%) in preeclampsia, chronic hypertension and gestational hypertension groups, respectively.

Conclusion: The results of the study showed that blood pressure can directly affect the placenta and fetus and the occurrence of placental disorders and increase in premature delivery.

Keywords: *Pregnancy, Gestational Hypertensive Disorders, Syncytiotrophoblast Cells.*

Cite this article: Khudir TH, Lateef RH, Salih IA. The Effects of Hypertensive Disorders on Syncytiotrophoblast Cells and Spiral Artery Remodeling in Pregnancy. *Journal of Babol University of Medical Sciences*. 2025; 27: e8.

[DOI: 10.22088/jbums.27.1.8]

Copyright © 2024 Babol University of Medical Sciences. Published by Babol University of Medical Sciences. This work is licensed under a Creative Commons Attribution-NonCommercial 4.0 International license (https://creativecommons.org/licenses/by-nc/4.0/). Noncommercial uses of the work are permitted, provided the original work is properly cited.

Introduction

There are four major categories of the hypertensive disorders during pregnancy comprising a spectrum as follows: 1) gestational hypertension in which women experience a rise in blood pressure during the second half of pregnancy, 2) pre-eclampsia caused by hypertension with proteinuria, 3) chronic hypertension which means "increase in blood pressure prior to pregnancy or during the time before twentieth week of pregnancy", 4) pre-eclampsia superimposed “on chronic hypertension” (1). The surface interface between fetus and mother is formed by fetal syncytiotrophoblasts. These cells are complicated in exchange of hormone production (2). Progesterone and estrogens modulate the synthesis and release of angiogenic factors by syncytiotrophoblast cells (3, 4).

Placental growth factor PGF is a member of the vascular endothelial growth factor (VEGF) family and is predominantly presented in the placenta. PlGF-1 and PlGF-2 are the most abundant forms. PE is related with a chronic maternal inflammatory form, and PlGF may suggest new specific indicative signs for control of pathological pregnancies (5, 6). The main objective of this research is to investigate the effect of blood pressure on the placenta and fetus during pregnancy and to identify its causes and complications.

Methods

This cross-sectional case-control study was conducted in Imam Sadiq Hospital from December 2023 to January 2024. The research was done under committee consideration of Babylon University with ethical code of IRQUB-2023-311. The ages under study where fifteen years and older. The samples included 60 women diagnosed with hypertension disorder (preeclampsia, chronic and gestational hypertension) and 60 women as control, and all agreed to participate in the research and a verbal consent were taken from pregnant women. Inclusion criteria for study group included pregnant women with chronic hypertension, gestational hypertension and preeclampsia. Exclusion criteria were pregnant women with any other disease. Maternal, fetal, and delivery characteristics were extracted using a questionnaire.

Soon after delivery, the placenta was removed, cleaned, and dried, and the weight (g) was registered. Biopsy from placenta included two sections from central and peripheral areas, which was kept for fixation in formalin for 24 hours and then examined using a light microscope and scanning electron microscopic (SEM). After fixation, all slides stained with H&E were subjected to histopathological examination; villous vascularity, syncytial knots, per villous fibrin deposition, infarction (coagulative necrosis), calcification, and villous stromal fibrosis were assessed. Hormonal examination (serum levels of PGF, estradiol and progesterone) for all cases of study group and control group was done on collected blood samples before delivery. For this purpose, 5 ml venous blood was collected from subjects and put in Eppendorf tube and under deep freeze and then hormonal immunoassay was done using MAGLUMI 600 Analyzer. 2×2 cm tissue samples were used for scanning electron microscope (SEM) examination.

Results

The details are displayed in Table 1. During the study period, 60 females were diagnosed with hypertensive disorders. These hypertensive disorders were divided into preeclampsia (n=20), chronic hypertension (n=20) and gestational hypertension (n=20) in the present study. 23 (38.3%) cases in control group were 20-25 years old, 10 (50%) cases in preeclampsia group were 31-35 years old, 11 (55%) cases in chronic hypertension group were 36-40 years old and 13 (65%) cases in gestational hypertension group

[DOI: 10.22088/jbums.27.1.8]

were 36-40 years old. Body mass index (kg/m2) was 30.31±1.24; which increased in chronic hypertensive women more than other groups. The percentage of parity primigravida of preeclampsia was 17 (85%); a more frequent incidence than other groups, while multigravida of preeclampsia was 3 (15%); less frequent incidence than the hypertension disorder groups.

Table 2 shows that the control group contains the highest mean placental weight (531±15.1) compared to the hypertension disorder (HD) group, (358±36.54, 388±30.51, 499±11.5), respectively. These findings are statistically significant. The mean birth weight in the control group was 3202±132 (g), whereas low-birth weight was 1875.36±675.19, 1623±121.1, 2016.69±531.35 (g) in PIH group, respectively. These findings were statistically significant. The presence of two or more obstetric risks increased the frequency of preterm delivery in the preeclampsia, chronic hypertension and gestational hypertension groups in this study by 7 (35%), 8 (40%) and 1 (5%), respectively. The severity of hypertension increased as it progressed. Apgar score in control group was 8.6±1.54, which decreases as the severity of hypertension progresses; 6.3±2.5, 6.3±4.2 and 6.4±1.1. Also, cesarean section increased mostly in preeclampsia group according to the risk factors. Gestational age in normal groups was 37.79±2.05, whereas in PIH group was 34.16±2.21, 34.99±3.77, 34.02±1.11 respectively.

Table 1. Maternal variables in both hypertension disorders and control groups

Maternal variable	Control (n=60) Number(%)	Preeclampsia (n=20) Number(%)	Chronic hypertension (n=20) Number(%)	Gestational hypertension (n=20) Number(%)	p-value
Maternal age years					
15-20	12(20)				
20-25	23(38.3)	3(15)	3(15)	3(15)	
26-30	12(20)	5(25)	2(10)	13(65)	
31-35	6(10)	10(50)	4(20)	3(15)	
36-40	7(11.6)	2(10)	11(55)	1(5)	
Body Mass Index (kg/m2) (Mean±SD)	23.2±3.01	29.1±1.52	30.31±1.24	24.5±1.99	<0.05
Parity					
Primigravida	10(16.6)	17(85)	15(75)	16(80)	
Multigravida	50(83.3)	3(15)	5(25)	4(20)	

Table 2. Fetal outcome in relation to study groups*

Fetal variable	Normal Mean±SD	Preeclampsia Mean±SD	Chronic hypertension Mean±SD	Gestational hypertension Mean±SD	p-value
Placental weight (gm)	531±15.1	358±36.54	388±30.51	499±11.5	
Birth Weight (g)	3202±132	1875.36±675.19	1623±121.1	2016.69±531.35	
Preterm birth, number(%)	Nill	7(35)	8(40)	1(5)	
Apgar score	8.6±1.54	6.3±2.5	6.3±4.2	6.4±1.1	
Root of delivery					
Spontaneous vaginal delivery	19	2	3	5	
Cesarean	1	18	17	15	
Gestational age	37.79±2.05	34.16±2.21	34.99±3.77	34.02±1.11	>0.05

*Hormonal examination

[DOI: 10.22088/jbums.27.1.8]

As shown in Figure 1, the mean values of PGF and LSD in preeclampsia patients (97.98±19.35) show significantly higher levels in comparison with controls (3.87). Regarding progesterone levels, the results of Table 2 show low levels in patients in comparison with control, indicating no significant differences in preeclampsia and LSD values (21.6). Estrogen levels are lower in patients with preeclampsia, followed by chronic patients in comparison with controls and LSD values (6.43). These results may indicate that pregnancy leads to different variations in hormones which causes more hypertension disorders.

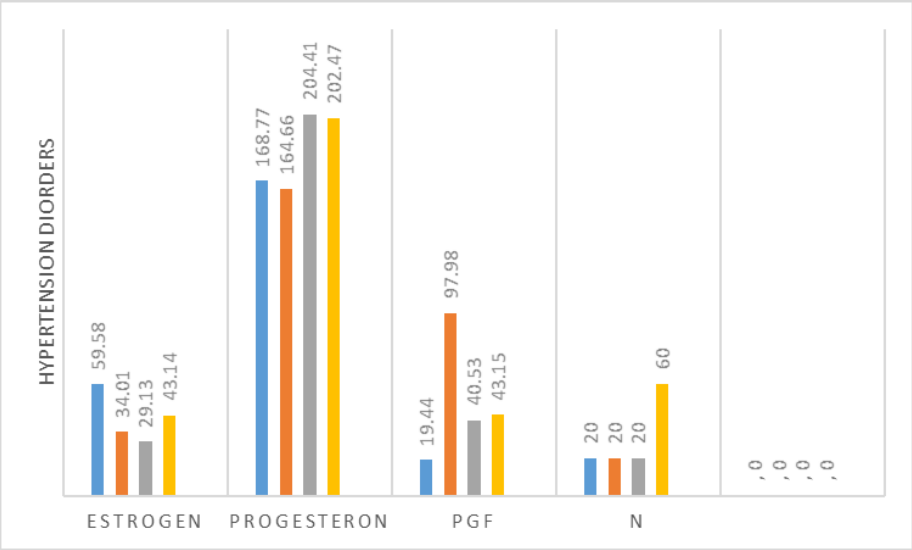

Figure 1. Levels of placental growth factor (PGF), estradiol and progesterone among pregnant women with hypertension disorder compared to uncomplicated pregnancies

Light microscopy and scanning electron microscope (SEM) examination on surface morphology of placental villi: The results of each figure is as follows: Figure 2 shows higher incidence of diffuse calcifications, and Hofbauer cells induce fibrotic responses within the villi during chronic inflammation, and edematous intervillous spaces (10x) H&E. Figure 2 (B and C) with different images of scanning electron microscope (SEM): Figure 2 (B) displays distribution of calcification areas on the surface of syncytiotrophoblast microvesicles (STBM) of villi, Figure 2 (C) revealed syncytiotrophoblast disruption and an extensive fibrillary meshwork of microvilli for calcification repairs on the surface of syncytiotrophoblast microvesicles (STBM) of villi in chronic hypertension.



Figure 2. A (a): Diffuse calcifications with black stain, (b): Hofbauer cells in the stroma of villi, (c): Edematous intervillous spaces (10x) H&E

[DOI: 10.22088/jbums.27.1.8]

Figure 3 shows that infarction (coagulative necrosis) of lumen is obliterated by partially calcified thrombus, per villous fibrin deposition and thickness of syncytiotrophoblast vascular membrane barrier, and increased syncytial note (10x) H&E. Figure 3 B (SEM) revealed lower and shorter arborization of villi. Figure 3 C (SEM) revealed that trophoblastic surface has a mosaic appearance of villi (Preeclampsia). Figure 4 depicts the Avascular villi, fibrosis of stroma increase in villi (10x) H&E., and scanning electron microscope (SEM). Figure 4 B shows (SEM) microvilli atypical, and Figure 4 C shows (SEM) areas without microvillous (Gestational hypertension).



Figure 3. (a): Infarction (coagulative necrosis) of the vessel lumen is obliterated by partially thrombus, (b): perivillous fibrin deposition and thickness of syncytiotrophoblast vascular membrane barrier (c) increased syncytial note



Figure 4. A: Avascular villi, fibrosis of stroma, thickening of vasculosyncytial membrane (perilous fibrinoid degeneration), slender villi with reduced branching (Accelerated villous maturation) (10x) H&E. B: SEM revealed atypical villi, and areas lacking Microvilli, C: SEM revealed no microvillous areas (Gestational hypertension)

Discussion

The hypertensive disorders during pregnancy lead to histomorphological changes that have severe fetal results. Thus, early search about mechanism of placental dysfunction informs us about the reasons of toxemic pregnancies which enables the obstetrician to fix any consequent complication (7). Numerous etiological risk factors exist for hypertension disorders in pregnancy (primigravida, BMI≥35, age over 40, previous history of preeclampsia, 10 years or more since last pregnancy, family history: 3-4-fold increase risk, pre-existing hypertension or renal disease (8). Furthermore, a study by Nimisha et al. in

[DOI: 10.22088/jbums.27.1.8]

2023 show that pregnancy with chronic hypertension increased the risk for preeclampsia, preterm delivery, cesarean section, and low birthweight (<2500 g) (7). Camen et al. (9) mentioned that the mean placental weight increases directly relative to the placental vascular density. They also found a statistically significant difference in increased maternal weight, advanced maternal age and younger age associated with preterm birth.

The infarction presence and basement membrane thickening tend to facilitate vascular remodeling to make up for low oxygen supply from maternal to fetal circulation, maybe due to the deposition of immunoglobulin caused by pregnancy-induced hypertension (10, 11). Pre-eclampsia decreases blood supply to the placenta, which result in secretion of placental toxic factors after endothelial dysfunction, resulting in general "vasoconstriction and thrombosis", which raises the level of liver enzymes disorders in severe morbidity of preeclampsia and eclampsia (12). Association between gestational hypertension and preeclampsia results in the degradation of collagen and the ruptures of membrane (13).

The hormonal changes of pregnancy require significant adaptations as short upsurge of estrogen, and progesterone, which result in systemic vasodilation that causes increase in plasma volume during early stages of pregnancy (14). In healthy pregnancies, PlGF increases until 32 weeks and then declines; in preeclampsia, however, there is a marked reduction of PIGF in venous levels as early as 13–16 weeks, occurring before the beginning of other clinical symptoms of hypertension (15).

Cohen et al. (15) mentioned that the rise of blood pressure, which leads to hypoxia and hyperplasia of syncytiotrophoblast cells, causes an increased production hormone of placenta. In a study by Albonici et al. may coincide with what we mentioned above; the reason of elevated peak secretion of PGF hormone in chronic hypertension group in our study was more than peak secretion of control group, as shown in Figure 1. The results of PGF show that chronic patients have higher level than gestational and preeclampsia in comparison with control at a significant variance and the LSD value (3.87), because main source of PGF during pregnancy is the placental syncytiotrophoblast cells. PGF is a member of VEGF family. The immunomodulatory effects of PlGF during pregnancy show that immune cells efficiently provide the early actions of placental progress (5).

Syncytiotrophoblast cells produce progesterone and estrogens hormones, influencing the response of the body both in the acute and late stages of injury. Progesterone and estrogens reduce the spiral uterine arteries resistance and modulate the creation and release of angiogenic factors such as PGF by syncytiotrophoblast cells. Progesterone can regulate the inflammatory reactions, contribute to pre-eclampsia and preterm labor (16). Comparing serum data over third trimester indicates that the uncomplicated pregnancy cases had a greater level of serum E2 but in PE complicated pregnancy group, a decreased level of E2 was found, but the two groups had similar levels of P4, which may be similar to the results in our study (17).

Indeed, uteroplacental malperfusion and hypoxia such as PE coincide with aggregates of syncytial nuclei. It's worth indicating that syncytiotrophoblast mainly serves as protective barrier against harmful effects to the fetus, which is exactly a fetal-maternal exchange portal for nutrients and waste products (18).

In our study, SEM of villous changes were found in the placentae of women with hypertension disorders which may adversely affect placental function. Figure 2 displays diffuse calcifications of the trophoblastic villi surface, which coincides with the study by Al-Zuhair et al. (19) who said that based on SEM, calcium depositions could only be seen at higher magnifications in the forms of flecks. The placental calcification is a pathological feature associated to both mother and fetus (20). Hofbauer cells play roles in angiogenesis in extracellular matrix remodeling through ingesting collagen and modulate trophoblast via regulating syncytial fusion (21).

[DOI: 10.22088/jbums.27.1.8]

A study by Dash et al. (22) showed that premature placental calcification is associated with low placental weight, low birth weight and APGAR scores of hypertensive disorder pregnancies. Clinicians should be aware of documenting placental grading of Premature Placental Calcification (PPC) during ultrasonography at 28 to 36 weeks (23).

A study by Miura et al. (24) pointed that the placental barrier syncytium cells develop many microvilli exposed to the maternal blood in the intervillous space, because it is placed in the wide cavity between the villi, where the mother's blood flow rate decreases significantly, and through the results obtained in our study, this may give the surface of the villi a mosaic appearance due to reduced maternal blood, so the boundaries of the cavity that surround the villi appear and then become clear to give a mosaic appearance as a result of pressure (25), as was shown in our study.

In Figure 4, SEM reveals alterations of syncytiotrophoblast such as a total absence of their covering microvilli just like what was found in a study by Castejón Sandoval et al. (26). A distorted villi from HD group was found to have very short arborization and atypical microvilli by using SEM; these changes are linked to the hypoxia-reoxygenation injury leading to apoptosis. Figure 2 C (SEM) revealed the impact of the syncytiotrophoblast may be from the loss microvilli, disruption of syncytiotrophoblast, and an extensive fibrillar meshwork that were often found on the surface of the syncytium in patients with chronic hypertension. The preterm labor is related to the loss of microvilli which may signify a possible reduced placental function (2). The results of Figure 4 C (SEM) coincide with Cerdeira et al. (27) who observed small terminal branches of stem villi with short ramifications by SEM. Usage sFlt-1/PlGF ratio, positive predictive value of PPV (95% CI, 27.6-53.5%) significantly enhanced clinical accuracy to diagnosis PE.

Histopathological findings that increase the risk of preeclampsia include: (i) syncytial knots, (ii) fibrin deposits, (iii) atherosclerosis arterial wall, (iv) accelerated villous maturation and calcifications due to the hypoxic mechanisms and ischemia. These findings indicate that pregnancy blood pressure can have consequences such as intrauterine growth disorder, pre-eclampsia, fetal death, placental abruption and dangerous maternal complications caused by vascular spasm and ischemia. In this regard, it is suggested that health centers reduce possible complications by conducting timely visits of patients and follow-up of high-risk patients.

Acknowledgment

We would like to thank the University of Babylon/ Collage of Science for women and also the officials and personnel and participants for their sincere cooperation.

[DOI: 10.22088/jbums.27.1.8]

References

1.Silasi M, Cohen B, Karumanchi SA, Rana S. Abnormal placentation, angiogenic factors, and the pathogenesis of preeclampsia. Obstet Gynecol Clin North Am. 2010;37(2):239-53.

2.Dixit S, Goyal S, Singh A, Dhingra A, Grover S, Gupta P. Evaluation of effect of various drinks on tooth surface morphology under scanning electron microscope. J Conserv Dent Endod. 2024;27(8):811-6.

3.Dadkhah N, Yazdani Sh, Manouchehri AA, Sahranavard Sh. An Investigation of the Causes and Methods of Termination of Pregnancy in Medical Abortions Referred from Forensic Medicine in Babol Hospitals within a Four-Year Period. J Babol Univ Med Sci. 2024;26:e32. [In Persian]

4.Berkane N, Liere P, Oudinet JP, Hertig A, Lefèvre G, Pluchino N, et al. From Pregnancy to Preeclampsia: A Key Role for Estrogens. Endocr Rev. 2017;38(2):123-44.

5.Albonici L, Benvenuto M, Focaccetti C, Cifaldi L, Miele MT, Limana F, et al. PlGF Immunological Impact during Pregnancy. Int J Mol Sci. 2020;21(22):8714.

6.Shahbazian N, Mohammadian F, Barati M, Saadati N. An Investigation of the Placental Implantation Location in Cesarean Scar Pregnancy. J Babol Univ Med Sci. 2023;25(1):434-41. [In Persian]

7.Sharma N, Kahlon N, Singh M, Jindal A, Pujani M, Das A. Histopathological Changes of Placenta in Maternal Hypertensive Disorders and its Association with Birth Weight: A Case-control Study. J Clin Diagn Res. 2023;17(3):EC22-5.

8.Wenas AF, Al-Massawi HY. Association between gestational hypertension and preeclampsia with spontaneous prelabor rupture of membrane. Med J Babylon. 2022;19(2):281-7.

9.Camen IV, Istrate-Ofițeru AM, Novac LV, Manolea MM, Dijmărescu AL, Neamțu SD, et al. Analysis of the relationship between placental histopathological aspects of preterm and term birth. Rom J Morphol Embryol. 2022;63(2):357-67.

10.Al-Rubai AJ, Ibraheem MM, Hameed AF, Noel KI, Eleiwi SA. Comparison of placental expression of basic fibroblast growth factor and insulin-like growth factor-1 in placentae of normal, pregnancy-induced hypertension, and preeclamptic pregnancies in Iraqi mothers. Med J Babylon 2023;20(4):681-8.

11.Obiri D, Erskine IJ, Oduro D, Kusi KA, Amponsah J, Gyan BA, et al. Histopathological lesions and exposure to Plasmodium falciparum infections in the placenta increases the risk of preeclampsia among pregnant women. Sci Rep. 2020;10(1):8280.

12.Sabeen F. Histopathological Study of Placentas of Hypertensive Disorders. J Clin Sci Trans Med. 2023;5(1):000119.

13.Ngene NC, Moodley J. Physiology of blood pressure relevant to managing hypertension in pregnancy. J Matern Fetal Neonatal Med. 2019;32(8):1368-77.

14.Benschop L, Schalekamp-Timmermans S, Broere-Brown ZA, Roeters van Lennep JE, Jaddoe VWV, Roos-Hesselink JW, et al. Placental Growth Factor as an Indicator of Maternal Cardiovascular Risk after Pregnancy. Circulation. 2019;139(14):1698-709.

15.Cohen Y, Gutvirtz G, Avnon T, Sheiner E. Chronic Hypertension in Pregnancy and Placenta-Mediated Complications Regardless of Preeclampsia. J Clin Med. 2024;13(4):1111.

16.Wan J, Hu Z, Zeng K, Yin Y, Zhao M, Chen M, et al. The reduction in circulating levels of estrogen and progesterone in women with preeclampsia. Pregnancy Hypertens. 2018;11:18-25.

17.Lan KC, Lai YJ, Cheng HH, Tsai NC, Su YT, Tsai CC, et al. Levels of sex steroid hormones and their receptors in women with preeclampsia. Reprod Biol Endocrinol. 2020;18(1):12.

[DOI: 10.22088/jbums.27.1.8]

18.Falco ML, Sivanathan J, Laoreti A, Thilaganathan B, Khalil A. Placental histopathology associated with pre-eclampsia: systematic review and meta-analysis. Ultrasound Obstet Gynecol. 2017;50(3):295-301.
19.Al-Zuhair AG, Ibrahim ME, Mughal S. Calcium deposition on the maternal surface of the human placenta: a scanning electron microscopic study. Arch Gynecol. 1984;234(3):167-72.
20.Reyes L, Golos TG. Hofbauer cells: their role in healthy and complicated pregnancy. Front Immunol. 2018;9:2628.
21.Gardiner C, Tannetta DS, Simms CA, Harrison P, Redman CW, Sargent IL. Syncytiotrophoblast microvesicles released from pre-eclampsia placentae exhibit increased tissue factor activity. PLoS One. 2011;6(10):e26313.
22.Dash S, Das B, Panda SR, Rajguru M, Jena P, Mishra A, et al. Perinatal Outcomes in Premature Placental Calcification and the Association of a Color Doppler Study: Report from a Tertiary Care Hospital in Eastern India. Clin Pract. 2021;11(4):841-9.
23.Cockell AP, Learmont JG, Smárason AK, Redman CW, Sargent IL, Poston L. Human placental syncytiotrophoblast microvillous membranes impair maternal vascular endothelial function. Br J Obstet Gynaecol. 1997;104(2):235-40.
24.Miura S, Sato K, Kato-Negishi M, Teshima T, Takeuchi S. Fluid shear triggers microvilli formation via mechanosensitive activation of TRPV6. Nat Commun. 2015;6:8871.
25.Atwa KA, Farghaly LM. Light and electron microscopic study of placental tissue in women suffering from severe preeclampsia. Egypt J Histol. 2011;34(4):650-61.
26.Castejón Sandoval OC, López González AJ. A light and scanning electron microscopy study of placental villi associated with obesity and hypertensión. Electron J Biomed. 2013;2:30.
27.Cerdeira AS, O'Sullivan J, Ohuma EO, Harrington D, Szafranski P, Black R, et al. Randomized Interventional Study on Prediction of Preeclampsia/Eclampsia in Women With Suspected Preeclampsia: INSPIRE. Hypertension. 2019;74(4):983-90.

[DOI: 10.22088/jbums.27.1.8]