Journal of
Babol University of Medical Sciences
JBUMS
e-ISSN: 2251-7170 p-ISSN: 1561-4107

Comparison of Opuntia Ficus-Indica and Punica Granatum Oil in Healing Skin Wounds

E. Y. Al-Zubaidy (DDS, MS)[1], B. Abdal Ghani (PhD)[*2]

1.College of Dentistry, University of Baghdad, Baghdad, Iraq.

2.Department of Oral Diagnosis, College of Dentistry, University of Baghdad, Baghdad, Iraq.

•**Corresponding Author: B. Abdal Ghani (PhD)**

Address: Department of Oral Diagnosis, College of Dentistry, University of Baghdad, Baghdad, Iraq.

Tel: +964 (771) 4225150. **E-mail:** golden87rose@yahoo.com

Article Type

Research Paper

Received:
Jun 23rd 2023
Revised:
Aug 26th 2023
Accepted:
Feb 3rd 2024

ABSTRACT

Background and Objective: Chemical drugs are effective for wound healing, but herbal drugs with relative safety mainly reduce the adverse effects of chemical drugs in wound healing. The use of Opuntia ficus-indica oil and punica granatum oil as a natural remedy is prevalent due to the perceived beneficial properties. The aim of the present study is to compare the impact of "opuntia oil" and "punica oil" separately and in combination on skin wound healing.

Methods: This triple-blind clinical trial included 32 male adult New Zealand rabbits with a mean weight ranging from 1.5 to 2.0 Kg. Four circular standardized wounds were created on the dorsal region of each rabbit using a sterile biopsy punch with a diameter of 8 mm. The wounds intentionally left uncovered and the wound on the upper right side was not treated. The wound located on the upper left side was subjected to treatment with Opuntia ficus-indica oil. Punica granatum oil was used to treat a wound located on the lower right side. The lower-left-side wound was ultimately treated with a mixture of opuntia ficus-indica oil and punica granatum oil. The three experimental groups received daily treatment including topical application of 10 µl of opuntia ficus-indica oil, punica granatum oil, or a combination of these two oils, and wound healing in the groups was compared on days 1, 3, 7, and 14.

Findings: Wound healing in experimental groups showed a significant difference compared to the control group. The combination group exhibited the greatest mean value of wound contraction at day 14, reaching 84.6% at the experimental site. The analysis of inflammatory cell count revealed that the experimental groups treated with punica granatum oil exhibited the greatest mean values, reaching 68% on day one. Additionally, the mean values of epithelial thickness rose with time in all groups, with the combination group displaying a mean value of 38.5±3.5 um on day 14. There were notable differences between the control and experimental groups throughout all healing phases.

Conclusion: The results of the study showed that both opuntia ficus-indica oil and punica granatum oil are effective in wound healing compared to the control groups.

Keywords: *Opuntia Ficus-Indica Oil, Punica Granatum Oil, Wound-Healing, Natural Products Effectiveness.*

Cite this article: Al-Zubaidy EY, Abdal Ghani B. Comparison of Opuntia Ficus-Indica and Punica Granatum Oil in Healing Skin Wounds. *Journal of Babol University of Medical Sciences*. 2025; 27: e4.

[DOI: 10.22088/jbums.27.1.4]

Copyright © 2024 Babol University of Medical Sciences. Published by Babol University of Medical Sciences. This work is licensed under a Creative Commons Attribution-NonCommercial 4.0 International license (https://creativecommons.org/licenses/by-nc/4.0/). Noncommercial uses of the work are permitted, provided the original work is properly cited.

Introduction

The capability for wound healing in the human body is contingent upon several factors, including the individual's overall health, the extent of tissue injury, and the proliferative ability of cells (1). Wounds break the integrity of the skin, leading to alterations in the surrounding anatomical structures and functions. The intricate and dynamic process of wound healing is influenced by several factors, including the host's general health, the immune system, and the local environment around the wound (2). The classification of wound healing is mostly based on the treatment modality and the specific characteristics of the lesion. Wound healing refers to the physiological process through which the skin undergoes repair and restoration following injury or harm inflicted upon it. The phases of wound healing are sometimes referred to as primary, secondary, and tertiary stages (3).

The successful regeneration of healthy and functioning skin poses a significant obstacle due to its complex multilayered structure and the coordinated arrangement of many cell types within the extracellular matrix. In light of recent advancements in wound care treatments, there is a continued interest in exploring alternative therapies derived from natural sources, including plant extracts, honey, and larvae (4). Opuntia ficus-indica (OFI), a member of the Cactaceae family, is traditionally employed for therapeutic purposes, particularly in the domain of wound healing. In the context of animal models, a number of extracts derived from different parts of the Opuntia ficus-indica (OFI) plant, such as stems and cladodes, have exhibited encouraging properties in promoting wound healing. The wound-healing properties of OFI are enhanced by its capacity to undergo self-emulsification into nano-droplets. The observed activity can be attributed, at least partially, to its anti-inflammatory, pro-collagen, and angiogenic properties (5).

Studies conducted over the past decade have demonstrated the therapeutic features of many components found in pomegranates, including antioxidants, anti-carcinogenic agents, antibacterial properties, and anti-inflammatory properties. The primary polyphenols with significant medicinal activity derived from pomegranates are ellagic acid, punicic acid, ellagitannins, anthocyanins and anthocyanidins, flavones, flavonoids, and estrogenic flavonols. Wound healing is a commonly seen biological process within the human body. Four meticulously prepared and accurate steps facilitate the accomplishment (6). The process of hemostasis, followed by the inflammatory phase, proliferative phase, and remodeling phase, was identified as a sequential series of events (7). In order to achieve good wound healing, it is imperative that all four phases take place in the appropriate sequence (8). The process of wound healing encompasses a series of intricate interactions between cells and their mediators, which play a crucial role in facilitating the repair of wounds. The primary aim of this study was to assess the efficacy of herbal medication in facilitating wound healing.

Methods

This study is a triple-blind randomized controlled trial. After being approved by the ethics committee for utilizing animals in research, as outlined by the College of Dentistry/University of Baghdad (Reference Number: 681 on 11/10/2022), it was performed on 32 adult male New Zealand rabbits, with an average weight ranging from 1.5 to 2 kg. Each rabbit's dorsum was subject to four circular full-thickness wounds, created using a sterile biopsy punch in a diameter of 8 mm. The rabbits were then randomly assigned into groups. The control group consisted of 32 wounds on each rabbit that were allowed to heal naturally. In each experimental group, 32 wounds on each rabbit were treated with opuntia ficus-indica oil (15 ml per dropper, manufactured in the United States), Punica Granatum seed oil (30 ml containing pure cold-pressed

[DOI: 10.22088/jbums.27.1.4]

seed extract, MAYAN'S SECRET, United States, batch number 1023820), and a combination of the two oils in a 1:1 ratio.

The animals were individually placed on a surgical bench and administered with a general anesthetic intramuscularly. The anesthesia solution consisted of 80% ketamine (at a dosage of 40 mg/kg) and 20% xylazine (at a dosage of 5 mg/kg).

The hair on the dorsal region was initially trimmed using a hair clipper, followed by the use of a hair removal lotion to eliminate any leftover hair. In order to disinfect the skin, a solution of 90% ethyl alcohol was employed for cleansing purposes. Four circular excisional incisions were created on the dorsal skin of each rabbit, 40mm apart from each other. This was achieved using a biopsy stapler punch with a diameter of 8mm. The local application of oil was perform using a micropipette. Specifically, a volume of 10µL of opuntia and pomegranate oil was applied to the upper left-side wound of rabbits, while the lower left-side wound received 10 µL of pomegranate oil. Additionally, the lower right-side wound was treated with 10µL of opuntia ficus oil. The upper right-side wound left untreated to allow for spontaneous healing. The process of scarification was performed on animals at certain intervals (1, 3, 7, and 14 days) to facilitate the healing process. Subsequently, samples were obtained to evaluate the extent of wound contraction. Additionally, histological and histomorphometric studies were conducted to assess the presence of inflammatory cells and measure the thickness of the epithelial layer.

The samples were immersed in a solution containing 10% newly prepared formalin for a duration of 24 hours. The technique of dehydrating biological samples is a crucial stage in the tissue processing procedure. The primary objective of the dehydration process is to extract water from biological specimens, facilitating their subsequent examination under a light microscope. Subsequently, each sample subjected to a 30-minute immersion in a container filled with xylene. Following this step, the treated tissue samples were immersed in molten paraffin wax. Once the paraffin wax has undergone solidification, the resulting block was prepared for the cutting process.

The present study used statistical analytic techniques to analyze the data. The comprehensive characterization of each variable was conduct using the Statistical Package for Social Sciences (SPSS) version 26. The sole information pertaining to the participants consisted of their respective serial numbers; while the acquired data was regularly organized on a daily basis. The data was represented using measures of central tendency (mean) and dispersion (standard deviation), as well as the range of values (minimum and maximum). The analysis of variance (ANOVA) test and the post hoc test, specifically the least significant difference (LSD) test, were employed to evaluate the distinctions between the independent groups under investigation. A significance threshold of 0.05 was used, indicating a confidence level of 95%, to determine statistical significance.

Results

Estimation of wound contraction: The results of the current investigation indicate that the observed rate of wound contraction exhibited a progressive rise throughout the course of the research, coinciding with decrease in wound size as depicted in table 1. The investigation involved monitoring the degree of wound contraction during the course of the healing process for each of the groups under study. The measurement of wound contraction was conducted in millimeters (mm). The control groups exhibited a minimum wound size value of 21.3% on day 1, whereas the combination group reached its maximum value of 84.6% on day 14. Noteworthy differences were seen between the experimental and control groups. According to ANOVA test, significant differences were observed between control and experimental groups in all healing periods ($p<0.01$) regarding wound contraction.

[DOI: 10.22088/jbums.27.1.4]

Table 1. Descriptive statistics of wound contraction in (mm) for all groups in each healing period

Days and Groups	Mean±SD	p-value	F test
DAY 1			
Control	6.3±1.6	0.049*	3.124
OFI	5.3±1.2		
PGS	5.2±1		
OFI+PGS	5.4±1		
DAY 3			
Control	6.1±1.4	0.022*	4.87
OFI	4.6±0.9		
PGS	5.1±1.1		
OFI+PGS	5.1±1.1		
DAY 7			
Control	5±1	0.045*	3.383
OFI	3.9±0.7		
PGS	4.4±0.7		
OFI+PGS	4.4±0.9		
DAY 14			
Control	3±1	0.013*	5.717
OFI	1.4±0.4		
PGS	2±0.5		
OFI+PGS	1.2±0.5		

***Significant result, ****high Significant result**

Inflammatory cell parameter: The mean values of inflammatory cell count were obtained during the healing periods for all groups under study. Table 2 presents the descriptive statistics for the inflammatory cell count data collected at various healing periods. The results indicate that the mean values were comparatively higher in the experimental groups as compared to the control groups on days 1 and 3. Specifically, the pomegranate group exhibited the highest mean value on day 1, while the opuntia group had the highest mean value on day 3. Conversely, on days 7 and 14, the control groups displayed higher mean values than the experimental groups. According to ANOVA test, highly significant differences were found between study groups at day 1 and significant differences were recorded at days 3 and 14 between the groups.

Epithelial thickness parameter: The findings indicated that the average values of epithelial thickness demonstrated a progressive rise over time across all groups under investigation. Table 3 presents the descriptive statistics for mean and standard deviation of the measured data at various healing periods for both the experimental and control groups in terms of epithelial thickness. Furthermore, it was observed that the measured thickness was consistently greater in the experimental groups compared to the control group. The combination groups exhibited the greatest values across various periods of study, with the highest value observed specifically on day 14. According to ANOVA test, there were highly significant differences between studied groups at days 1 and 3 and significant differences were detected on days 7 and 14.

[DOI: 10.22088/jbums.27.1.4]

Table 2. Descriptive statistics of inflammatory cells count for all groups in each healing period

Days and Groups	Mean±SD	p-value	F test
Day 1			
Control	26.3±1.6		
OFI	62.3±1.2	0.000**	14.198
PGS	68.02±1		
OFI+PGS	52.0±1		
Day3			
Control	39.0±1.4		
OFI	56.0±0.9	0.011*	5.987
PGS	48.7±0.8		
OFI+PGS	49.3±1.1		
Day 7			
Control	63.0±1		
OFI	33.0±0.7	0.002**	9.533
PGS	37.3±0.7		
OFI+PGS	31.8±0.9		
Day 14			
Control	27.2±1		
OFI	16.3±0.4	0.047*	3.221
PGS	18.2±0.5		
OFI+PGS	16.5±0.5		

***Significant result, ****high Significant result**

Table 3. Descriptive statistics of epithelial thickness in (µm) for all groups in each healing period

Days and Groups	Mean±SD	p-value	F test
Day 1			
Control	0.9±0.1		
OFI	2.8±0.5	0.005**	8.615
PGS	2.1±0.4		
OFI+PGS	3.6±0.3		
Day 3			
Control	5.7±1.3		
OFI	7.1±2.1	0.004**	8.801
PGS	6.9±1.8		
OFI+PGS	8.6±2.2		
Day 7			
Control	12.7±3.2		
OFI	21.8±5.4	0.043*	3.446
PGS	17.1±2.9		
OFI+PGS	23.2±2.8		
Day 14			
Control	22.4±3.3		
OFI	38±4	0.022*	4.87
PGS	31.8±3.7		
OFI+PGS	38.5±3.5		

***Significant result, ****high Significant result**

[DOI: 10.22088/jbums.27.1.4]

Histological finding: The histological analysis of the skin slice at the wound site of the control group reveals the presence of necrotic tissue scabs (s). Additionally, inflammatory cells (IC) were observed in the dermis at the surface. The histological analysis of the experimental groups reveals the presence of migrating epithelial cells along the cut edge on the surface of the wound. Additionally, a significant number of hair follicles were observed in Figure 1 within three days. The histological analysis of the wound site in the control group revealed the presence of necrotic tissue on the wound surface, with a clear demarcation between the expansion of the scab and the growth of new epithelial tissue. In contrast, the experimental groups exhibited the presence of collagen fibers alongside fibroblasts, as well as the emergence of nascent hair follicles. Following the application of oils, the wound surface exhibited the emergence of new epithelial cells underneath the demarcation line, which serves as a boundary between viable tissue and the scab. Additionally, Figure 2 illustrates the presence of hair follicles below the dermis. The histological analysis of the wound site in the control group reveals the presence of newly formed epithelium, collagen fibers undergoing remodeling, and the development of hair follicles over a period of seven days. The histological analysis of the wound site subsequent to the application of oils reveals the presence of full epithelialization, hair follicles, fibroblasts in conjunction with collagen fibers, a substantial number of blood vessels accompanied by nearby inflammatory cells, as seen in Figure 3 within fourteen days. The microphotograph of the wound site in the control group reveals the presence of full epithelialization and the process of collagen fibers remodeling. The histological analysis of the wounds in the experimental groups after a duration of 14 days reveals the presence of full epithelialization at the wound site, together with the presence of hair follicles and the remodeling of collagen fibers (Figure 4).

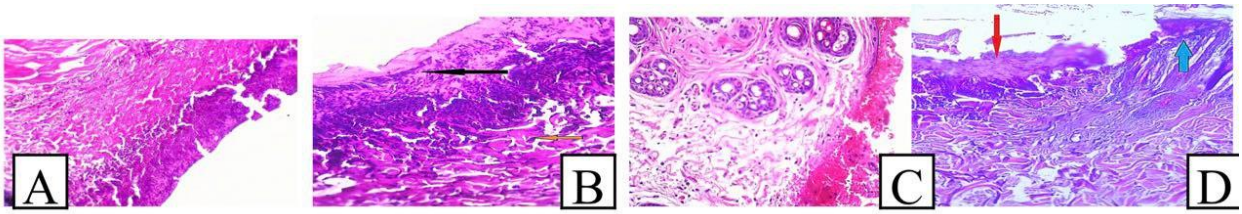

Figure 1. Day 1 a) control group, b) OFI, c) PGS oil, d) FOI/PGS group

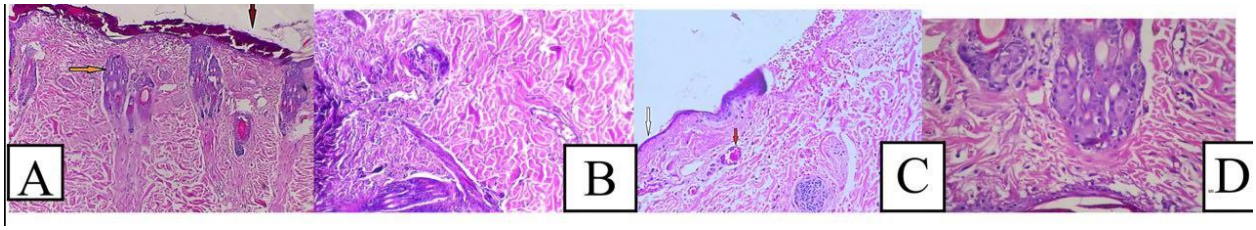

Figure 2. Day 3 a) control group, b) OFI, c) PGS oil, d) FOI/PGS group

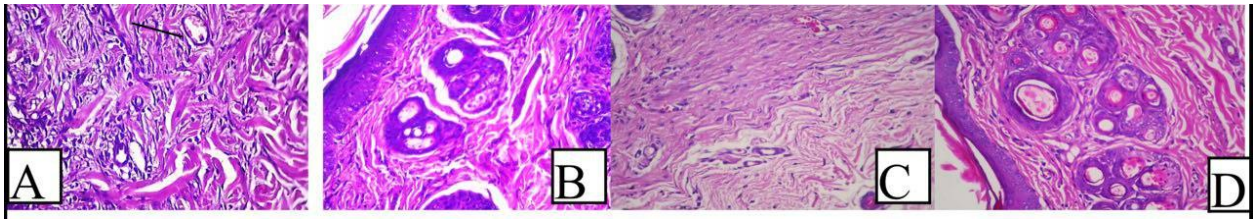

Figure 3. Day 7 a) control group, b) OFI, c) PGS oil, d) FOI/PGS group

[DOI: 10.22088/jbums.27.1.4]

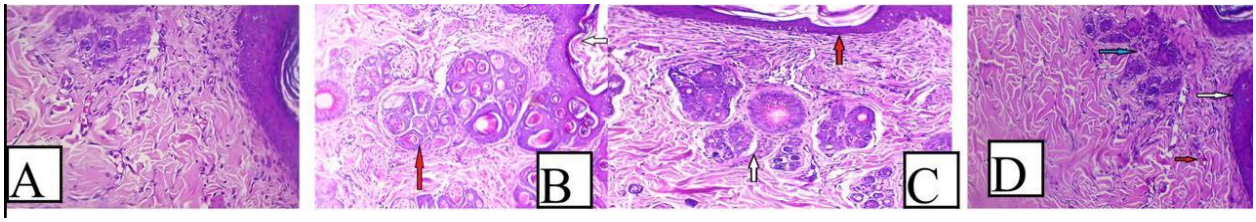

Figure 4. Day 14 a) control group, b) OFI, c) PGS oil, d) FOI/PGS group

Abbreviation: OFI: Opuntia Ficus-Indica, PGS: Punica Granatum Seed oil, SD: Stander Deviation, N: Number. Significance denoted by bold font.

Discussion

In the context of excision wound research, the administration of the herbal extract resulted in a notable increase in the rate of wound contraction and a decrease in the time required for epithelialization in the experimental group of animals, as compared to the control group consisting of animals receiving a placebo or negative treatment. The healing process of the wound exhibits a steady yet rapid progression, often observed on the third or fourth day. The utilization of complementary medicine is seeing an upward trend in popularity as individuals seek for secure and efficacious alternatives to conventional pharmaceutical interventions. The increasing popularity of herbal medicine can be attributed to advancements in scientific research. According to a study conducted by Alostad et al. (9), it is projected that almost 80% of the global population would use herbal medicine into their fundamental healthcare practices. The plant known as PGS exhibits robust fruit-bearing capabilities and possesses therapeutic qualities, including anti-osteoporotic, anti-inflammatory, and anti-oxidant effects (10). Rabbits are very suitable for application in several domains of experimental animal medicine, including human dermatology, experimental toxicology, and experimental pharmacology. The indigenous rabbit is a versatile creature with a wide range of uses. The integumentary system is composed of two main layers, namely the epidermis and dermis, which are interconnected by subcutaneous tissue to adjacent anatomical components like muscle and bone. The epidermis mostly consists of stratified cornified squamous epithelium. The dermis predominantly consists of irregular connective tissue, which contains blood vessels and nerves, and is interspersed with hair follicles (11).

The relationship between wound healing and wound morphology was investigated in a study by Mori et al. (12). The wound was created using a punch biopsy technique, as described by Mori et al. (12). The study found that the application of a topical herbal extract oil to a full-thickness circular layer of dorsal skin in animals resulted in faster wound closure compared to a control group, as reported by Mori et al (12). Another study shown that the average wound contraction was reduced with time in the study groups that received topical oil treatment (13). The present study revealed that wound contraction was hastened in all experimental groups. The experimental groups B, C, and B&C were compared to the control group A. The lowest mean value was seen in group C, compared to groups B and D, following the control group.

The findings of this investigation are consistent with study of Koshak et al. (5) which showed that the topical administration of OFI seed oil resulted in a substantial improvement in wound healing. OFI treatment exhibited a considerable acceleration in wound closure when compared to control groups that did not receive any treatment. The assessment of wound constriction percentages revealed a statistically significant increase in wound constriction in animals subjected to herbal medicine treatment.

[DOI: 10.22088/jbums.27.1.4]

The findings of this investigation are consistent with study of Khalil Ahmed et al. (14) which showed that the use of topical therapy accelerated wound contraction and re-epithelialization. The use of essential oils at the site of wounds, particularly throughout the process of wound healing, is of significant importance. The duration is 3 to 7 days. The evaluation of the impact of herbal oil on wound healing revealed a decline in the average wound size with time, with the experimental group exhibiting the lowest values on day 14. These findings align with the outcomes of the present investigation.

The findings of this study demonstrated that the application of OFI and PGS resulted in enhanced wound contraction. This effect might lead to the increased proliferation and advancement of epidermal cells in the experimental group, as well as the anti-inflammatory properties of these oils.

Acknowledgment

We gratefully thank the specialized veterinary doctors at the cancer research center for their support.

[DOI: 10.22088/jbums.27.1.4]

References

1.Paul W, Sharma CP. Tissue and Organ Regeneration: An Introduction. In: Sharma CP, editor. Regenerated Organs: Future Perspectives, 1st ed. Academic Press; 2021. p. 3-9.

2.Chhabra S, Chhabra N, Kaur A, Gupta N. Wound Healing Concepts in Clinical Practice of OMFS. J Maxillofac Oral Surg. 2017;16(4):403-23.

3.Grubbs H, Manna B. Wound Physiology. Treasure Island (FL): StatPearls Publishing; 2022.

4.Pereira RF, Bártolo PJ. Traditional Therapies for Skin Wound Healing. Adv Wound Care (New Rochelle). 2016;5(5):208-29.

5.Koshak AE, Algandaby MM, Mujallid MI, Abdel-Naim AB, Alhakamy NA, Fahmy UA, et al. Wound Healing Activity of *Opuntia ficus-indica* Fixed Oil Formulated in a Self-Nanoemulsifying Formulation. Int J Nanomedicine. 2021;16:3889-905.

6.Al-Kadhimy BJ, Ghani BA. In vivo histological evaluation of the effect of the topical application of estrogen hormone on wounds healing in ovariectomized rabbit. J Bagh Coll Dent. 2015;27(1):100-4.

7.Al-Wattar WM, Abdulluh BH, Mahmmod AS. Irradiation effect of 780-805nm diode laser on wound healing in mice. J Bagh Coll Dent. 2013;25 (Special Issue 1):48-52.

8.Muhammad NH, Ghani BA. Histological Evaluation of the Effect of Topical Application of Curcumin Powder and Essential Oil on Skin Wound Healing. J Bagh Coll Dent. 2015;27(3):58-63.

9.Alostad AH, Steinke DT, Schafheutle EI. International Comparison of Five Herbal Medicine Registration Systems to Inform Regulation Development: United Kingdom, Germany, United States of America, United Arab Emirates and Kingdom of Bahrain. Pharmaceut Med. 2018;32(1):39-49.

10.Burhan E, Thahar B, Abidin T, Putra DP, Gani BA. Analysis Reactivity Of Punic Granatum Polyphenols To The Osteocalcin, Bone Morphogenetic Protein-2, And Collagen Type-1. Asian J Pharm Clin Res. 2018;11(12):544-7.

11.Ibrahim RS, Hussein AA, Jabbar AI. Comparative microscopically study of the skin in local and wild rabbits. Kufa J Vet Med Sci. 2017;8(1):152-6.

12.Mori HM, Kawanami H, Kawahata H, Aoki M. Wound healing potential of lavender oil by acceleration of granulation and wound contraction through induction of TGF-β in a rat model. BMC Complement Altern Med. 2016;16:144.

13.Ali SH, Ghani BA Kamil NB. In Vivo Histological Assessment of Local Application of Fenugreek Seed Oil on Cutaneous Wound Healing. Medico-legal Update. 2022;22(2):167-75.

14.Khalil Ahmed H, Ghani BA. Histological assessment of effect of Cinnamomum Zeylanicum Extract on Experimentally Induced Cutaneous Wound Healing in Rats. Diyala J Med. 2020;18(2):1-11.

[DOI: 10.22088/jbums.27.1.4]