

## Acute Pancreatitis as A Complication of Typhoid Fever: A Case Report

S. Mehrabani (MD)\*<sup>1</sup>

1.Non-Communicable Pediatric Disease Research Center, Health Research Institute, Babol University of Medical Sciences, Babol, I.R.Iran

J Babol Univ Med Sci; 22; 2020; PP: 376-379

Received: May 13<sup>rd</sup> 2020, Revised: Aug 2<sup>nd</sup> 2020, Accepted: Aug 10<sup>th</sup> 2020.

### ABSTRACT

**BACKGROUND AND OBJECTIVE:** Typhoid fever could have a wide range of complications. Pancreatitis is a rare complication in children with typhoid fever. The aim of this case report is to describe a case of typhoid fever presented with acute pancreatitis (AP).

**CASE REPORT:** A 13-year-old girl with fever and abdominal pain around the umbilical region lasting one week was referred to the Amirkola Children's Hospital. She had recurrent non-bloody, non-biliary vomiting and watery diarrhea while she had dysentery during admission. She had drunk spring water in a recent trip. The stool culture was positive for *Salmonella* Typhi. The Widal test results were first: TO:1.80, TH:1.80 and after one week: TO:1.320, TH:1.320. Hydrotherapy along with treatment with cefotaxime (50 mg/kg for 14 days) recovered the patient from dysentery, nausea and fever. After one week, she complained of periumbilical abdominal pain, vomiting and tenderness of epigastric region. Lipase level was elevated to 500 U/L and her pain became worse. Spiral abdominopelvic CT scan showed normal liver, spleen, gallbladder and bile ducts. However, the pancreas tail was hypodense and larger than normal. The pancreatitis was treated by hydration and intravenous pantoprazole. After two weeks of admission, she was discharged with remission, and the lab tests and ultrasound examination were normal within a 4-week follow-up.

**CONCLUSION:** According to this case report the pancreatitis should be considered in children with typhoid fever and persistent abdominal pain.

**KEY WORDS:** *Typhoid Fever, Pancreatitis, Child.*

### Please cite this article as follows:

Mehrabani S. Acute Pancreatitis as A Complication of Typhoid Fever: A Case Report. J Babol Univ Med Sci. 2020; 22: 376-9.

\*Corresponding Author: S. Mehrabani (MD)

Address: Non-Communicable Pediatric Disease Research Center, Amircola Children's Hospital, Babol University of Medical Sciences, Babol, I.R.Iran

Tel: +98 11 32346963

E-mail: mehrabanisanaz@gmail.com

## Introduction

Typhoid fever caused by *Salmonella enterica* serovar Typhi bacteria is one of the causes of mortality and morbidity in children (1, 2). The disease is more prevalent in low- and middle-income countries, and human being is its only host and reservoir (2). Its common signs and symptoms include fever, anorexia, vomiting, abdominal pain, constipation, diarrhea, hepatomegaly and splenomegaly (3-6). Osteomyelitis, intra-abdominal abscess, urinary tract infection, pancreatitis and meningitis are its extra-intestinal manifestations (7, 8).

There are few reports regarding pancreatitis in children with typhoid fever (9-11). The gold standard of typhoid fever diagnosis is bone marrow positive culture, but the diagnosis is also confirmed with positive blood and stool culture (12). Pancreatitis is a rare complication among children with typhoid fever (9, 10). The pancreas may be involved in the second stage of typhoid sepsis (13). Supportive care, including fluid therapy and gastric acid suppression, are principles of acute pancreatitis management in children (14). Here, a case of typhoid fever with acute pancreatitis is reported.

## Case Report

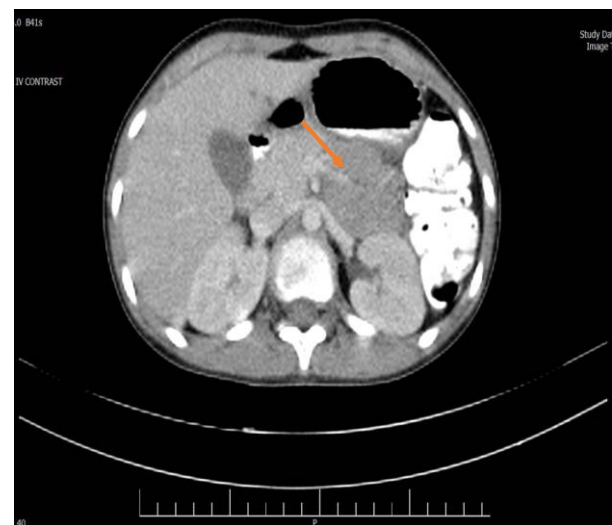
This study was approved by the ethics committee of Babol University of Medical Sciences (IR.MUBABOL.HRI.REC.1399.093) and informed consent was taken from this patient and his parents. A 13-year-old girl with fever and abdominal pain around the umbilical region lasting one week was referred to the Amirkola Children's Hospital of Babol University of Medical Sciences. She had recurrent non-bloody, non-biliary vomiting and watery diarrhea while she had dysentery during admission. Her weight was 40 kg. She had colicky abdominal pain, worsened during defecation. She had drunk spring water in a recent trip with her family; similar signs were reported in her sister.

The patient was treated with cefixime tablet 400mg/day for 5 days before admission due to the outpatient diagnosis of bacterial gastroenteritis. The patient reported no chronic illnesses as well as no use of any medications or alcohol before becoming symptomatic. At the time of admission, her vital signs were as follows: temperature: 38c, blood pressure: 95/70 mmHg, pulse rate: 95/min, respiratory rate: 16/min. She was dehydrated, and the periumbilical pain was reported. Other examinations were normal. Her lab

test showed: CBC:WBC:  $6.9 \times 10^3/\mu\text{l}$ , poly: 59%, lymph: 38%, mono: 1%, Hb: 12 g/dl, PLT:  $241 \times 10^3/\mu\text{l}$ , ESR: 33mm/h, CRP: 23 mg/dl, Stool exam: WBC: 8-10, RBC: 2-3. After 48 hours, the stool culture was positive for *Salmonella* Typhi (*S. Typhi*) sensitive to cefotaxime. Biochemistry tests were normal, and the blood culture was negative. The Widal test results were first: T0: 1/80, TH: 1/80 and after one week: TO: 1.320, TH: 1.320.

Hydrotherapy along with treatment with cefotaxime (50 mg/kg for 14 days) recovered the patient from dysentery, nausea and fever. After one week, she complained of periumbilical abdominal pain, vomiting and tenderness of epigastric region. Lab results were: AST: 35 IU/L, ALT: 25 IU/L, ALP: 399 IU/L, Amylase: 181 U/L, Lipase: 200 U/L, CBC:WBC:  $6.6 \times 10^3/\mu\text{l}$ , Poly: 42%, Lymph: 50%, Mono: 8%, Hb: 11/7 g/dl, PLT:  $295 \times 10^3/\mu\text{l}$ . After one week, the second blood culture was negative again. Abdominal ultrasound was normal while the lipase level was elevated to 500 U/L (normal range: <60 U/L), and her pain became worse. Spiral abdominopelvic CT scan indicated normal liver, spleen, gallbladder and bile ducts. However, the pancreas tail was hypodense and larger than normal (figure 1).

The pancreatitis was treated by hydration and intravenous pantoprazole (1 mg/kg, q 12 h), and her symptoms subsided with this method. On the 14th day of hospitalization, the patient was fully recovered and discharged from hospital. Moreover, the lab tests and ultrasound examination were normal within a 4-week follow-up.



**Figure 1. Abdominal CT scan indicating pancreatitis (tail enlargement)**

## Discussion

Here, we reported a 13-year-old girl with typhoid fever who presented with AP. In cases with typhoid fever, the characteristics of pancreatitis vary from biological abnormalities to pancreatic abscesses (7). Pancreatitis is a rare complication among children with typhoid fever (9, 10). Our case was first presented with fever and abdominal pain around the umbilical region. Although pancreatitis is one of the rare complications of typhoid fever, Hermans et al. reported biologic signs of pancreatitis in 7 out of 14 adults who had typhoid fever and clinical signs in 4 out of 14 cases (11). In their study, the liver and pancreas were the two most common sites of complication (11).

The most reliable diagnostic methods for typhoid fever are blood, bone marrow and stool culture (12). In our patient, the stool culture was positive for *S. Typhi*. Though there are some controversies on the Widal test, it depends on the rising titer of antibodies (12). This rising titer was observed in the current case. The pathogenesis of pancreatitis following typhoid fever is not clear while literature illustrates that the *S. Typhi* can be found in bile fluid and/or cultures of gallstones (13). The pancreas might be affected during the second phase of typhoid septicemia (13).

Asano et al. reported a 4-year-old girl referred to the hospital with diarrhea, fever, vomiting and diffuse tenderness around the umbilicus. The CT scan revealed enlargement in the body and tail of the pancreas. The

blood and stool cultures were positive for *S. Typhi*. After three months, she was discharged from hospital, and her follow-up laboratory tests were normal (9). In our case, the CT scan indicated the pancreas tail was hypodense and larger than normal.

Roy et al. presented a 5-year-old girl with AP as a complication of typhoid fever. She responded to conservative and antibiotic therapy (10). The principles of AP management in pediatrics are supportive care such as gastric acid suppression and fluid therapy (14). The present case had symptoms and signs of pancreatitis as well as responded to pancreatitis treatment. She was discharged after a 14-day treatment period, and the lab tests and imaging results were normal during a one-month follow-up.

Previously, eight pancreatitis cases were reported following typhoid fever, one of which had a pancreatic abscess (13,15-21). As pancreatic enzymes are not checked routinely, some cases might be missed. In developing countries such as Iran, the pancreatitis should be considered in children with typhoid fever.

**Conflict of interest:** The author declares that she has no conflict of interest

## Acknowledgment

The author is deeply thankful for the cooperation of child and her parents.

## References

1. Prasad N, Jenkins AP, Naucukidi L, Rosa V, Sahu-Khan A, Kama M, et al. Epidemiology and risk factors for typhoid fever in Central Division, Fiji, 2014-2017: A case-control study. *PLoS Negl Trop Dis*. 2018;12(6):e0006571.
2. Mweu E, English M. Typhoid fever in children in Africa. *Trop Med Int Health*. 2008;13(4):532-40.
3. Walia M, Gaiind R, Mehta R, Paul P, Aggarwal P, Kalaivani M. Current perspectives of enteric fever: a hospital-based study from India. *Ann Trop Paediatr*. 2005;25(3):161-74.
4. Nsutebu EF, Martins P, Adiogo D. Prevalence of typhoid fever in febrile patients with symptoms clinically compatible with typhoid fever in Cameroon. *Trop Med Int Health*. 2003;8(6):575-8.
5. Papaevangelou V, Syriopoulou V, Charissiadou A, Pangalis A, Mostrou G, Theodoridou M. Salmonella bacteraemia in a tertiary children's hospital. *Scand J Infect Dis*. 2004;36(8):547-51.
6. Ispahani P, Slack RC. Enteric fever and other extraintestinal salmonellosis in University Hospital, Nottingham, UK, between 1980 and 1997. *Eur J Clin Microbiol Infect Dis*. 2000;19(9):679-87.
7. Lambotte O, Debord T, Castagne C, Roue R. Unusual presentation of typhoid fever: cutaneous vasculitis, pancreatitis, and splenic abscess. *J Infect*. 2001;42(2):161-2.
8. Cohen JL, Bartlett JA, Corey GR. Extra-intestinal manifestations of salmonella infections. *Medicine (Baltimore)*. 1987;66(5):349-88.
9. Asano T, Kuwabara K, Takagi A, Hatori T, Hamada H, Imai T, et al. Acute pancreatitis complicating typhoid fever in a 4-year-old girl. *Pediatr Int*. 2007;49(6):1004-6.
10. Roy S, Majumdar SD, Chakrabartty S, Chakravarti S. Typhoid fever with acute pancreatitis in a five-year-old child. *J Pediatr Infect Dis*. 2018;13(03):240-1.
11. Hermans P, Gerard M, Laethem YV, de Wit S, Clumeck N. Pancreatic disturbances and typhoid fever. *Scand J Infect Dis*. 1991;23(2):201-5.
12. Mawazo A, Bwire GM, Matee MIN. Performance of Widal test and stool culture in the diagnosis of typhoid fever among suspected patients in Dar es Salaam, Tanzania. *BMC Res Notes*. 2019;12:316.
13. Hearne SE, Whigham TE, Brady CE. Pancreatitis and typhoid fever. *Am J Med*. 1989;86(4):471-3. Available from: <https://www.sciencedirect.com/science/article/pii/0002934389903495?via%3Dihub>
14. Husain SZ, Srinath AI. What's unique about acute pancreatitis in children: risk factors, diagnosis and management. *Nat Rev Gastroenterol Hepatol*. 2017;14(6):366-72.
15. Sédallian P, Monnet P, Brette R. A case of typhic pancreatitis. *Lyon Med*. 1947;177(22):432-4.
16. Monod-Broca P, Auzépy P, Lesourd G, Goumet C. Pancréatite aiguë typhique vérifiée opératoirement: Guérison [Acute typhoid pancreatitis surgically verified. Cure]. *Mem Acad Chir (Paris)*. 1967;93(24):779-83.
17. Spay G, Savoye B, Rahimi N. Typhoïde et pancréatite, pancréatite typhique? A propos d'un cas [Typhoid and pancreatitis: typhic pancreatitis? Apropos of a case]. *J Med Lyon*. 1971;52(219):1741-2.
18. Kune GA, Coster D. Typhoid pancreatic abscess. *Med J Aust*. 1972;1(9):417-8.
19. Lemańczyk M, Kamińska E, Wejchert K. Zapalenie przydatków w przebiegu duru brzuszego u dziewczynki 13-letniej [Adnexitis in the course of typhoid fever in a 13-year-old girl]. *Pediatr Pol*. 1974;49(8):1027-8.
20. Russell IJ, Forgacs P, Geraci JE. Pancreatitis complicating typhoid fever. report of a case. *JAMA*. 1976;235(7):753-4.
21. Ginsburg C, Raffenne L. Fièvre typhoïde compliquée d'insuffisance rénale aiguë, de rhabdomyolyse et de pancréatite aiguë [Typhoid fevers complicated by acute renal failure, by rhabdomyolysis and by acute pancreatitis]. *Rev Med Interne*. 1989;10(3):279-80.