

A Case of Polypoid Intraoral Nevus in Buccal Mucosa: a Case Report

S. Baghery Moghadam (DDS,MS)¹, N. Mortazavi (DDS,MS)¹, A.R. Ahmadiania (DDS,MS)¹,
F. Mirzaei ^{*2}

1.Dental Research Center, Golestan University of Medical Sciences, Gorgan, I.R.Iran

2.Student Research Committee, Golestan University of Medical Sciences, Gorgan, I.R.Iran

J Babol Univ Med Sci; 22; 2020; PP: 241-244

Received: Oct 19th 2019, Revised: Des 15th 2019, Accepted: Feb 6th 2020.

ABSTRACT

BACKGROUND AND OBJECTIVE: Mouth discoloration can be of internal or external origin. Melanotic nevus are the result of benign proliferation of melanocytes, the intraoral type of which is not as common as melanotic skin moles. In addition, they have the potential for malignant changes and can develop into oral melanoma. In this article, a case of Polypoid Intraoral Nevus is reported.

CASE REPORT: In intraoral examination, a 21-year-old man who had referred to the Oral Diseases Department for dental scaling and examination showed a prominent black lesion with a smooth, 1×1 cm long lobular surface and a firm consolidation in the buccal mucosa. The lesion was asymptomatic and not sensitive to touch. Chronic stimulation was not reported on clinical examination and history, and the diascopy test was negative. Systemic disease and history of drug and tobacco use were not reported. The lesion was removed by excisional biopsy while maintaining a safe margin. The macroscopic specimen was a brownish-gray lesion with elastic consolidation and the microscopic appearance of benign proliferation of nevus cells and melanin production in the connective tissue was observed. The final diagnosis was an intra-mucosal lesion. The patient referred for regular six-month examinations for two years, during which no recurrence or similar symptoms were observed in the oral mucosa.

CONCLUSION: In the present case, the histopathological result indicated a mucosal nevus after excisional biopsy.

KEY WORDS: *Nevus, Melanocyte, Pigmentation.*

Please cite this article as follows:

Baghery Moghadam S, Mortazavi N, Ahmadiania AR, Mirzaei F. A Case of Polypoid Intraoral Nevus in Buccal Mucosa: a Case Report. J Babol Univ Med Sci. 2020; 22: 241-4.

*Corresponding Author: F. Mirzaei

Address: Faculty of Dentistry, Golestan University of Medical Sciences, Gorgan, I.R.Iran

Tel: +98 17 32344830

E-mail: fatemehmirzaei.ir.1998@gmail.com

Introduction

Mouth discoloration can be of internal or external origin. Discoloration of foreign origin is usually caused by the presence of a foreign body in the mucosa. Internal discoloration includes melanin, hemosiderin, hemoglobin, and carotene. Depending on the amount and position of melanin in the lesion, the nevus inside the mouth can appear brown, blue, gray or black (1). Melanotic nevi can be congenital or acquired and their etiology and pathology are not well understood (2).

Since the 1960s, there have been reports of isolated cases of oral melanocytic nevus in which the ratio of women to men is approximately 1.5 to 1, with a diagnostic age range of 3 to 85 years and no racial effects. Unlike skin moles, oral melanotic nevi are highly uncommon, so that the number of such nevi does not exceed 0.1% of oral biopsies (3-5).

Today, researchers think of oral melanotic nevi as benign tumors composed of cells that have split from the neural tube of fetus. However, intraoral nevi have the potential for malignant changes and may develop into oral melanoma (6-8). Therefore, early and timely diagnosis of this lesion may improve a very poor prognosis associated with oral melanoma. Similar to skin moles, oral melanotic nevi are classified as junctional, compound, intra-mucosal, blue and mixed moles (9). Benign proliferation of melanocytes in junctional, compound and intra-mucosal types occurs in the basal layer, basal layer and superficial lamina propria, and exclusively in the lamina propria layer, respectively (10). The most common site of melanocyte mole is on the skin and its observation on the mucosa, especially the buccal mucosa, is a rare diagnostic case. This study reports a case of polypoid intraoral nevus in buccal mucosa.

Case Report

In the intraoral examination of a 21-year-old man who had referred to the Oral Diseases Department of Zahedan Dental School for scaling and dental examination, a prominent black lesion with a smooth, 1×1 cm long lobular surface and a firm consolidation in the left buccal mucosa were observed. The lesion had no symptoms of pain or bleeding and was not tender to the touch. The diascopy test was performed with a glass slide and the result was negative. The patient had no systemic disease, no history of drug or tobacco use, and no habits of cheek biting, and was unaware of such a lesion in the oral cavity. No pathological symptoms or

asymmetry were observed in the oral examination. There was no palpable lymph node in the neck. Due to the absence of pain and symptoms, a nevus was considered in the mucosa and melanoma in the differential diagnosis of the lesion, and due to the fact that the lesion was stimulated with a pigmented surface, it was placed at the bottom of the list of differential diagnoses.

The lesion was removed by excisional biopsy and maintaining a safe margin and a tissue sample was sent for histopathological evaluation. The macroscopic specimen was a brownish-gray lesion with elastic consolidation which was seen in the microscopic view of benign proliferation of nevus cells and melanin production in the connective tissue. Due to the fact that the blue nevus is an accumulation of elongated and narrow nevus cells with dendritic appendages and are located deep in the dermis or lamina propria, the lesion was differentiated from the mucosal nevus and the final diagnosis of the lesion was mucosal nevus. The patient referred for regular six-month examinations for two years, during which time no recurrence or similar symptoms were observed in the oral mucosa.

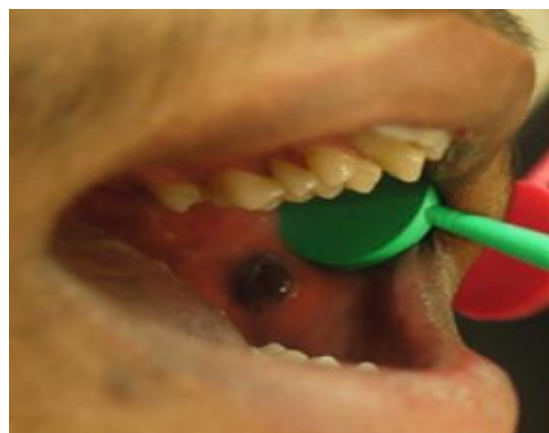

Figure 1. Black polypoid nevus

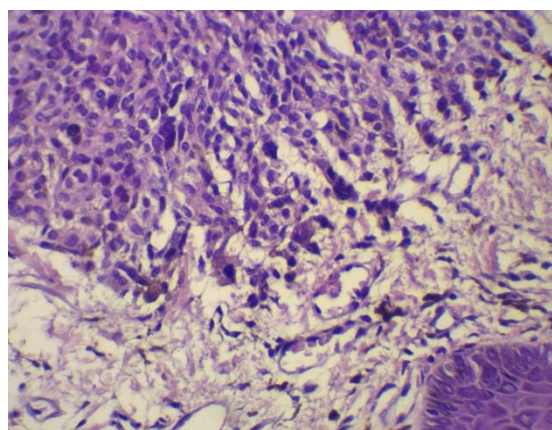


Figure 2. Histopathological view

Discussion

The case reported here is a polypoid intraoral nevus, which is one of the rare lesions with discoloration in the mouth in terms of its location in the oral mucosa and in the buccal mucosa. Cardoso et al. reported a dark brown macula in the maxillary buccal mucosa of a 22-year-old man who took phenytoin to treat epilepsy. No discolored lesions were observed in other mucosa of the patient. In histopathological specimens, nevus cells were present in the epithelium and connective tissue. As reported by the order in which the nevus cells are located in these two tissues, the feature of the nevus is "compound" and differs from our histological specimen in which melanocytes are found exclusively in the lamina propria (5).

Pandey et al. reported a nevus on the buccal mucosa of a 5-year-old child. The lesion, which lasted for two months, was painless and about 5 mm in size. After hematological tests and histopathological examination, the final diagnosis was made for the patient (8). Bonan et al. reported an intra-mucosal nevus on the cheek of a 23-year-old woman that had developed as a brown nodule in the left cheek for 15 years and had no irritating factor in the area. Histological examination confirmed the intra-mucosal nevus (11), which was also seen in our

findings. In this tissue sample, melanocytes have penetrated into the lamina propria and were found exclusively in this area. In a study by Beena et al., a pigmented lesion in the labial mucosa of a 22-year-old woman was reported. It was stated that the lesion was sometimes accompanied by pain. The lesion was black and slightly more prominent than the surrounding mucosa, and no recurrence of the lesion was seen after biopsy. In this histopathological specimen, as in the present case, the melanocyte nevus was "intra-mucosal" without recurrence and it was benign (9).

To date, there have been no reports of malignant changes in intraoral nevi, but due to the possibility of melanoma appearing in different forms, all intraoral nevi should be removed and evaluated histopathologically. In these lesions, surgical resection is recommended and the patient should be instructed to examine these lesions in his/her mouth and report them to the doctor in case of recurrence.

Acknowledgment

We would like to thank the Research Center of the School of Dentistry of Golestan University of Medical Sciences and Dr. Leila Farhad Mollashahi.

References

1. Eisen D. Disorders of pigmentation in the oral cavity. *Clin Dermatol*. 2000;18(5):579-87.
2. Buchner A, Merrell PW, Carpenter WM. Relative frequency of solitary melanocytic lesions of the oral mucosa. *J Oral Pathol Med*. 2004;33(9):550-7.
3. Bauer J, Garbe C. Acquired melanocytic nevi as risk factor for melanoma development. A comprehensive review of epidemiological data. *Pigment Cell Res*. 2003;16(3):297-306.
4. Meleti M, Mooi WJ, Casparie MK, van der Waal I. Melanocytic nevi of the oral mucosa—No evidence of increased risk for oral malignant melanoma: An analysis of 119 cases. *Oral Oncol*. 2007;43(10):976-81.
5. Cardoso LB, Consalaro A, da Silva Santos PS, da Silva Sampieri MB, Tinoco-Araujo JE. Oral compound nevus. *Dermatol Online J*. 2014;20(2).
6. Bashamalla R, Rao GV, Ramulu S, Sravya T. Pigmented intramucosal nevus of gingiva with a special insight on its pathophysiology: Report of a rare entity. *J Dr. NTR Univ Health Sci*. 2017;6(3):181-4.
7. Raj AT, Patil S, Rajkumar C. Are oral mucosal nevi potential precursors for oral mucosal melanoma?. *Oral Oncol*. 2018;79:83.
8. Pandey P, Chaudhary CP, Ansari AA, Singh R. Intramucosal nevus of buccal mucosa in a male child. *BMJ Case Rep*. 2013;2013:bcr2013010191.
9. Beena VT, Chauhan I, Heera R, Rajeev R. Oral melanotic nevi: A case report and review of literature. *Oral Maxillofac Pathol J*. 2010;1(1).
10. Ferreira L, Jham B, Assi R, Readinger A, Kessler HP. Oral melanocytic nevi: a clinicopathologic study of 100 cases. *Oral Surg Oral Med Oral Pathol Oral Radiol*. 2015;120(3):358-67.
11. Bonan PRF, Ribeiro ILA, de Andrade ALDL, da Rosa MRD. Melanocytic nevus in the buccal mucosa: A case report. *Rev Odonto Ciência*. 2012;27(4):349-52.