

## Effect of Omega-3 on Rat Sperm DNA Methylation and Histological Structure of Testis after Treatment with Bleomycin, Etoposide and Cisplatin (BEP)

Sh. Razavi (PhD)\*<sup>1</sup>, F. Hashemi (MSc)<sup>1</sup>, F. Khadivi (MSc)<sup>1</sup>

1. Department of Anatomical Sciences, School of Medicine, Isfahan University of Medical Sciences, Isfahan, I.R.Iran

J Babol Univ Med Sci; 21; 2019; PP: 273-78

Received: Oct 15<sup>th</sup> 2018, Revised: Mar 3<sup>rd</sup> 2019, Accepted: May 20<sup>th</sup> 2019.

### ABSTRACT

**BACKGROUND AND OBJECTIVE:** During the cancer treatment course, in addition to the destructive effects on the tumor cells, chemotherapy also damages healthy tissues and disrupts the balance of oxidant and antioxidant levels. The present study was conducted to evaluate the effect of omega-3 on sperm DNA methylation and histological structure of rat testis after treatment with combination chemotherapy using bleomycin, etoposide and cisplatin (BEP).

**METHODS:** In this experimental study, 40 male rats were randomly divided into four groups of control, BEP, BEP+omega-3 and omega-3 (n=10). The control group was treated with 0.9% normal saline intraperitoneally for 18 weeks. The second group (BEP) first received 0.9% normal saline intraperitoneally for nine weeks. Then, it received BEP at 5.1 mg / kg for nine weeks, received etoposide and cisplatin at 5.7 mg/kg through gavage on days 1-5 of each week, and then received bleomycin at 75 mg/kg on days 2 of each week. The third group was gavaged with 0.9% saline for 9 weeks and then, orally received 300 mg/kg/day omega-3 (capsule containing 1000 mg, 18% EPA and 12% DHA) for 9 weeks and in BEP + omega-3 group treated with BEP based on the same method and then orally received 300 mg/kg omega-3 as an antioxidant for the second nine weeks daily. Sperm DNA methylation and histological structure of rat testis including seminiferous tubules and basement membrane thickness were respectively evaluated by immunofluorescence staining and Periodic acid – Schiff (PAS) after 18 weeks of treatment in all groups.

**FINDINGS:** The mean percentage of sperm DNA methylation in the BEP-treated group ( $52.22 \pm 3.11$ ) was significantly decreased compared to the control group ( $81.80 \pm 2.92$ ) ( $p < 0.001$ ). However, the mean percentage of sperm DNA methylation increased significantly with omega-3 use after treatment with BEP ( $67 \pm 2.18$ ) compared with BEP group ( $p < 0.01$ ). In light microscopy of testicular tissue, the number of spermatogonial cells ( $44.95 \pm 1.56$ ), primary spermatocytes ( $47.60 \pm 1.45$ ) as well as the epithelial thickness of seminiferous tubules ( $145.5 \pm 5.64$ ) and basement membrane ( $7.07 \pm 0.29$ ) decreased in the BEP-treated group in comparison with control group ( $p < 0.001$ ). However, the use of omega-3 after treatment with BEP significantly improved the number of germ cells and epithelial thickness of the seminiferous tubule and basement membrane ( $p < 0.01$ ).

**CONCLUSION:** Based on the results of this study, omega-3 as an antioxidant can improve the cytotoxic effects of chemotherapy drugs and it is recommended to be used for cancer patients after chemotherapy to reduce the cytotoxicity of these drugs.

**KEY WORDS:** Antioxidant, Oxidative Stress, Omega-3, Chemotherapy, DNA Methylation.

### Please cite this article as follows:

Razavi Sh, Hashemi F, Khadivi F. Effect of Omega-3 on Rat Sperm Dna Methylation and Histological Structure of Testis after Treatment with Bleomycin, Etoposide and Cisplatin (BEP). J Babol Univ Med Sci. 2019;21: 273-78.

\*Corresponding Author: Sh. Razavi (PhD)

Address: Department of Anatomical Sciences, School of Medicine, Isfahan University of Medical Sciences, Isfahan, I.R.Iran

Tel: +98 31 37929055

E-mail: razavi@med.mui.ac.ir

## Introduction

The goal of cancer treatment is to eradicate the tumor cells in the patient's body. Chemotherapy and radiotherapy are commonly used to complete the treatment process after surgery and to prevent metastasis (1). In addition to treating cancer, chemotherapy drugs can damage other tissues, including the male reproductive system (2). Usually, the balance between the levels of oxidants and antioxidants is disturbed during treatment with anticancer drugs (3). Pathologic effects of reactive oxidative stress (ROS) include reduced sperm motility, DNA damage, protein, as well as apoptosis. All cellular constituents including carbohydrates, proteins, lipids and nucleic acids are potential targets of ROS and increased oxidative stress as a destructive factor can damage the sperm and alter the structure of the sperm and ultimately reduce male fertility (4, 5).

Among chemotherapy drugs, one can mention the adverse effects of bleomycin, etoposide and cisplatin (BEP) on reproductive organs including weight loss of testes, decreased sperm count and motility, DNA damage, abnormal spermatogenesis and cell apoptosis (6, 7). Men are affected by DNA damage during treatment with BEP, which affects their fertility (8), as sperm fertility depends on sperm DNA integrity (6). DNA methylation is one of the epigenetic mechanisms that is comprehensively studied and involves the addition of the methyl group at the 5-carbon of the cytosine ring via covalent bonding by DNA methyltransferase enzyme.

In men, the acquisition of the correct pattern of DNA methylation of germ cells occurs mainly at the embryonic period, and then completes in adulthood and during the process of maturation during transition into the epididymis. The correct pattern of DNA methylation is important in a few cellular processes such as transcription termination of some genes (9). In rats treated with BEP, the pattern of DNA methylation was changed in the testis (10). The body has an antioxidant defense system against to damage caused by free radicals. It has now been shown that antioxidants such as omega-3 reduce oxidants produced by doxorubicin and lipid peroxide in testicular tissue through oxidative stress modulators such as superoxide dismutase and glutathione peroxidase (SOD and GSH-PX) (11). In addition, omega-3, as an unsaturated fatty acid, has anti-inflammatory, antioxidant and anti-apoptotic properties and have been known to inhibit cell proliferation and tumor formation in cancer (12). The aim of this study was to evaluate the protective effects of omega-3 on

sperm DNA methylation, germ cells and testicular tissue structure after chemotherapy with BEP.

## Methods

**Animal Preparation:** After being approved by the Ethics Committee of Isfahan University of Medical Sciences (Code: 396145), this experimental study was performed on 40 adult male Wistar rats weighing 180 to 250 g with approximate age of 12-13 weeks purchased from Pasteur Institute of Iran. Before beginning the study, the animals were exposed to 12:12 h light-dark cycle under similar conditions for 10 days. Rats were housed in standard cages at  $21 \pm 2$  °C with free access to rodent food and water in the animal sanctuary of Isfahan University of Medical Sciences. All materials, except for the mentioned ones, were purchased from Sigma Co.

**Treatment with BEP and antioxidant:** The rats were divided into four groups of 10 and experimented for 18 weeks, which is approximately equivalent to two cycles of spermatogenesis in rats. The control group was treated with 0.9% normal saline intraperitoneally for 18 weeks. The second group (BEP) received 0.9% normal saline intraperitoneally for nine weeks. Then, it received BEP at 5.1 mg/kg for nine weeks, received etoposide and cisplatin at 5.7 mg/kg gavage on days 1-5 of each week, and then received bleomycin at 75 mg/kg on days 2 of each week. The third group was gavaged with 0.9% saline for 9 weeks and then, orally received 300 mg/kg/day omega-3 (capsule containing 1000 mg, 18% EPA and 12% DHA) for 9 weeks and in BEP+omega-3 group treated with BEP based on the same method and then orally received 300 mg/kg omega-3 as an antioxidant for the second nine weeks daily (6). All chemotherapeutic agents were purchased from Helal Ahmar pharmacy in Isfahan.

**Sampling of epididymal sperm:** After treatment, rats were first sacrificed with ketamine (40 mg/kg) and xylazine (10 mg/kg), and then left epididymis was removed. The distal end of the epididymal tail was removed and placed in Petri dish containing 1 ml normal saline at 37 °C. Several incisions were made on the epididymis for better extraction, and incubated in 37 °C for 10 min. The cell suspension was prepared.

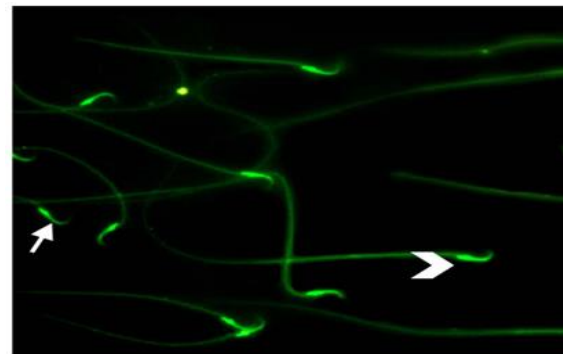
**Evaluation of sperm DNA methylation by immunocytochemistry technique:** After preparation of smears from cell suspension and fixation for 10 minutes in Carnoy's solution, they were washed with phosphate buffered saline (PBS) for 30 min with goat serum blocking solution and incubated at room

temperature. To remove the blocking solution, the smears were washed three times with PBS for 5 minutes each time. Then the smears were incubated at room temperature for two hours with monoclonal primary antibody (5-methylcytidine mouse antibody) from Acrise Co. To remove the primary antibody, the smears were washed three times with PBS and the slides were incubated with secondary antibody with fluorescein isothiocyanate (FITC) from Abcam Co. for 30 min at room temperature and in the dark. After washing with PBS, the samples were observed by fluorescence microscope. At least 200 sperms were detected for each sample at 400 x magnification and the percentage of sperms with DNA methylation was determined. The light green is related to DNA methylation in sperm, whereas sperms with dark green color do not have DNA methylation (6).

**Histological examination of the testis by Periodic acid-Schiff (PAS):** After sacrificing the rats and removing the left testis, the samples were placed in Bouin's fixative for one hour to prevent cellular changes. Passage of tissue was performed by an Autotechnichon tissue processor, and after embedding, 5 µm sections were obtained from the left testis using a microtome. For staining, the prepared sections were hydrated in descending alcohol solutions at concentrations of 90%, 80%, 70% (one minute for each concentration). The slides were then placed in periodic acid solution for five minutes at room temperature. After washing with running water, samples were immersed in Schiff's reagent at room temperature for 15 minutes and after washing with water for five minutes, they were immersed in hematoxylin solution for 90 minutes. The samples were dehydrated in ascending alcohol solutions at concentrations of 90%, 100%, 100% (3 seconds for each concentration). The slides were then placed in xylene solution for two minutes each time. After mounting the slides, photographs were taken using a light microscope at a magnification of 400 x. Counting of spermatogonial cells, primary spermatocytes, and Leydig cells (based on cell position, size and morphology), and measuring of internal and external diameter and epithelial thickness of the seminiferous tubule and basement membrane were done with at least five sections of seminiferous tubule using ImageJ software. Statistical analysis was performed using SPSS 22 software and Chicago Inc., IL. One-way ANOVA test was used to evaluate significant differences between groups and  $p < 0.05$  was considered significant.

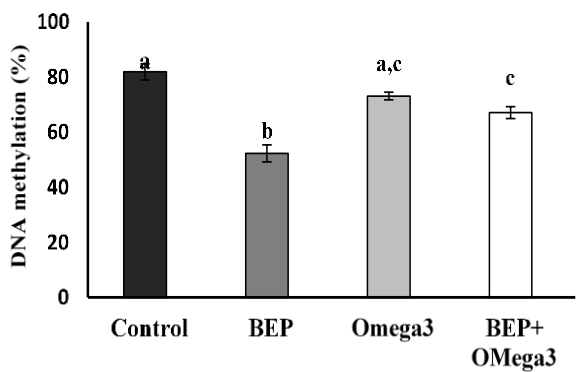
## Results

**Effect of omega-3 on sperm DNA methylation after treatment with BEP:** To determine the average percentage of sperm methylation, fluorescence microscopy images of sperm were evaluated; light green shows sperm DNA methylation and is considered positive, whereas dark green shows lack of DNA methylation and is considered negative (Fig 1). The mean percentage of sperm DNA methylation in the BEP-treated group ( $52.22 \pm 3.11$ ) was significantly decreased compared to the control group ( $81.8 \pm 2.92$ ) ( $p < 0.001$ ). However, after the use of omega-3 in the BEP-treated group, the mean percentage of sperm DNA methylation ( $67 \pm 2.18$ ) was significantly increased ( $p < 0.01$ ). In addition, the mean percentage of sperm DNA methylation in this group was lower than the control group and showed a significant difference compared to the control group ( $p < 0.01$ ). However, the mean percentage of sperm DNA methylation in the Omega-3 group ( $73 \pm 1.39$ ) was significantly different from the BEP group ( $p < 0.01$ ) but it was not significantly different from the control group (Fig 2).



**Figure 1.** A photomicrograph of sperm with DNA methylation; the chevron mark shows sperm DNA methylation in light green and the arrow mark shows lack of sperm DNA methylation in dark green. (400x Magnification) (100µm scale bar)

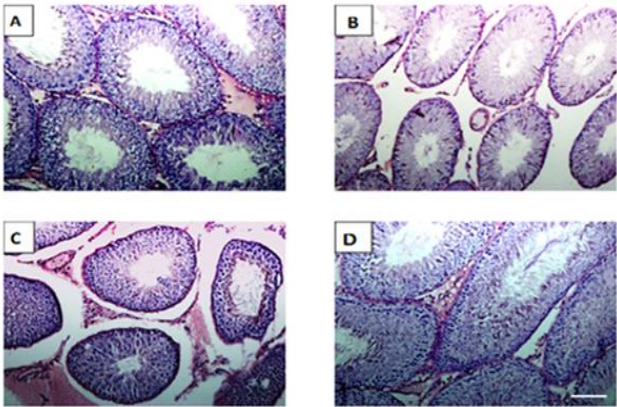
**The results of testicular tissue structure study:** After PAS staining using ImageJ software, sections prepared from testicular tissue were examined and inner and outer diameter of seminiferous tubule were measured and the thickness of germinal epithelium and basement membrane was calculated. Moreover, spermatogonial cells and primary spermatocytes were counted for each tubule. All these cells were counted using ImageJ software (Fig 3).



**Figure 2. Comparison of mean percentage of sperm DNA methylation in different groups. Data are shown as mean±standard deviation. Non-similar letters indicate significant difference (p<0.05).**

After treatment with BEP, the mean number of spermatogonial cells ( $44.95 \pm 1.56$ ), primary spermatocytes ( $47.60 \pm 1.45$ ), and Leydig cells ( $7.51 \pm 0.58$ ) showed a significant decrease compared to the control group ( $61.9 \pm 2.23$ ,  $66.20 \pm 2.16$  and  $18.40 \pm 1.24$ , respectively) ( $p < 0.001$ ). In addition, morphological changes were observed in seminiferous tubules such as disruption of tissue structure, and atrophy of seminiferous tubules while significant decrease was observed in epithelial thickness ( $145.5 \pm 5.64$ ) and basement membrane ( $7.07 \pm 0.29$ ) in seminiferous tubules compared to control group that were respectively  $377.4 \pm 9.52$  and  $12.48 \pm 0.62$  ( $p < 0.001$ ). In addition, in the BEP group treated with

omega-3, the mean spermatogonial cells ( $60.55 \pm 2.30$ ), primary spermatocytes ( $65.70 \pm 2.30$ ) and Leydig cells ( $21.50 \pm 1.19$ ), epithelial thickness ( $188.13 \pm 0.45$ ) and basement membrane ( $12.98 \pm 0.6$ ) in seminiferous tubules increased significantly compared to BEP group ( $p < 0.001$ ). In addition, in the omega-3 group, the mean spermatogonial cells ( $69.24 \pm 1.10$ ), primary spermatocytes ( $72.96 \pm 9.6$ ), epithelial thickness ( $302.5 \pm 13.05$ ) and basement membrane diameter ( $12.09 \pm 0.35$ ) in seminiferous tubules showed a significant increase compared to BEP+omega-3 group and BEP group ( $p < 0.05$ ), whereas no significant difference was observed compared with control group (Table 1).



**Figure 3. Micrographs of testis sections of testicular tissue and seminiferous tubules after PAS staining. Seminiferous tubules sections in control group (A), BEP group (B), Omega-3+BEP (C), and Omega-3 (D)**

**Table 1. The mean number of germ cells, epithelial thickness of the seminiferous tubule (ST) and basement membrane in different groups**

Group	Spermatogonia Mean±SD	Primary spermatocytes Mean±SD	Leydig cells Mean±SD	Thickness of ST epithelium (µm) Mean±SD	Thickness of the basement membrane of ST (nm) Mean±SD
Control	61.9±2.23 <sup>a</sup>	66.20±2.16 <sup>a</sup>	18.40±1.24 <sup>a</sup>	377.4±9.52 <sup>a</sup>	12.48±0.62 <sup>a</sup>
BEP	44.95±1.56 <sup>b</sup>	47.60±1.45 <sup>b</sup>	7.51±0.58 <sup>b</sup>	145.5±5.64 <sup>b</sup>	7.07±0.29 <sup>b</sup>
Omega-3	69.24±1.10 <sup>ac</sup>	72.96±9.6 <sup>ac</sup>	23.13±1.60 <sup>c</sup>	302.5±13.05 <sup>c</sup>	12.09±0.35 <sup>ac</sup>
Omega-3+BEP	60.55±2.30 <sup>ad</sup>	65.70±2.30 <sup>ad</sup>	21.50±1.09 <sup>ac</sup>	188.0±13.45 <sup>d</sup>	12.98±0.6 <sup>ac</sup>

Non-similar letters indicate significant difference at  $p < 0.05$

**Discussion**

The results of this study showed that sperm DNA methylation decreased after treatment with BEP compared to control group, but sperm DNA methylation significantly increased after using omega-3 compared to BEP group. Evaluation of tissue sections in this study showed that in the BEP-treated group, the number of germ cells and Leydig cells as well as the epithelial

thickness of basement membrane of seminiferous tubules decreased but it improved after treatment with omega-3. Examination of epigenetic changes in sperm DNA following testicular cancer treatment revealed that DNA methylation pattern changed. The level of DNA methylation changed in most of the affected genes (10). By examining the effects of BEP drugs on rats, it was found that these drugs increase sperm DNA

fragmentation and alter sperm chromatin integrity, which may lead to infertility (7). It has recently been shown that BEP destroys germ cells that form seminiferous tubules and the use of antioxidants improves these changes (13). In addition, omega-3 can protect the chromatin structure against the deleterious effects of BEP (6). Moreover, in the analysis of tissue sections in this study, it was found that in the BEP-treated group, the number of germ cells and the thickness of the epithelium and basement membrane of the seminiferous tubules decreased, but they were recovered after treatment with omega-3. In this regard, a previous study confirms the protective effect of omega-3 on testicular tissue structure against doxorubicin, which causes testicular tissue disruption and reduces germ cells (11).

The results of this study were consistent with the present study and showed that in the BEP-treated group the number of germ cells, Leydig cells as well as the thickness of the epithelium and basement membrane decreased, but it improved after treatment with omega-3. Cisplatin alone has been shown to cause destructive histopathologic changes in testicular tissue and to cause tissue disruption, vacuolization, and degeneration of the germinal epithelium and these injuries improve during

antioxidant use (14). BEP also had deleterious effects on the surface of the seminiferous tubules and some of these adverse effects were eliminated with the use of omega-3. Consistent with the findings of this study, a decrease in the number of seminiferous tubules, spermatogonial cells and primary spermatocytes has been observed after treatment with BEP drugs (15). In addition, in 2011, the effects of BEP chemotherapy drugs on spermatogonial cells of rat were reported to cause oxidative stress and lead to the destruction of spermatogonial cells (16), which is consistent with the findings of this study.

Overall, it can be concluded that omega-3 can improve the cytotoxic effects of BEP on DNA methylation and histological structure of seminiferous tubules. Patients treated with chemotherapy agents are recommended to use omega-3 to improve the cytotoxic effects of chemotherapy drugs.

### Acknowledgment

Hereby, we would like to thank the Deputy of Research and Technology of Isfahan University of Medical Sciences for the financial support of this research.



## References

1. Hervieu A, Rébé C, Végran F, Chalmin F, Bruchard M, Vabres P, et al. Dacarbazine-mediated upregulation of NKG2D ligands on tumor cells activates NK and CD8 T cells and restrains melanoma growth. *J Invest Dermatol.* 2013;133(2):499-508.
2. Menna P, Salvatorelli E, Minotti G. Anthracycline degradation in cardiomyocytes: a journey to oxidative survival. *Chem Res Toxicol.* 2009;23(1):6-10.
3. Sikka SC. Andrology lab corner: Role of oxidative stress and antioxidants in andrology and assisted reproductive technology. *J Androl.* 2004;25(1):5-18.
4. Akbari A, Jelodar GA. The effect of oxidative stress and antioxidants on men fertility. *Zahedan J Res Med Sci.* 2013; 15(7):e92918.
5. Dasdag S, Ketani M, Akdag Z, Ersay A, Sari I, Demirtas Ö, et al. Whole-body microwave exposure emitted by cellular phones and testicular function of rats. *Urol Res.* 1999;27(3):219-23.
6. Hashemi F, Razavi S, Khadivi F. The protective effects of omega3 on ubiquitination and protamination of rat sperm after bleomycin, etoposide, and cisplatin treatment. *Nutr Cancer.* 2018; 70(8):1308-14.
7. Delbes G, Hales BF, Robaire B. Effects of the chemotherapy cocktail used to treat testicular cancer on sperm chromatin integrity. *J Androl.* 2007;28(2):241-9.
8. Henkel R, Hajimohammad M, Stalf T, Hoogendijk C, Mehnert C, Menkveld R, et al. Influence of deoxyribonucleic acid damage on fertilization and pregnancy. *Fertil Steril.* 2004;81(4):965-72.
9. Oakes C, La Salle S, Smiraglia D, Robaire B, Trasler J. Developmental acquisition of genome-wide DNA methylation occurs prior to meiosis in male germ cells. *Dev Biol.* 2007;307(2):368-79.
10. Chan D, Delbès G, Landry M, Robaire B, Trasler JM. Epigenetic alterations in sperm DNA associated with testicular cancer treatment. *Toxicol Sci.* 2011;125(2):532-43.
11. Uygur R, Aktas C, Tulubas F, Uygur E, Kanter M, Erboğa M, et al. Protective effects of fish omega-3 fatty acids on doxorubicin-induced testicular apoptosis and oxidative damage in rats. *Andrologia.* 2014;46(8):917-26.
12. Bas O, Songur A, Sahin O, Mollaoglu H, Ozen OA, Yaman M, et al. The protective effect of fish n-3 fatty acids on cerebral ischemia in rat hippocampus. *Neurochem Int.* 2007;50(3):548-54.
13. Razavi S, Khadivi F, Hashemi F, Bakhtiari A. Effect of Zinc on Spermatogenesis and Sperm Chromatin Condensation in Bleomycin, Etoposide, Cisplatin Treated Rats. *Cell J.* 2019;20(4):521-6.
14. Heeba GH, Hamza AA, Hassanin SO. Induction of heme oxygenase-1 with hemin alleviates cisplatin-induced reproductive toxicity in male rats and enhances its cytotoxicity in prostate cancer cell line. *Toxicol Lett.* 2016;264:38-50.
15. Ghezzi M, Berretta M, Bottacin A, Palego P, Sartini B, Cosci I, et al. Impact of BEP or carboplatin chemotherapy on testicular function and sperm nucleus of subjects with testicular germ cell tumor. *Front Pharmacol.* 2016;7:122.
16. Coşkun N, Hatipoğlu MT, Özoğul C, Korkmaz C, Akyol SN, Mıcılı SC, et al. The protective effects of Acetyl L-Carnitine on testis gonadotoxicity induced by Cisplatin in rats. *Balkan Med J.* 2013;30(2):235-41.