

A Case Report of Primary Angiitis of the Central Nervous System

A.M. Soleymani Joniyani (MD)¹, P. Saadat (MD)^{*2}

1.Student Research Committee, Babol University of Medical Sciences, Babol, I.R.Iran

2.Mobility Impairment Research Center, Health Research Institute, Babol University of Medical Sciences, Babol, I.R.Iran

J Babol Univ Med Sci; 20(11); Nov 2018; PP: 67-73

Received: Apr 19th 2018, Revised: Aug 5th 2018, Accepted: Aug 26th 2018.

ABSTRACT

BACKGROUND AND OBJECTIVE: Primary angiitis of the central nervous system (PACNS) is an inflammatory vasculitis with very low frequency and prevalence. It is not clear why the inflammatory process of this disease is limited to cerebrovascular disease without systemic manifestations. A case of primary angiitis of the central nervous system with cerebrovascular manifestations is reported here.

CASE REPORT: The patient is a 50-year-old woman with headache, nausea, vomiting, and visual symptoms without clear motor impairment. Normocytic normochromic anemias tests and function tests of kidney, liver and thyroid and serology of infectious diseases were reported to be normal. The patient underwent brain imaging, and due to multiple lesions in both cerebral hemispheres and cerebellum, she underwent biopsy with a probable diagnosis of cerebral vasculitis. After histopathologic confirmation, the patient was discharged with glucocorticoid and cyclophosphamide therapy, and the symptoms subsided after one year follow-up.

CONCLUSION: Based on the results of this case report, some general and common symptoms of the primary angiitis of the central nervous system should also be considered.

KEYWORDS: *Primary Angiitis of the Central Nervous System (Pacns), Cytotoxic, Glucocorticoids.*

Please cite this article as follows:

Soleymani Jouniani AM, Saadat P. A Case Report of Primary Angiitis of the Central Nervous System. J Babol Univ Med Sci. 2018;20(11):68-73.

***Corresponding Author:** P. Saadat (MD)

Address: Clinical Research Development Unite of Rouhani Hospital, Babol University of Medical Sciences, Babol, I.R.Iran.

Tel: +98 11 3223 8301

E-mail: sepanta1968@yahoo.com

Introduction

PPrimary angiitis of the central nervous system (PACNS) is a rare vasculitis that affects the parenchyma of the brain and spinal cord, arteries and meningeal veins, and leads to inflammation and destruction of the vessels at this level, without any inflammation outside the central nervous system. Lymphocytic vasculitis is one of the PACNS variants with relatively lower prevalence (1–5).

Its annual incidence rate is reported to be 2.4 per one million people (2). Pathogenesis, diagnosis and treatment of this disease is very challenging due to very low rates of the disease (3, 5). The cause of the disease is still unclear, but viral infection and association with lymphoma are suggested, and if this disease is left untreated, the patient may experience loss of consciousness or even brain death (1, 4). PACNS is usually diagnosed based on radiological, pathological, and immunohistochemistry findings (5). However, there is no accepted universal diagnostic criteria for a definitive diagnosis. There are no specific imaging findings for the diagnosis as criteria. Overall progress in the diagnosis of neurological disorders has led to invasive diagnostic approach, clinical description and pathological description (7, 8).

Histologically speaking, the inflammatory process usually affects the small and medium arteries, and meninges and cortex, and rarely on venules and veins through lymphocytic infiltration. The classic findings of segmental granulomatous vasculitis with multinucleated giant cells occur in less than 50% of patients. Necrotic vasculitis occurs in 25% of patients. The presence of fibrosis at the site of the previous lesions is usually a sign of recovery of the lesions (5).

There are a variety of clinical symptoms associated with different imaging modalities and angiography for diagnosis. Due to similar constitutional symptoms and numerous differential diagnoses, high clinical suspicion in diagnosing the disease is very helpful and a correct diagnosis should be reached by considering all symptoms and rejecting other causes of the disease. PACNS vasculitis often occurs in men with an average age of 50 years. Men are usually twice as likely as women to develop this disease. The symptoms of

PACNS at ages below 30 years and over 70 years make it difficult to diagnose the disease (4). The purpose of this case report is to be aware of the general and varied symptoms of the disease, and at the same time to differentially compare it with other diagnoses to reach quick diagnosis and treatment of the patient.

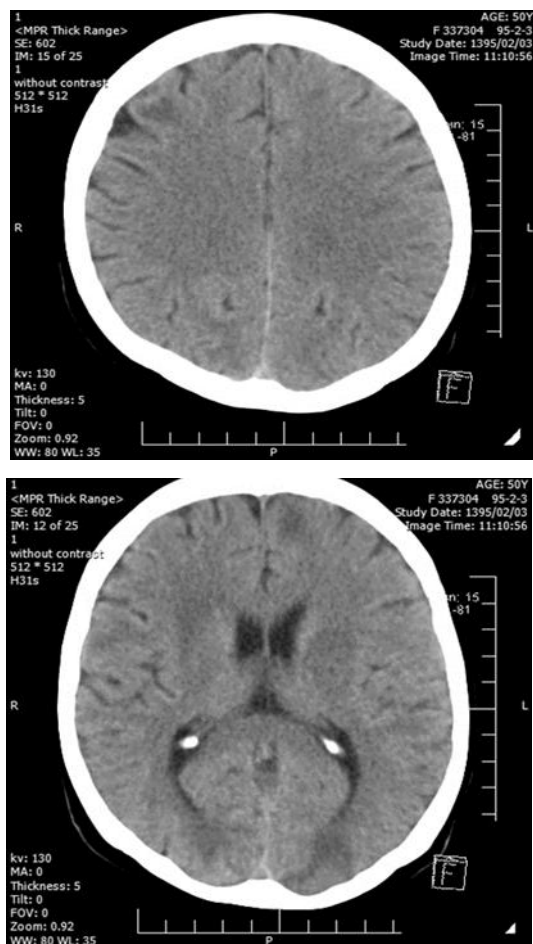
Case report

A 50 – year – old woman, who was a housewife, married and had three children referred with complaint of constant throbbing and bilateral headache in the frontotemporal area for six weeks, lasting one to two hours a day, and exacerbated with coldness and noise. The patient's headache was accompanied by photophobia, nausea and vomiting, and did not spontaneously recover without the use of sedatives. The patient has no complaints of weight loss, sensory impairment and sphincter disturbance. Her child complains about the patient's unawareness of the time and place and memory impairment.

In the medical history, there is a history of early onset seizure at the age of eight, and according to the patient, she was treated with Depakine for one to two months, and no seizures occurred after discontinuing drug treatments. The patient's recent travel does not show the use of non-pasteurized milk and other dairy products. The patient also did not have atherosclerosis risk factors, such as smoking, hyperlipidemia, hypertension, and diabetes mellitus. In the neurological examination, the patient was completely alert, awake and aware.

The examination of the cranial nerves and sensory examination were all normal. In the examination of motor system, the limb muscle strength was 4.5 and deep reflexes were 3+. Bilateral Babinski's reflex was abnormal. Other physical examinations were normal. In the initial assessment, the function tests of liver, kidney, and thyroid, coagulation tests and electrolyte levels, CXR and EEG were normal. After performing the spiral CT scan (Fig. 1), due to the presence of several hypodense lesions in different sections, we decided to perform MRI (Fig. 2). In MRI with and without

injection of contrast medium, multiple intra – axial lesions with nodular and diffuse contrast were observed similar to CT scan results (Fig. 2).



**Figure 1. Spiral CT Scan before treatment
(multiple hypodense lesions)**

Considering the above findings, infectious diseases such as tuberculosis, septic embolism, endocarditis, fungal infections such as coccidiosis and cryptococcus along with malignancies such as neurological tumors and lymphoma, and rheumatologic diseases such as vasculitis, SLE, APS, and Sjogren's syndrome were proposed, and they were rejected one by one based on diagnostic priorities and possibilities to reach the main diagnosis. PPD, blood culture, CSF culture and TB PCR were negative (based on aerobic and anaerobic bacterial culture).

In CSF analysis, Pr: 20, Glu: 50, RBC: 2500, and WBC: 80 (PMN: 85%, Lym: 15%), the serology of HIV, CMV, Toxo and hepatitis were also negative. Echocardiography was performed several times, which

was negative and valvular vegetation was not observed. Concurrent with evaluating infectious diseases, measures were taken to find the source of potential metastasis of unknown origin:

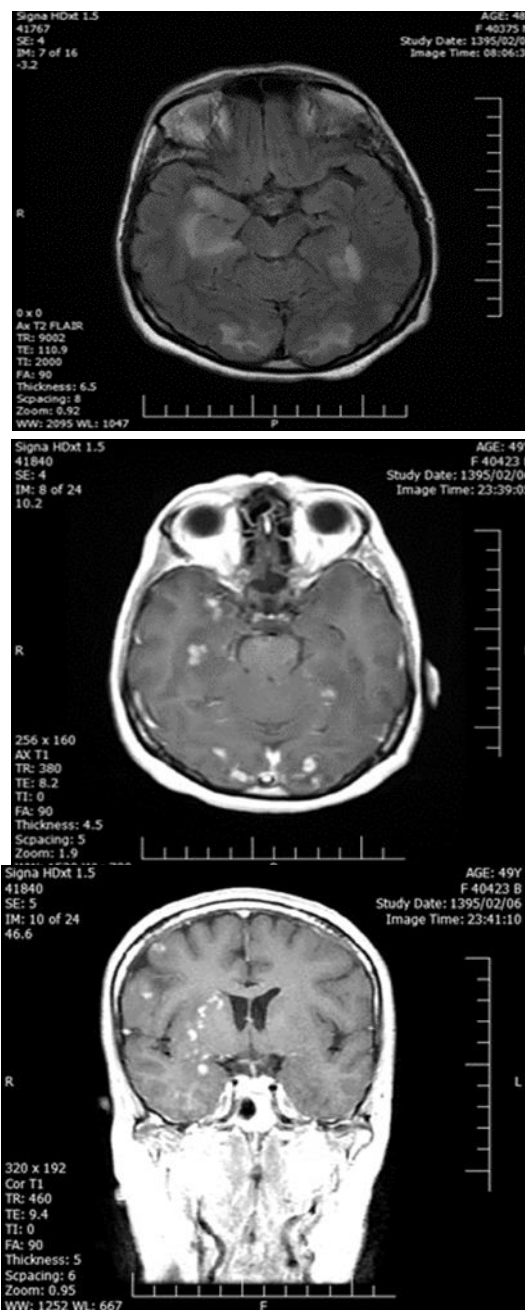


Figure 2. After the injection of contrast medium, multiple enhanced lesions were dispersedly detected in both cerebral hemispheres and cerebellum that could be explained by multiple metastatic lesions.

Complete abdominal and pelvic ultrasonography with tumor markers was performed to examine internal organs such as the liver and ovary, which was negative

(CEA, CA15-3, CA-125, CA19-9, AFP). Spiral CT scan was performed on the chest, abdomen and pelvis with and without contrast, which had no pathologic findings. Mammography did not show any lesion.

In the case of rheumatologic studies, all serologies was negative: RF, Anti CCP, ANA, Anti ds DNA, ACEI, Anti RO, Anti LA, Anti Cardiolipin Ab, Anti Coagulan Ab, C3, C4, CH50, P ANCA, C ANCA. Finally, two weeks after the diagnostic measures and failure in detecting the origin of multiple brain lesions, stereotactic biopsy was performed at the surgery center of Shohadaye Tajrish Hospital, and the yellow tissue containing necrosis and gelatinous fluid was transferred to the pathology center.

Microscopic biopsy showed perivascular lymphocytic infiltration and chronic intraparenchymal inflammation, in which the vascular wall was destroyed by T cells. In IHC tests, positive markers of CD3, CD5

(Tcell) and CD20 (Bcell) were observed. Based on the results of biopsy, the absence of systemic symptoms and the laboratory results, primary angiitis of the central nervous system (PACNS) was confirmed for the patient. The patient was treated with 1 g methylprednisolone per day for three days and 1 g cyclophosphamide per month for six months. After induction therapy, the patient was treated with 50 mg prednisolone per day, which gradually decreased to 12.5 mg within six months. A daily dose of 300 mg phenytoin was also prescribed to prevent seizures. One year after the treatment, MR spectroscopy was performed for the patient, and regression of subcortical lesions with less dispersion could clearly be observed.

Anyway, our patient was treated with prednisolone and cyclophosphamide, and after one year of follow up, the symptoms completely subsided and the patient recovered completely.

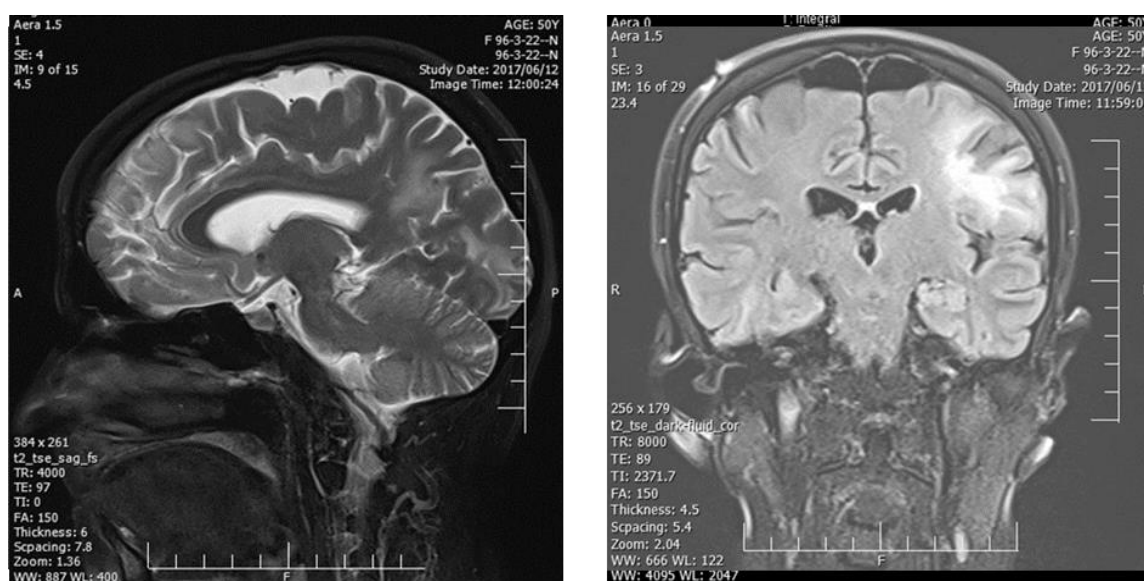


Figure 3. MRS of the brain shows the axial T1, T2, and FLAIR, without contrast.

Multifocal nodular leptomeningeal lesions with enhancement were observed in MRI before and after contrast. The major peaks of the H-MRS spectrum, corresponding to N-acetylaspartate (NAA) (2), creatinine (Cr) (3), and choline (Cho) (2, 3) are visible in the figure. In MVS-135 in the lesion: there is no clear change in the peak of serum levels of NAA, creatinine and choline levels. Choline to NAA ratio = 0.45, choline to creatinine ratio = 0.75.

Discussion

In this report, a 50-year-old woman with PACNS was introduced. In a study by Lyra et al., a 28-year-old man with PACNS was introduced (9). Restrepo et

al. introduced three PACNS patients, two men aged 54 and 35, and a 55-year-old woman (10). Our report also confirms the incidence in middle age, but the

gender of our patient was not consistent with higher prevalence in male gender. Most PACNS reports are from Europe and North America (15).

Restrepo et al. (10) in 2013 reported three PACNS cases from Columbia, including two men and one middle aged woman, which is probably the first case reported in South America. In Asia, there is no compiled report of the geographical dispersion of the disease. Infections (varicella zoster virus, HIV virus, and Hepatitis C virus) are associated with vascular disorders of the brain and need to be rejected by serological tests (12, 13). Pulmonary tuberculosis is one of the most important differential diagnoses of PACNS. No laboratory test has sufficient sensitivity or specificity to detect PACNS, and clinical suspicion is essential for early diagnosis. Brain biopsy is necessary to confirm the diagnosis and prevent other causes.

According to published studies, the estimated sensitivity of cerebral angiography for detecting vasculitis is 27 – 90% and is 36 – 83% for brain biopsy (7, 8). Common symptoms of PACNS are headache and encephalopathy caused by cortical dysfunction. The prevalence of headache is 63%, which is usually not severe enough to necessitate the evaluation of SAH (subdural hematoma) (16).

Similarly, cognitive impairment in PACNS is fatal and slow, and acute changes in consciousness levels are uncommon. Non – specific symptoms of PACNS, such as headache and cognitive impairment progress slowly, prolonging the onset of symptoms until diagnosis (about six months), which was the same in our patient.

Stroke and permanent neurological deficit are observed in 40% of cases and transient ischemic attack (TIA) is observed in 30 – 50% of cases, which was not observed in our patient. However, Crane et al. reported an incidence of less than 20% for TIA and neurological deficit at the onset of disease (17).

In a study by Molloy et al., nausea and diplopia were reported along with the presence of a mass in the brain and after the biopsy and confirming CNS vasculitis, treatment with glucocorticoid and cytotoxic fulfilled the need for surgery (18).

Although PACNS is small-vessel vasculitis, due to the higher prevalence of the symptoms of large-vessel

vasculitis such as aphasia (28%) and visual field defects (21%), these symptoms may be more prominent than others at the onset of the disease (4). In the patient of our report, there was no aphasia and visual field defects. In the study of Calabrese et al. (19), as reported by Salvarani et al. (4) and Vollmer et al. (20), the incidence of seizure was about 25%, however, there was no seizure in our patient. Signs and symptoms of systemic inflammation in the body are lower in PACNS compared with other primary vasculitis. Salvarani et al. (4) and Vollmer et al. (20) reported fever, sweating, weight loss, and high ESR in 20% of cases, which was again not present in our patient. In the study of Birnbaum et al. (8), there were abnormal findings in CSF analysis and Brain MRI imaging in PACNS patients, but due to non-specificity, parenchymal lesions biopsy was the best option for definitive diagnosis. Similar to our case, Birnbaum et al. (8), Restrepo et al. (10) and most PACNS experts treated patients through the induction of 1 g methylprednisolone for three days and then maintenance therapy with prednisolone and Endoxan. MRI is the primary method for diagnosing patients with suspected PACNS, and in general, a combination of normal findings in MRI, and normal CSF analysis has high negative predictive value for PACNS diagnosis (10).

A common mistake in detecting CNS vasculitis is initiating an immunosuppressive therapy, without definitive diagnosis or rejecting other diseases. In our patient, after clinical suspicion and before treatment, due to serious complications of the treatment, definitive diagnosis was confirmed by stereotactic brain biopsy, and then the treatment with corticosteroid and Endoxan was performed. The efficacy of most immunosuppressive agents, such as azathioprine, methotrexate, and rituximab, used in systemic vasculitis, are still unknown in PACNS (11).

The vast majority of cases that are treated in patients with glucocorticoid or glucocorticoid with cyclophosphamide show very good results. However, there are reports indicating that the combination of mycophenolate mofetil and glucocorticoid can be used to control the disease by eliminating neurological disorders, restoration of normal daily activities, and

improving brain disorders dramatically (14). Sometimes, common constitutional symptoms of a disease indicate important and dangerous diseases such as vasculitis, and with the slightest negligence for timely diagnosis and treatment, it may lead to irreparable lesions and even death. Therefore, considering PACNS when facing a series of general and

constitutional symptoms such as headache may help diagnose the disease.

Acknowledgment

Hereby, we would like to thank Dr. Masood Shekarchizadeh for his cooperation with this research.

References

1. Panchal NJ, Niku S, Imbesi SG. Lymphocytic vasculitis mimicking aggressive multifocal cerebral neoplasm: MR imaging and MR spectroscopic appearance. *AJNR Am J Neuroradiol*. 2005; 26(3): 642-5.
2. Kraemer M, Berlit P. Primary central nervous system vasculitis: clinical experiences with 21 new European cases. *Rheumatol Int*. 2011;31(4):463-72.
3. Qu SB, Khan S, Liu H. Primary central nervous system vasculitis mimicking brain tumour: case report and literature review. *Rheumatol Int*. 2009; 30(1): 127-34.
4. Salvarani C, Brown RD Jr, Calamia KT, Christianson TJ, Weigand SD, Miller DV, et al. Primary central nervous system vasculitis: analysis of 101 patients. *Ann Neurol*. 2007;62(5):442-51.
5. Volcy M, Toro ME, Uribe CS, Toro G. Primary angiitis of the central nervous system: report of five biopsy-confirmed cases from Colombia. *J Neurol Sci*. 2004;227(1):85-9.
6. Myung J, Kim B, Yoon BW, Lee SK, Sung JJ, Chung CK, et al. B-cell dominant lymphocytic primary angiitis of the central nervous system: four biopsy-proven cases. *Neuropathology*. 2010;30(2):123-30.
7. Hajj-Ali RA, Singhal AB, Benseler S, Molloy E, Calabrese LH. Primary angiitis of the CNS. *Lancet Neurol*. 2011;10(6):561-72.
8. Birnbaum J, Hellmann DB. Primary angiitis of the central nervous system. *Arch Neurol*. 2009;66(6):704-9.
9. Lyra TG, Martin MG, do Carmo Carvalho RC, Rodrigo & Regina Gomes Cardim Mendes Oliveira C, Filipe de Souza Godoy L, de Sousa Delgado D, Guido Cerri G, Leite C. Pseudotumoral presentation of primary central nervous system vasculitis: case report and literature review. *Arquivos de neuro-psiquiatria*. 2013;71(5):333-335.
10. Coronel-Restrepo N, Bonilla-Abadía F, Cortes OA, Izquierdo JH, Shinchí AM, et al. Primary Angiitis of the Central Nervous System: A Report of Three Cases from a Single Colombian Center. *Neurolog Med*. 2013; 2013:Article ID 940438.
11. Amara AW, Bashir K, Palmer CA, Walker HC. Challenges in diagnosis of isolated central nervous system vasculitis. *Brain Behav*. 2011;1(1):57-61.
12. Cañas CA, Jiménez C, Arango G, Ricaurte O, Toro G, Peña M, et al. Compromiso vascular en la encefalitis herpética. *Rev Fac Med*. 1997; 45(1):16-20.
13. Cañas CA, Cedeño SV, Carrascal E, Vélez JD. Diátesis trombótica en paciente con infección aguda por cytomegalovirus. *Acta Médica Colombiana*. 2009; 34(3): 136-9.
14. Chenevier F¹, Renoux C, Marignier R, Durand-Dubief F, Hermier M, Streichenberger N, et al. Primary angiitis of the central nervous system: response to mycophenolate mofetil. *J Neurol Neurosurg Psychiatry*. 2009;80(10):1159-61.
15. Cañas CA¹, Jiménez CA, Ramírez LA, Uribe O, Tobón I, Torrenegra A, et al. Takayasu arteritis in Colombia. *Int J Cardiol*. 1998;66 Suppl 1:S73-9.
16. Moore PM. Diagnosis and management of isolated angiitis of the central nervous system. *Neurology*. 1989; 39(2 Pt 1):167-73.
17. Crane R, Kerr LD, Spiera H. Clinical analysis of isolated angiitis of the central nervous system: a report of 11 cases. *Arch Intern Med*. 1991;151(11):2290-2294.
18. Molloy ES, Singhal AB, Calabrese LH. Tumour-like mass lesion: an under-recognised presentation of primary angiitis of the central nervous system. *Ann Rheum Dis*. 2008;67(12):1732-5.
19. Calabrese LH, Mallek JA. Primary angiitis of the central nervous system: report of 8 new cases, review of the literature, and proposal for diagnostic criteria. *Medicine (Baltimore)*. 1988;67(1):20-39.
20. Vollmer TL, Guarnaccia J, Harrington W, Pacia SV, Petroff OA. Idiopathic granulomatous angiitis of the central nervous system: diagnostic challenges. *Arch Neurol*. 1993;50(9):925-30.