

The comparison of N-acetylcysteine and Vitamin D on oxidative Liver Toxicity in Sub-Acute Paraquat Poisoning

Gh. Rahmani (Pharm,D)¹, S. Soleimani Asl (PhD)², A. Nili Ahmadabadi (PhD)³,
A. Larki (PhD)⁴, A. Ranjbar (PhD)^{4*}

1.Student Research Committee, Hamadan University of Medical Sciences, Hamadan, I.R.Iran

2.Department of Anatomy, Faculty of Medicine, Hamadan University of Medical Sciences, Hamadan, I.R.Iran

3.Department of Pharmacology-Toxicology, Faculty of Pharmacy, Hamadan University of Medical Sciences, Hamadan, I.R.Iran

4.Medicinal Plants and Natural Products Research Center, Hamadan University of Medical Sciences, Hamadan, I.R.Iran

J Babol Univ Med Sci; 20(7); July 2018; PP: 14-20

Received: Jan 21st 2018, Revised: Mar 19th 2018, Accepted: May 9th 2018.

ABSTRACT

BACKGROUND AND OBJECTIVE: Paraquat is mainly used as an herbicide and its toxicity can be caused by acute and chronic liver disease by increasing the active oxygen species, in this study, we investigated the effect of N-acetyl cysteine and vitamin D on the oxidative toxicity of Liver tissue in sub-acute toxicity with paraquat.

METHODS: In this experimental study, 36 male albino Wistar 8 weeks old were randomly divided into 6 groups: 1) control group; 2, 3) control animals received intraperitoneal injection of Vit D 2 µg/kg/day or NAC 6.25 mg/kg/day (IP); 4) received paraquat 5 mg/kg/day (IP); 5 and 6) received paraquat and treated with Vit D 2 µg/kg/day or NAC 6.25 mg/kg/day for 7 days. At the end of the study, serum and liver tissue were collected. Total antioxidant capacity (TAC), lipid peroxidation (LPO), total thiol groups (TTG), ALT and AST levels in liver tissue were evaluated. Also liver histopathological evaluation was performed.

FINDING: Based on the results, in paraquat-poisoned groups compared to the healthy control group, the LPO was increased by 239.83 ± 70.87 versus the control group 123.1 ± 16.63 and the liver enzymes were increased. TAC in paraquat-poisoned groups was 68.66 ± 23.41 that showed a significant decrease compared to the control group 126.50 ± 18.25 . Also, TTG in paraquat-poisoned groups was 40.50 ± 5.95 that significantly decreased compared to control group ($P < 0.05$). Moreover, LPO was significantly reduced in vitamin-treated groups 156.33 ± 39.40 compared to the paraquat-poisoned group of 239.83 ± 70.87 . In addition, histopathologic findings showed that vitamin D could improve the tissue damage caused by paraquat in the liver.

CONCLUSION: The results of this study indicated that Vit D and NAC decreased oxidative toxic stress, and tissue damage in the Liver caused by paraquat poisoning.

KEY WORDS: *N-Acetylcysteine, Paraquat, Liver, Vitamin D.*

Please cite this article as follows:

Rahmani Gh, Soleimani Asl S, Nili Ahmadabadi A, Larki A, Ranjbar A. The comparison of N-acetylcysteine and Vitamin D on oxidative Liver Toxicity in Sub-Acute Paraquat Poisoning. J Babol Univ Med Sci. 2018;20(7):14-20.

*Corresponding Author: A. Ranjbar (PhD)

Address: Medicinal Plants and Natural Products Research Center, Hamadan University of Medical Sciences, Hamadan, I.R.Iran

Tel: +98 81 38381591

E-mail: akranjbar2015@gmail.com

Introduction

Paraquat (1 and 1 di-methyl 4 and 4-bipyridium dichloride) is mainly used as a herbicide. Paraquat in humans accumulates in all organs of the body and especially in the lungs as a selective member after oral intake due to its high distribution volume. The toxicity of paraquat is related to the mitochondrial oxidation and regeneration system. Paraquat can produce high levels of reactive oxygen species (ROS) such as hydrogen peroxide and superoxide anion. ROS are atoms or molecules that lead to oxidative damage of macromolecules of the body, such as proteins, lipids, carbohydrates, and DNA (1,2). Paraquat can be resulted in acute and chronic liver disease, which severely affects non-specific changes in the liver structure to acute liver failure, cirrhosis, and liver cancer (3). None of the paraquat antidotes including corticosteroids, immunosuppressive agents, fibrinolytic agents, and radiotherapy have not been fully clinically effective (4). N-acetylcysteine (NAC) is known as an antidote for acetaminophen poisoning, but it has other clinical applications that are scientifically supported. Based on animal and human studies, NAC is one of the first lines of treatment for paraquat poisoning. NAC supplementation appears to increase glutathione, suppress NF- κ B activity, and thus reduce oxidative stress (5). Vitamin D (Vit D) or calciferol is a fat-soluble vitamin. Studies have shown that vitamin D alone is not involved in maintaining normal levels of calcium in the body. One of the newly studied effects of vit D is the antioxidant action of this substance. It has been shown that vitamin D deficiency is associated with many diseases, including diabetes(6), cardiovascular disease, autoimmune diseases, and chronic kidney disease by altering the oxidant/antioxidant system(1). Administration of vitamin D decreases lipid peroxidation and improves superoxide disodase (SOD) enzyme activity in mice. Also, vitamin D can reduce the active oxygen species, this mechanism is done by methods such as enhancing the content of GSH, enhancing the expression of glutamate-cysteine ligase genes (an enzyme involved in glutathione synthesis) and glutathione reductase (7,8). Considering the high mortality rate with poison and also the agricultural

boom in different parts of the country, and the high rates of accidental and deliberate poisoning due to this poison and the lack of definitive treatment for this poison, comprehensive and targeted research to discover effective treatment for Paraquat poisoning are needed. The purpose of this study was to compare the effect of Vit D on subacute liver poisoning with paraquat compared to NAC, may have beneficial effects on the reduction of liver toxicity due to poisoning and reduce the mortality due to this poisoning.

Methods

In this experimental study, after approval by the Ethics Committee of Hamedan University of Medical Sciences with code IR.UMSHA.REC.1395. 205, 36 male Wistar rats weighing 180-250 g were used. Animals were kept in animal house condition with water and food, and had 12 hours of light and 12 hours of darkness. Animals were randomly divided into 6 groups of 6.

1. Healthy control group (C)
2. The control group treated with NAC at 6.2 mg/kg/day for 7 days by intraperitoneal injection (IP) (C+NAC) (9)
3. The control group treated with Vit D at a dose of 2 μ g/kg/day for 7 days (IP) (C+Vit D) (10)
4. A poisoned group with paraquat with a dose of 5 mg/kg/day for 7 days (IP) (P) (11)
5. A poisoned group with paraquat at a dose of 5 mg/kg/day treated with 6.25 mg/kg/day for 7 days (P+NAC)
6. A poisoned group with paraquat at a dose of 5 mg/kg/day treated with Vit D at a dose of 2 μ g/kg/day for 7 days (P+Vit D)

At the end of the treatment period, rats were anesthetized with intraperitoneal injection of ketamine (50 mg/kg) and liver samples were stored at -80 C. In addition, some liver tissue was maintained in 10% formalin for histopathological studies. Serum samples were also isolated and maintained to measure the activity of liver enzymes. To measure oxidative stress markers in liver tissue, total protein values were measured by Bradford method. In the following, for the examination of lipid peroxidation, the tiobarbituric acid

(TBA) method was used, the maximum absorption of the TBA + MDA pink complex was read at 532 nm wavelength (12).

To assess the total antioxidant capacity of the serum, FRAP (Ferric Reducing Ability of Plasma) was used which FRAP reagent containing 4 2,4,6-Tripyridyl-S-Triazine (TPTZ 6,4,2) was added to samples and the maximum absorption of the blue complex + TPTZ + Fe²⁺ was read at 593 nm wavelength (13), thiol groups were also evaluated as another indicator of oxidative stress. Thiol groups are sensitive to oxidative damage, and its reduction is an important sign of oxidative stress. To measure these factors, the Hu colorimetric method using DTNB (2 and 2 di-nitrobenzoic acid, Ellman reagent) was used. Therefore, the maximum absorption was read at 412 nm (14). Vit D levels were also assessed by ELISA kit based on the kit protocol. Serum ALT and AST levels were also measured with Pars Azmoon company kit.

Histopathologic studies were performed after removing the liver from the abdomen and washing with cold saline buffer, fixed with 10% formalin. After the tissue processing and preparation of paraffin blocks and 5 µm sections, the sections were stained with Hematoxylin and Eosin. Then, using a light microscope and using the Motic Advance Plus 2 software, photos were taken from the tissue, and the shape of the liver cells (hepatocytes), core shift to the environment, cell vacuolization, nucleolar nucleation, sinusoidal dilatation and cell infiltration were studied. For statistical analysis, SPSS software version 16 was used and ANOVA and Tukey post hoc test were used and $p < 0.05$ was considered significant.

Results

The amount of lipid peroxidation in the liver tissue in the poisoned group with paraquat (239.70 ± 83.87) was significantly higher than the control group (123.16 ± 00.63) ($p < 0.01$). Treatments with NAC (171.44 ± 00.077) and Vit D (156.39 ± 33.40) ($p < 0.05$) improved lipid peroxidation of liver tissue than the poisoned group. In addition, total antioxidant capacity in the paraquat-poisoned group (68.23 ± 66.41) had a

significant reduction compared to the control group (126.18 ± 50.25) ($p < 0.05$). Treatment with Vit D (103.12 ± 16.18) and NAC (111.18 ± 66.64) did not significantly improve the total antioxidant capacity compared to the poisoned group. In addition, the levels of thiol (TTG) in the liver tissue in the poisoned group with paraquat (40.50 ± 55.95) had a significant decrease compared to the healthy control group (79.10 ± 50.52) ($p < 0.01$).

Treatment with NAC (69.10 ± 37.38) and Vit D (63.9 ± 66.28) significantly increased the number of thiol groups compared to the poisoned group ($p < 0.05$) (Fig 1). Serum levels of ALT in the poisoned group with paraquat (136.17 ± 00.98) had a significant increase compared to the healthy control group (46.7 ± 83.33) ($p < 0.01$). Treatment with Vit D (109.17 ± 50.16) resulted in an improvement in ALT compared to the poisoned group ($p < 0.05$). The serum AST level in the paraquat-poisoned group (215.28 ± 50.89) had a significant increase compared to the control group (85.10 ± 33.30) ($p < 0.01$). Treatment with NAC (140.32 ± 16.50) and VitD (152.10 ± 16.75) resulted in an improvement in AST levels in the liver compared to the poisoned group ($p < 0.01$). (Fig 2).

The results of histological studies in the control group indicate that the hepatocyte cells have a radial arrangement and are drawn from the central vein to the sides regularly. (Fig 1) The sinusoids are observed between the hepatocytes row and the macrophage (the copper cell) was seen in its wall. Administration of paraquat led to a change in the liver tissue, which was characterized by the disappearance of radial hepatocyte arranges, increased number of macrophages and lymphocytes, and the increased number of dilated sinusoids. Although NAC administration decreased the dilated sinusoids and improved hepatocytes arranges, the number of macrophages and lymphocytes was still high. In association with the Vit D treated group, hepatocyte arranges have been radially and reduced the number of inflammatory sinusoids. Few cells of macrophage and lymphocyte are seen (Fig 3D). In groups that have received NAC alone, liver toxicity is seen as a loss of radial structure of hepatocytes and an increase in inflammatory cells (Fig 3A-F).

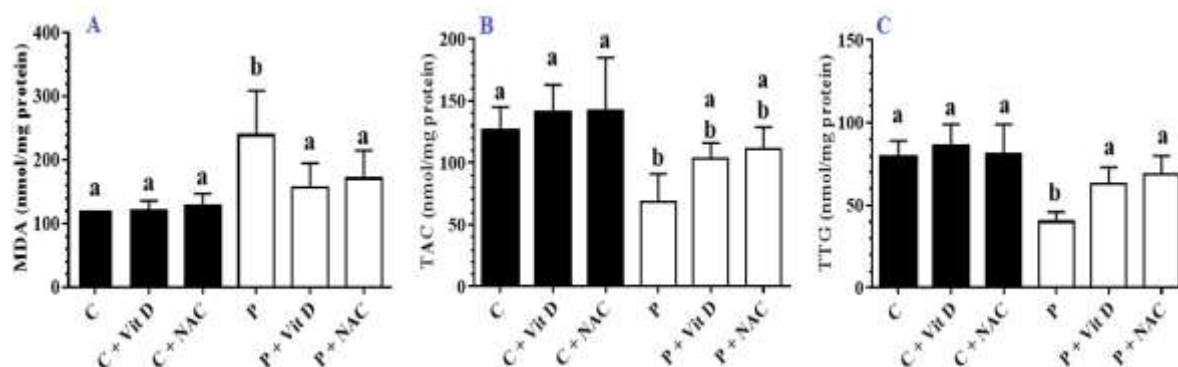


Figure 1. The results of measurement (A) of lipid peroxidation (MDA), (B) total antioxidant capacity (TAC) and (C) thiol groups (TTGs) in liver tissue in the studied groups. Data are reported based on Mean \pm SE. C: Control, P: Paraquat, Vit D: Vitamin D, NAC: N-acetylcysteine. Non-matching letters indicate a significant difference.

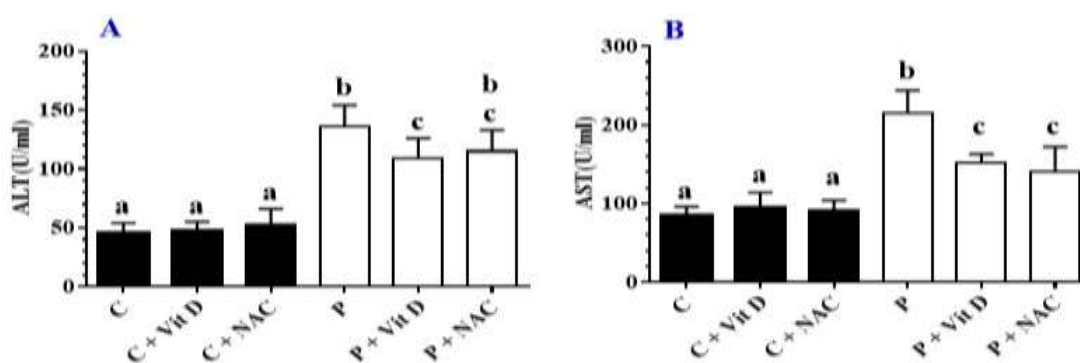


Figure 2. The results of AST and ALT measurements in the studied groups. Data were reported based on Mean \pm SD. C: Control, P: Paraquat, Vit D: Vitamin D, NAC: Nonsteylcysine. Non-matching letters indicate a significant difference.

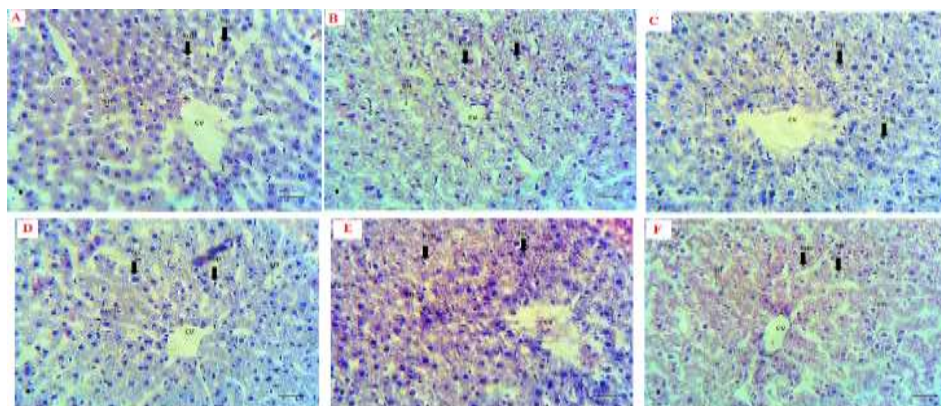


Figure 3. Hematoxylin-eosin staining of the liver tissue in the control group (A), (B) Paraquat, (C) Paraquat + NAC, (D) Paraquat + Vit D, (E) NAC group and (F) Vit D group. $\times 40$

Discussion

In this study, treatment with N-acetylcysteine and vitamin D reduced oxidative stress in liver tissue caused by paraquat poisoning compared to non-treated paraquat rats. In the present study, in control groups poisoned with paraquat, liver tissue damage, production of free oxygen radicals, increased lipid peroxidation,

decreased total antioxidant levels and thiol groups were observed. In previous studies, it has been shown that paraquat generates free radicals through the creation of a NADPH-dependent electron-reduction process, and these free radicals in contact with oxygen molecules produce superoxide anions (15). Han and colleagues reported that rabbits poisoned with paraquat had

structural damage and liver tissue changes, as well as a significant increase in AST and ALT levels. Paraquat also resulted in increased expression of the cytochrome P450 3A2 mRNA and mitochondrial damage including mitochondrial membrane swelling, mitochondrial cytochrome C reduction, and an increase in the amount of apoptosis-inducing proteins in the cell (15). In a study by Mullick et al. thirteen patients who died of acute poisoning with paraquat were examined. Following an autopsy performed on the tissues of the subjects, the most important pathologic findings were found in the pathways of bile excretion. The total and direct bilirubin levels, SGOT and SGPT liver enzymes also increased in these poisoned individuals. In this study, the reasons for the adverse effects of paraquat on the liver and other tissues are due to the increase in lipid peroxidation and also the production of a product called 4-carboxy-1-methylpyridylium chloride, which has the potential to degrade cell mitochondria (16).

In the present study, the results indicated that vitamin D treatment reduced lipid peroxidation, increased levels of thiol groups, and total antioxidant capacity as compared to the control group. Along with this study, a study by Alvarez et al. showed that a high level of vitamin D increases serum levels of glutathione and its reduced thiol group (17). Sirtuin 1 (SIRT1) is a very important factor in inhibiting oxidative stress. Polidoro et al. showed that administration of vitamin D with effect on the MEKs / ERKs / SIRT-1 pathway reduced H₂O₂ levels (18).

Another mechanism that Vit D exerts its antioxidant effects in the tissue is via the Keap1 Nrf2 route. Nrf2 controls the antioxidant factor of the cell by affecting the ARE / EpRE in the promoter of these genes (19). Nrf2 is inactive in Keap1 under physiological conditions in the cytoplasm. In Vit D treatment, expression of the Keap1 gene decreases as a result of the protein, and the amount of expression of the Nrf2 gene and protein increases in the cell, and further oxidative stress is prevented (19,20). Measuring the activity of aminotransferase enzymes is a good indicator

for measuring the damage to liver cells (21). In the early stages of liver damage, the cytoplasmic enzymes leak out of these cells through the blood stream due to increased penetrability of the hepatocyte membrane (22). In the present study, the serum levels of liver enzymes increased in the poisoned group with paraquat, which is consistent with the results of Mullick et al. (16). On the other hand, Vit D treatment reduced activity of liver enzymes in the serum of treated rats. In the study of Skaaby et al., Vit D deficiency is common in liver disease. The study also reported that increased levels of ALT and AST were associated with a reduction in vitamin D levels (23).

In the present study, also in NAC-treated poisoned rats, there was a significant decrease in oxidative stress factors compared to control poisoned group. Xu et al. reported that NAC increases the expression of the antioxidant signaling pathway HO-1, p-STAT3 and Brg1 (24). In the study of Khoshbaten et al., NAC has been shown to improve liver function and decrease the activity of aminotransferase enzymes in the serum (25). It was also reported in the study of Beyaz et al. that the administration of NAC improved liver function, decreased aminotransferase enzymes, and decreased MDA levels in laparoscopic patients (26).

In a study by Qader et al., NAC treatment has been shown to improve liver function in rifampicin toxicity. It was reported that NAC reduced ALT, AST, and ALP levels and, on the other hand, increased total antioxidants level in mice. Histopathological findings also indicated improvement in the liver structure treated with NAC, which is consistent with the results of our study (27). The results of the study showed that Vit D and NAC reduced the oxidative stress and tissue damage in the liver caused by paraquat poisoning.

Acknowledgment

Hereby, we would like to thank the Vice-Chancellor for Research of Hamedan University of Medical Sciences for financial support of this research.

References

- 1.Ortiz MS, Forti KM, Suárez Martinez EB, Muñoz LG, Husain K, Muñoz WH. Effects of antioxidant n-acetylcysteine against paraquat-induced oxidative stress in vital tissues of mice. *Int J Sci Basic Appl Res.* 2016;26(1):26-46.
- 2.Kheiripour N, Karimi J, Khodadadi I, Tavalani H, Goodarzi MT, Hashemnia M. Silymarin prevents lipid accumulation in the liver of rats with type 2 diabetes via sirtuin1 and SREBP-1c. *J Basic Clin Physiol Pharmacol.* 2018;29(3):301-8.
- 3.Han W, Wu D, Liu H, Lu Y, Wang L, Hong G, et al. Curcumin alleviated liver oxidative stress injury of rat induced by paraquat. *Zhonghua Lao Dong Wei Sheng Zhi Ye Bing Za Zhi.* 2014;32(5):352-6.
- 4.Ranjbar A, Mohsenzadeh F, Chehregani A, Khajavi F, Zijoud SM, Ghasemi H. Ameliorative effect of *Matricaria chamomilla* .L on paraquat: Induced oxidative damage in lung rats. *Pharma Res.* 2014;6(3):199-203.
- 5.Atkuri KR, Mantovani JJ, Herzenberg LA, Herzenberg LA. N-Acetylcysteine—a safe antidote for cysteine/glutathione deficiency. *Curr Opin Pharmacol.* 2007;7(4):355-9.
- 6.Vakilian K, Ranjbar A. Associations of oxidative stress indices in infants born via natural delivery with entonox exposure. *J Babol Univ Med Sci.* 2015;17(10):34-8. [In Persian].
- 7.Lu SC. Regulation of glutathione synthesis. *Mol Aspects Med.* 2009;30(1-2):42-59.
- 8.Jain SK, Micinski D, Huning L, Kahlon G, Bass PF, Levine SN. Vitamin D and L-cysteine levels correlate positively with GSH and negatively with insulin resistance levels in the blood of type 2 diabetic patients. *Eur J Clin Nutr.* 2014;68(10):1148-53.
- 9.Azad A, Lall S, Mittra S. Effect of N-acetylcysteine and L-NAME on aluminium phosphide induced cardiovascular toxicity in rats. *Acta Pharmacol Sin.* 2001;22(4):298-304.
- 10.Moghadamnia AA, Hakiminia S, Baradaran M, Kazemi S, Ashraf-pour M. Vitamin D improves learning and memory impairment in streptozotocin-induced diabetic mice. *Arch Iran Med.* 2015;18(6):362-6.
- 11.Awadalla EA. Efficacy of vitamin C against liver and kidney damage induced by paraquat toxicity. *Exp Toxicol Pathol.* 2012;64(5):431-4.
- 12.Zanganeh N, Siahpoushi E, Kheiripour N, Kazemi S, Goodarzi MT, Alikhani MY. Brucellosis Causes Alteration in Trace Elements and Oxidative Stress Factors. *Biol Trace Elem Res.* 2018;182(2):204-8.
- 13.Artimani T, Karimi J, Mehdizadeh M, Yavangi M, Khanlarzadeh E, Ghorbani M, et al. Evaluation of pro-oxidant-antioxidant balance (PAB) and its association with inflammatory cytokines in polycystic ovary syndrome (PCOS). *Gyneco Endocrinol.* 2018;34(2):148-52.
- 14.Rahimi R, Karimi J, Khodadadi I, Tayebinia H, Kheiripour N, Hashemnia M, et al. Silymarin ameliorates expression of urotensin II (U-II) and its receptor (UTR) and attenuates toxic oxidative stress in the heart of rats with type 2 diabetes. *Biomed Pharmacother.* 2018;101:244-50.
- 15.Han J, Zhang Z, Yang S, Wang J, Yang X, Tan D. Betanin attenuates paraquat-induced liver toxicity through a mitochondrial pathway. *Food Chem Toxicol.* 2014;70(Supplement C):100-6.
- 16.Mullick FG, Ishak KG, Mahabir R, Stromeyer FW. Hepatic injury associated with paraquat toxicity in humans. *Liver.* 1981;1(3):209-21.
- 17.Alvarez JA, Chowdhury R, Jones DP, Martin GS, Brigham KL, Binongo JN, et al. Vitamin D status is independently associated with plasma glutathione and cysteine thiol/disulphide redox status in adults. *Clin Endocrinol.* 2014;81(3):458-66.
- 18.Polidoro L, Properzi G, Marampon F, Gravina GL, Festuccia C, Di Cesare E, et al. Vitamin D protects human endothelial cells from H(2)O(2) oxidant injury through the Mek/Erk-Sirt1 axis activation. *J Cardiovasc Transl Res.* 2013;6(2):221-31.
- 19.Nakai K, Fujii H, Kono K, Goto S, Kitazawa R, Kitazawa S, et al. Vitamin D activates the Nrf2-Keap1 antioxidant pathway and ameliorates nephropathy in diabetic rats. *Am J Hypertens.* 2014;27(4):586-95.

20. Kobayashi M, Yamamoto M. Molecular mechanisms activating the Nrf2-Keap1 pathway of antioxidant gene regulation. *Antioxid Redox Signal*. 2005;7(3-4):385-94.
21. Cetinkunar S, Tokgoz S, Bilgin BC, Erdem H, Aktimur R, Can S, et al. The effect of silymarin on hepatic regeneration after partial hepatectomy: is silymarin effective in hepatic regeneration? *Int J Clin Exp Med*. 2015;8(2):2578.
22. Chin J, Abas H, Sabariah I. Toxicity study of orthosiphon stamineus benth (misai kucing) on Sprague dawley rats. *Trop Biomed*. 2008;25(1):9-16.
23. Skaaby T, Husemoen LL, Borglykke A, Jorgensen T, Thuesen BH, Pisinger C, et al. Vitamin D status, liver enzymes, and incident liver disease and mortality: a general population study. *Endocrine*. 2014;47(1):213-20.
24. Xu J, Lei S, Liu Y, Gao X, Irwin MG, Xia Z-y, et al. Antioxidant N-acetylcysteine attenuates the reduction of Brg1 protein expression in the myocardium of type 1 diabetic rats. *J Diabetes Res*. 2013;2013. 1-8.
25. Khoshbaten M, Aliasgarzadeh A, Masnadi K, Tarzamani MK, Farhang S, Babaei H, et al. N-Acetylcysteine Improves Liver Function in Patients with Non-Alcoholic Fatty Liver Disease. *Hepat Mon*. 2010;10(1):12-6.
26. Beyaz SG, Yelken B, Kanbak G. The effects of N-acetylcysteine on hepatic function during isoflurane anaesthesia for laparoscopic surgery patients. *Indian J Anaesth*. 2011;55(6):567-72.
27. Qader GI, Aziz R, Ahmed Z, Abdullah Z, Hussain SA. Protective Effects of Quercetin against Isoniazid and Rifampicin Induced Hepatotoxicity in Rats. *Am J Pharmacol Sci*. 2014;2(3):56-60.