

## A Case of Cecal Perforation Due To Ogilvie's Syndrome after Cesarean Section

A. Kamali (MD)<sup>1</sup>, Sh. Barat (MD)<sup>2</sup>, Y. Asghari (MD) \*<sup>1</sup>

1. Department of Surgery, Babol University of Medical Sciences, Babol, I.R. Iran

2. Fateme Al-Zahra Gynaecology & Obstetrics Research Center, Health Research Institute, Babol University of Medical Sciences, Babol, I.R. Iran

J Babol Univ Med Sci; 18(10); Oct 2016; PP: 65-9

Received: Mar 7<sup>th</sup> 2016, Revised: Jun 1<sup>st</sup> 2016, Accepted: Sep 26<sup>th</sup> 2016.

### ABSTRACT

**BACKGROUND AND OBJECTIVE:** Ogilvie Syndrome is an acute, non-organic pseudo obstruction of the colon due to neurological dysfunction of the bowel, that can be happened after pelvic & gynecologic surgery. Perforation of the colon and peritonitis can occur due to perfusion impairment of the colon wall, because of increased intraluminal pressure of the bowel. We here reported a case of this rare syndrome as it may have high mortality and morbidity if any delay be occurred.

**CASE REPORT:** A 33 years old Female patient, presented with abdominal distention and obstipation and constipation 48 hours after her 2nd cesarean section delivery that accompanied with abdominal pain, fever and tachycardia and abdominal tenderness, regard less to conservative management. So she Underwent laparotomy with impression of peritonitis. Severe dilation of the cecum and ascending colon with perforation of the cecal wall was found known as Ogilvie syndrome. Right hemicolectomy and ileocolic anastomosis was done. A 33 years old Female patient, presented with abdominal distention and obstipation and constipation 48 hours after her 2nd cesarean section delivery that accompanied with abdominal pain, fever and tachycardia and abdominal tenderness, regard less to conservative management. So she Underwent laparotomy with impression of peritonitis. Severe dilation of the cecum and ascending colon with perforation of the cecal wall was found known as Ogilvie syndrome. Right hemicolectomy and ileocolic anastomosis was done. The patient was house arrested for 5 days in ICU of surgery. During this period, patient was treated with broad spectrum antibiotics, optimal hydration and nutritional support as PPN were performed. On the fifth day after surgery, a liquid diet was started for patient and bowel movement was established. After 10th day of surgery, the patient was discharged with good general appearance. In three months follow-up after surgery, there was no specific complication

**CONCLUSION:** Proper and on-time diagnosis and management of the Ogilvie Syndrome, decreases the rate of mortality and morbidity of this emergent condition. It is important for the healthcare provider to know this critical condition and to have high clinical suspicion when deal with a patient with bowel obstruction symptoms after pelvic & gynecologic surgery.

**KEY WORDS:** Ogilvie's, Syndrome, Cesarean Section, Cecal, Perforation.

### Please cite this article as follows:

Kamali A, Barat Sh, Asghari Y. A Case of Cecal Perforation Due To Ogilvie's Syndrome after Cesarean Section. J Babol Univ Med Sci. 2016;18(10):65-9.

\*Corresponding author: Y. Asghari (MD)

Address: Department of Surgery, Shahid Beheshti Hospital, Babol University of Medical Sciences, Babol, I.R. Iran

Tel: +98 11 32252071-5

E-mail: yasserasghari80@gmail.com

## Introduction

Ogilvie syndrome or acute colonic pseudo-obstruction is considered as severe distension of the colon without specific organic cause (1). This disease is rare but life-threatening might be due to trauma, pelvic surgery (orthopedics, gynecology, urology), metabolic disorders, nervous system disorders, medications and idiopathic (2, 3). Delayed diagnosis could lead to increase morbidity and mortality rates, so that the risk of mortality in this disease is 15-31%, and in case of cecal perforation and fecal peritonitis this risk will increase to 45% (2, 4). Acute colonic pseudo-obstruction syndrome or Ogilvie was first described in 1948 (5). In general, this syndrome occurs after trauma or abdominal or pelvic surgery (6).

In women, cesarean is the most common cause of injuries for this syndrome. However, some cases of this syndrome has been reported following normal vaginal delivery (6, 7). Physiopathology of Ogilvie's syndrome is not precisely known, but different reasons were considered for this syndrome. Bed rest and electrolyte disturbances may be a risk factor of this syndrome (8). Best-accepted theory is autonomic nervous system dysfunction associated with subsequent ischemic process following colon surgery (1, 9). According to this theory, the parasympathetic nervous system function of the left colon (S2-S4) is inhibited while the neurological function of right colon is preserved. By inhibiting sacral parasympathetic function (S2-S4) and also the normal function of parasympathetic vagal, the left colon will be collapsed and right colon will be dilated and these changes of colon diameter are evident in splenic flexure, and can confirm the assumption of parasympathetic inhibition in Ogilvie syndrome (7).

Based on difference in neurological function of the colon, the peristalsis of left colon is inhibited and thus the pressure is transmitted to right colon and the right colon is dilated and pressure is increased in the wall which leads to impaired capillary circulation of right colon wall. This causes ischemia and necrosis and ultimately perforation of the colon. Perforation usually occurs in the cecum, a part of colon with greatest expansion and experiencing the greatest amount of parietal pressure. dilation-induced Parietal ischemia and increased pressure on the lining of the colon affect nerve function, leading to a vicious cycle that only by creating a perforation, decompression occurs (11, 10). Typical clinical features of this syndrome is distal intestinal obstruction with progressive process that

usually occurs within 72 hours after surgery, however, can be faster than or the time delay of up to 7 days occur after surgery (6, 4, 2).

Clinical symptoms of this disease according to a study of Vanek et al., include: bloating (100%), abdominal pain (83%), constipation (51%), diarrhea (41%), fever (37%) and signs of peritoneal irritation (12). Acute colonic pseudo-obstruction syndrome known as an emergency that must be diagnosed and treated in time to prevent the occurrence of perforation and subsequent morbidity and mortality. Due to the rarity of this condition and serious risks caused by lack of timely diagnosis and treatment and very high morbidity and mortality of Ogilvie syndrome, we report a case of this syndrome resulted in perforation of the cecum undergoing hemicolectomy.

## Case Report

33-year-old female patient with complain of bloating and lack of bowel movements from two days ago (48 hours after cesarean) was admitted to Ayatollah Rohani hospital in Babol. The patient was experiencing her fourth pregnancy. In a preliminary assessment, vital signs was normal and abdominal distention was observed and abdomen was soft in touch. First ileus following surgery was confirmed. Therefore, support and drug treatment was done as follows.

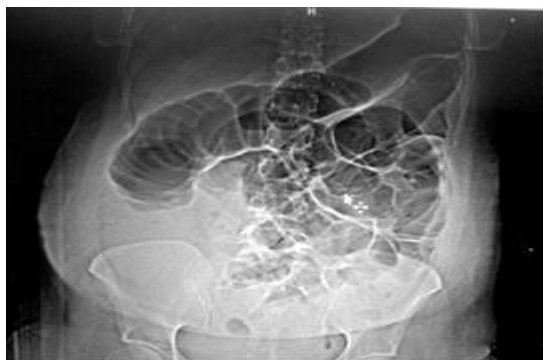First, hydration, liquid diet and bisacodyl suppositories was given and because of the lack of improvement in symptoms and nausea, patient was NPO, nasogastric tube and urinary catheter was inserted. With the passage of time in the course of the fifth day of hospitalization, the patient's abdomen distention increased associated with nausea, vomiting, fever and abdominal pain.

In examination the patient had tachycardia, abdominal tenderness and fever ( $C^{\circ}38$ ), in the Digital Rectal Exam (DRE), rectum was empty, in blood tests had leukocytosis ( $9700 = WBC$ ), BUN: 11, Cr: 0.8, Na: 133, K: 4.1, Hb: 11, respectively. Because of protective actions in the course of hospitalization, the patient's state of hydration and urine output was satisfactory. In Abdominal radiography diffused hyperinflation and dilation of the small and large intestine loops were observed (Fig 1). In Ultrasound, bowel loops dilatation was reported. The patient underwent abdominal CT scan including some points such as free fluid in the abdomen, severe dilation of

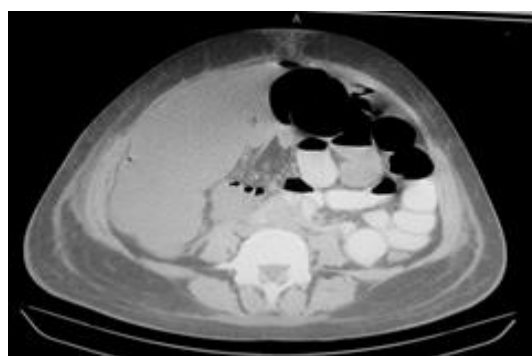
the colon especially in cecum and ascending colon and distended loops of small intestine (Fig 2). Thus, with respect to the total clinical and paraclinical findings, patient underwent laparotomy with the primary diagnosis of peritonitis. In the review procedure, discharge and some brief reactive and fecal materials were evident in right paracolic gutter and hip that was evacuated.

Diffuse distension of the bowel was evident that this expansion resulted in regional ischemia, necrosis and perforation of the ascending colon and cecum and therefore Ogilvie syndrome was considered. Resection of the distal ileum, cecum and ascending colon was done (right hemicolectomia) and according to the ileum and transverse colon health ileocolic anastomosis was done.

After surgery patient was considered For 5 days in ICU and during this period, treated with broad spectrum antibiotics, optimal hydration and nutritional support for PPN. On the fifth day after surgery, the patient received a liquid diet and bowel movements were established. After 10 days of surgery, the patient was discharged. In three months follow-up after surgery, there was no specific complication.



**Figure 1. X-ray image of the patient's stomach indicating the severe dilatation of intestine and colon loops**



**Figure 2. Axial section of CT scan of the abdomen: severe dilation of the cecum and colon and air-liquid surface**

## Discussion

In mentioned patient, symptoms of the disease was started 48 hours after cesarean section. On physical examination, abdominal distention and increased bowel sounds are found (4). In the absence of necrosis and perforation, palpation of the abdomen is without tenderness and the patient's general condition is good. When the pain is localized in R.L.Q or patients with fever should be suspected cecal perforation (6). In the case of this report, progressive abdominal distention along with nausea, vomiting and lack of bowel movements were associated with fever, tachycardia, and abdominal tenderness. One of differential diagnosis of the Ogilvie syndrome is paralytic ileus which the bowel sounds is reduced and flatus and bowel movement are stops, while in Ogilvie syndrome bowel sounds increase and can even lead to diarrheal bowel movements (13).

Laboratory findings are not specific for the diagnosis of Ogilvie's syndrome. Main disorder that can be noted is leukocytosis and electrolyte imbalances. Leukocytosis in 27% of cases is without complication and is seen in 100% cecal perforation (6). Hypocalcaemia Is the most common electrolyte disorder in this syndrome (7). One of the key assessments for diagnosis of Ogilvie syndrome is medical imaging. In The first step must be taken a plain abdominal X-Ray. In The imaging, colon is generalized or partial distended which it is dominant in the cecum. In addition, in 30% of the cases distention of small intestine with multiple air-fluid levels is evident (4). In our study dilation of the colon and small intestine with multiple levels of air-fluid in abdominal radiography was evident. If the diameter of the cecum in X-Ray more than 9 cm and in some studies to be more than 10 cm is suggestive of obstruction and may indicate a risk of perforation (14,7,5).

Cecal perforation can be detected on abdominal CT with contrast enhancement. CT scan can also detect other differential diagnosis including sigmoid volvulus, cecal volvulus, organic causes such as tumors and fecaloma or peritonitis (6). In our patient, CT scan showed dilatation of the bowel, colon and large diameter of cecum which is suggestive of Ogilvie's syndrome.

Ogilvie's syndrome is an emergency of diagnosis and treatment. Treatment guidelines of this syndrome is related to the general condition of the patient, the size of the cecum in the imaging and presence or absence of cecal perforation. The main goal of

treatment is to reduce immediately the diameter of cecum and prevent perforation of the cecum. Investigations show that in cases with the colonic decompression on the seventh day compared with that action be taken on the fourth day mortality will be more 5 times (6).

In the absence of perforation, initial treatment will be conservative or supportive. These symptomatic and supportive treatments should be done in surgery unit with careful daily monitoring and clinical and radiographic evaluation. Treatment guidelines developed by the United States Association of gastrointestinal endoscopy in 2012, include: The NPO of patient, nasogastric tube insertion, correction of electrolyte disorders and rectal tube insertion and bowel movements inhibitors.

Frequent patient's status changes helps to make the bowel movements. Criteria of successful treatment in these patients are regression of abdominal distention, flatus, and feces and reduction of cecum diameter in the imaging(1). We also performed NPO in our patient, embedded nasogastric tube and Foley catheter and also controlled hydration, antibiotic, modification and electrolyte status of the patient. Parasympathomimetic drugs such as neostigmine in cases that not improved 24 hours after symptomatic treatment and there are no contraindications for prescribing, is prescribed.

It should be noted that prescriptions should not delay the decompressive colonoscopy or surgical intervention. Neostigmine is slowly administered intravenously at a rate of 2 to 5.2 mg. In 10% of cases, side effects are observed. This may be minor side effects such as increased salivation, abdominal cramps, nausea and vomiting or major complications such as obstruction of bronchus, bradycardia, hypotension that require precise monitoring of heart rate, blood pressure and the availability of atropine.

Endoscopic decompression can be helpful in the diagnosis and treatment of Ogilvie's syndrome. Even when the diameter of cecum reaches to 9-12 cm and medical therapy fails, if there is no evidence of perforation endoscopic decompression can be used. This method can be associated with 61% to 100% improvement and the intestinal wall, openness of intestinal lumen and intestinal mucosal status can be

examined through endoscopy. In Ogilvie syndrome, decompressive endoscopy as a difficult process and must be done by an experienced physician. Air injection should be minimized to prevent perforation in 5% of cases (1). In case of failure of medical therapy or if there is evidence of necrosis and perforation have to be surgical treatment (3).

Surgical treatment based on the severity of peritonitis and abdominal infection, can include embedded resection and colostomy of damaged part or in limited cases can be attempted primary anastomosis. In the patient described in this report with respect to the incidence of cecal perforation and localized peritonitis, right hemicolectomy and ileocolic anastomosis was done.

Ogilvie Syndrome is a rare complication following the cesarean and due to the risk of necrosis and perforation of the cecum can be dangerous and potentially deadly. General practitioners/ gynecologists, and surgeons should be familiar with the usual and unusual presentation of this syndrome and in patients after childbirth, if there is unexplained abdominal distention, must have a high clinical suspicion until error and delay in diagnosis can be prevented. Diagnosis is based on clinical presentation as intestinal obstruction with abdominal pain and distension of the colon in abdominal imaging.

Rapid diagnosis to prevent life-threatening complications, and treatment is essential and supportive treatment should be initiated quickly and accurately. If symptoms of necrosis and perforation does not exist, Initial treatment is symptomatic and supportive and when complications are suspected, surgical intervention should be done without further delay.

## Acknowledgments

Hereby, we would like to thank the doctor Mohsen Aliasgharzadeh, surgical assistant at Babol University of Medical Sciences worked on gathering patient information as well as all colleagues in the surgery department, operating room of Ayatollah Rouhani hospital and clinical research unit of Shahid Beheshti hospital.

## References

1. Fatnassi R, Mkhinini I, Abdelkefi MS, Torki E, Hammami S, Barhoumi H. Ogilvie's Syndrome: A Caesarean Section Complication (A two cases report and review of the literature). *EC Gynaecol*. 2015;1(1):35-40.
2. Kakarla A1, Posnett H, Jain A, Ash A. Acute pseudo-obstruction of the colon (Ogilvie's syndrome) following instrumental vaginal delivery. *Int J Clin Pract*. 2006;60(10):1303-5.
3. Basirat Z, Hashifard M, Bouzary Z. A case report of colonic pseudo-obstruction (Ogilvie's Syndrome) after cesarean delivery. *Sci J Kurdistan Univ Med Sci*. 2004;2(30):76.[In Persian].
4. Weber P, Heckel S, Hummel M, Dellenbach P. Ogilvie's syndrome after cesarean section. Apropos of 3 cases. Review of the literature. *J Gynecol Obstet Biol Reprod (Paris)*. 1993;22(6):653-8.
5. Madu AE. Ogilvie's syndrome and caecal perforation following caesarean section for concealed placental abruption. *J Paediatr Obstet Gynaecol*. 2007;13:121-2.
6. Mainguy Le Gallou C, Eboue C, Vardon D, Von Theobald P, Dreyfus M. [Ogilvie's syndrome following cesarean section: Just think! Report of two cases and review of the literature]. *J Gynecol Obstet Biol Reprod (Paris)*. 2011;40(6):557-63.
7. Cartlidge D, Seenath M. Acute pseudo-obstruction of the large bowel with caecal perforation following normal vaginal delivery: a case report. *J Med Case Rep*. 2010;4:123.
8. Jetmore AB, Timmcke AE, Gathright JB, Jr., Hicks TC, Ray JE, Baker JW. Ogilvie's syndrome: colonoscopic decompression and analysis of predisposing factors. *Dis Colon Rectum*. 1992;35(12):1135-42.
9. Roux M, Fichez A, Roth P, Gaucherand P. Ogilvie's syndrome after cesarean section: A case report. *Gynecol Obstet Fertil*. 2011;39(1):15-9.
10. Ben Ameer H, Boujelbene S, Beyrouti MI. Treatment of acute colonic pseudo-obstruction (Ogilvie's Syndrome). Systematic review. *Tunis Med*. 2013;91(10):565-72.
11. Saunders MD. Acute colonic pseudo-obstruction. *Best Pract Res Clin Gastroenterol*. 2007;21(4):671-87.
12. Vanek VW, Al-Salti M. Acute pseudo-obstruction of the colon (Ogilvie's syndrome). An analysis of 400 cases. *Dis Colon Rectum*. 1986;29(3):203-10.
13. Roberts CA. Ogilvie's syndrome after cesarean delivery. *J Obstet Gynecol Neonatal Nurs*. 2000;29(3):239-46.
14. Harrison ME, Anderson MA, Appalaneni V, Banerjee S, Ben-Menachem T, Cash BD, et al. The role of endoscopy in the management of patients with known and suspected colonic obstruction and pseudo-obstruction. *Gastrointest Endosc*. 2010;71(4):669-79.