

The Effect of Hydroalcoholic Vac Extract on Pituitary-Thyroid Axis Function in Adult Male Rats

Z. Hashempour (MSc)¹, S.E. Hosseini (PhD)*¹

1. Department of Biology, Shiraz Branch, Islamic Azad University, Shiraz, I.R.Iran

J Babol Univ Med Sci; 18(7); Jul 2016; PP: 41-7

Received: Jan 23th 2016, Revised: Mar 2nd 2016, Accepted: Jun 1st 2016

ABSTRACT

BACKGROUND AND OBJECTIVE: Thyroid disorders are relatively common diseases throughout the world. According to chemical drugs side effects, this study aimed to investigate the effect of the pituitary-thyroid axis function VAC extract in adult male rats.

METHODS: In this study, 50 adult male rats were divided into control and experimental groups received doses of 50, 100 and 200 mg / kg VAC extracts. All prescribed for 30 days and was conducted by gavage. In the end, after collecting blood samples from animals to measure T3, T4 and TSH hormones, thyroid removed and after preparing tissue sections follicles were counted and compared.

FINDINGS: The results showed that extracts of Vitex decreased TSH and increased T4 hormone in the order of 0.72 ± 0.1 and 3.66 ± 0.30 in the control group to 0.27 ± 0.03 and 5.76 ± 0.47 in the group receiving dose of 200 mg/kg and increases T3 of 71.20 ± 4.05 in control group to 90.60 ± 5.63 and 88.8 ± 5.39 at doses of 100 and 200 mg/kg. In addition, extracts of Vitex decreased body weight of 310 ± 4.5 in the control group to 286.66 ± 13.95 , 265.83 ± 13.77 and 276.83 ± 10.13 at doses 50, 100 and 200 mg/kg ($p < 0.05$). Moreover, Vitex extract increased the total number of follicles of 17.19 ± 2.44 in the control group to 31.54 ± 2.9 and 34.66 ± 1.5 and 36.77 ± 3.45 and active follicles of 13.15 ± 2.04 in the control group to 28.83 ± 2.46 , 28.77 ± 2.98 and 34.38 ± 2.84 in experimental groups ($p < 0.01$).

CONCLUSION: The results of this study demonstrated that Vitex extract significantly increased thyroid hormones and reduced TSH and body weight.

KEY WORDS: *Vitex, Triiodothyronine, Thyroxine, Thyrotropin, Thyroid Follicles.*

Please cite this article as follows:

Hashempour Z, Hosseini SE. The Effect of Hydroalcoholic Vac Extract on Pituitary-Thyroid Axis Function in Adult Male Rats. J Babol Univ Med Sci. 2016;18(7):41-7.

* Corresponding author: E. Hosseini (PhD)

Address: Department of Biology, Shiraz Branch, Islamic Azad University, Shiraz, I.R.Iran

Tel: +98 71 43311148

E-mail: ebrahim.hossini@yahoo.com

Introduction

Vitex with the scientific name *Vitex agnus castus* L is a form of mangrove (Verbenaceae) that grows in the mediterranean and in the north, south, southwest and east areas in Iran and around Tehran (1). VAC has essential oils, iridoid glycosides, flavonoids diterpene and essential fatty acids. Some evidence suggest that Vitex extract containing compounds such as vitex lactones, which receptors able to bind to D2 Dopamine receptors in the hypothalamus and pituitary and also has precursors of steroidal hormones (3).

Kastysyn which is a flavonoid isolated from VAC inhibits the release of prolactin from the anterior pituitary cells and this effect may be related to the inhibition of expression of mRNA, ER α and increased expression of mRNA ER β (4). VAC extract containing compounds that increase dopaminergic activity and inhibits the release of the prolactin hormone through dopamine D2 receptors (5). In another study it was shown that VAC extract increased prolactin during lactation that is consistent by the results of some studies on the VAC stating that the plant will be increased milk (6).

In one study it was shown that VAC extract stimulates μ and δ opioid receptors (7). Evidences show that treatment with Vitex increases preantral follicles, antral and corpus luteum, reducing the number of follicles cyst, reducing the thickness of the tunica albuginea ovarian theca layer thickness reduction and increasing the thickness of the granulosa of antral follicles (8).

The results of a study showed that extracts of Vitex is effective in reduction of premenstrual syndrome symptoms (9). VAC extract helps to prevent miscarriage and has important effects on embryonic development in animals such as mice during different stages of pregnancy (weight gain and growth) (10). VAC extract has estrogen-like effects on reducing anxiety caused by ovariectomy in rats (11). In addition, VAC extract has effects similar to estrogen that protects the neurons in ovariectomized mice with middle cerebral artery occlusion (MCAO) (12). The thyroid is one of the important gland of the body and hormones secreted by it, are involved in regulating of many body functions such as metabolism of carbohydrates, lipids, nerve impulse conduction, oxygen consumption and reproduction, so that the variation in their natural amount causes some physiological abnormalities as hypothyroidism and hyperthyroidism (13). Thyroid hormones has an

important role in the growth and development of different regions of the brain, especially the hippocampus, sub Ventricular and olfactory bulb and that all involved in spatial memory and learning (14, 15). Several factors are effective in the regulation of thyroid hormone and TSH in the blood (16). In some studies have shown that plant alkaloids and flavonoids and steroidal compounds are effective in function of pituitary-thyroid axis (17).

Extract of the harmal's seeds by having steroidal and alkaloids compounds and has a depressing effect on Pituitary-thyroid hormonal axis function (18) or *Salvia officinal* is extract increases the amount of thyroid hormone in mice with the hypothyroidism disorder (19). Hosseini was shown in a study that disulfiram as GABA receptor antagonist, probably by increasing the activity of the enzyme 5-Deiodinase, serotonin, and increasing calcium entry into the cells and reduction of somatostatin has no significant effect on the T4 hormone plasma levels, but increases the hormones T3 and TSH (20).

Given the increasing use of medicinal plants in the treatment of diseases and disorders around the world and due to the fact that until now little research has been done into the effects of VAC extract -that also has many applications in traditional medicine-, on thyroid gland function and thyroid hormone levels. Since the Alcoholic extract of this plant, that has the most compounds of this plant's extract (21) Therefore, this study aimed to investigate the effects of the VAC extract on pituitary-thyroid axis function in adult male rats.

Methods

This experimental study was done in 1394 at Islamic Azad University of Shiraz on 50 adult male Wistar rats weighing approximately 220-200 g. The test animals were prepared from animal house of Shiraz University of Medical Sciences and were stored in a special room at 22 \pm 2 degrees celsius and 12 hours of darkness and 12 hours of light conditions. Samples were divided into 5 groups of 10 specimens included the control group (no treatment), control (treated with a solvent) and three experimental groups receiving doses of 50 mg/kg, 100 mg/kg and 200 mg/kg hydroalcoholic VAC extract (12).

Throughout the experiment, the animals had no access restrictions to municipal tap water and compressed food for mice. The study protocol based

on international law concerning the protection of laboratory animals set and adopted by the university ethics committee. In this study the percolation method was used to prepare the VAC extract, and to do this in sufficient quantities VAC were collected from the area around Tehran. After identification and approval by the Department of Botany of University of Shiraz and after drying by using electric mill, were powdered. Then a sufficient amount of powder dissolved in 200 ml of ethanol 96% and the resulting mixture were kept for 24 hours at room temperature (25°C) to be completely soaked and stirred by an electric whisk well until to be uniform. After that, the resulting mixture was filtrated by a filter and the resulting mixture was concentrated by rotary device and taken all the moisture mixed with desiccating to extract obtained with high viscosity.

All rats prescribed for 30 days and was conducted by gavage. At the end of the period, rats were anesthetized by ether and then to measure the serum level of T3, TSH and T4, blood samples were taken from the heart by a syringe 5 ml. The animal thyroid gland removed and after tissue sectioning and staining with hematoxylin-eosin, the number of thyroid follicles were counted.

To measure the volume of colloid in thyroid follicles due to the fact that each follicular thyroid has a major axis (a) and a minor axis (b), First, by application of Astreolayt large and small diameter space in each follicle colloid, measured so that the large diameter (a) perpendicular to the small diameter (b), and then to convert these measurements directly into diameters (d) a circle with the same area, the formula $d = \sqrt{a \times b}$ was used. In addition, to offset the effects of tissue cutting diameter measured on a node (d), that were less than expected, Abercrombie and colleagues methods were used to calculate the diameter closer to true value (22). The mean diameter (D) was estimated using the formula $D = d \times \frac{4}{\pi}$. The correct mean diameter (D) to assess the volume of colloids (Vcol) was calculated assuming that the cross sections is equivalent to a circle of equal space and finally colloid space (Vcol) calculated by using the formula $V_{col} = \frac{\pi \times D^3}{6}$ (23). In this research to determine the proportion of nuclear and cytoplasmic, the 50 follicles were found in each animal and then exterior and interior border line around each follicle

was drawn manually and by Astreolayt software. The cytoplasmic region (Anc) is calculated by subtracting the area occupied by the two border and then the area occupied by each core was measured manually and by using software (Although the number of cores in each follicle is usually between 24 and 68 number but the average area of 44 core was measured) and the nuclear area (An) has summed and from the main area (Anc) were revealed to calculate the cytoplasmic surface area (Ac).

As well as cytoplasmic-nuclear ratio was calculated by using the formula $N/C \text{ ratio} = \frac{A_n}{A_{nc} - A_n}$ (23). Also in this study, to measure thyroid hormones Kavoshyar Company's production of a hormone kits and ELISA method were used. Data obtained by measuring serum concentrations of T3, T4 and TSH and the results of histological studies analyzed by 18-SPSS software and ANOVA and Duncan tests and $p \leq 0.05$ was considered significant.

Results

The results of data analysis of this study showed a significant decrease in mean serum concentration of TSH hormone. And a significant increase in mean serum concentration of T4 hormone in the group receiving the VAC extract at doses of 200 mg / kg And a significant increase in the concentration of T3 hormone And a reduction in body weight in the groups receiving VAC extract at a dose of 100 and 200 mg/kg compared to the control group ($p \leq 0.05$) (table 1). The results of this study showed a significant reduction in the volume of colloid in VAC extract groups receiving doses of 50, 100 and 200 mg / kg compared to controls ($p \leq 0.01$).

In addition, no significant change was observed in the nuclear-cytoplasmic (N/C) follicular cells in VAC extract recipient groups compared to controls. As well as a significant increase in epithelium height follicles in thyroid tissue was observed in the group receiving VAC extract at a dose of 100 and 200 mg/kg to the control group ($p \leq 0.05$).

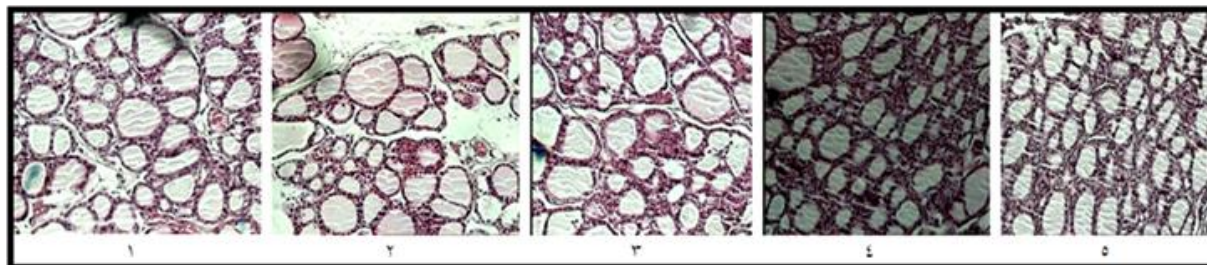
A significant increase in the number of thyroid follicles and in the average number of active follicles were observed in the group receiving VAC extract at a dose of 100 and 200 mg/kg to the control group ($p \leq 0.05$) (table 2, Fig 1).

Table 1. Comparison of serum levels of T3, TSH, T4 and body weight in the VAC extract treatment groups compared to the control group.

Groups	Hormones Mean±SD	TSH(IU/ml) Mean±SD	T4(ng/ml) Mean±SD	T3(pg/ml) Mean±SD	Body weight (gr) Mean±SD
Control		0.72±0.1	3.66±0.30	71.20±4.05	310.00±4.50
Experimental		0.70±0.07	3.53±0.43	70.20±4.23	307.50±4.16
VAC extract 50 mg/kg		0.46±0.07	3.68±0.55	79.20±6.81	286.66±13.95
VAC extract 100 mg/kg		0.44±0.13	4.76±0.59	*90.60±5.63	*265.83±13.77
VAC extract 200 mg/kg		0.27±0.03*	*5.76±0.47	*88.80±5.39	*276.83±10.13

Table 2. Comparison of thyroid follicle number, follicle epithelium height, nuclear-cytoplasmic ratio in follicular cells and size of the colloid follicles in the groups treated with VAC extract compared to the control group

Follicle Group	The total number of follicles Mean±SD	The total number of active follicles Mean±SD	The height of follicular epithelium (µm) Mean±SD	Nuclear-cytoplasmic ratio of follicular cells Mean±SD	The amount of space colloids (3µm) Mean±SD
Control	17.19±2.44	13.15±2.04	8.16±0.35	0.52±0.01	1586.07±307.95
Experimental	17.15±2.40	13.32±1.95	7.91±0.50	0.51±0.01	1586.07±306.96
VAC extract 50 mg/kg	31.54±2.90 **	28.83±2.46**	8.31±0.24	0.62±0.08	834.23±83.03**
VAC extract 100 mg/kg	34.66±1.50**	28.77±2.98**	10.15±0.59	0.6±0.05*	630.16±68.6**
VAC extract 200 mg/kg	36.77±3.45**	34.38±2.84**	10.55±0.82	0.60±0.03*	557.29±71.65**

**Figure 1. Optical micrograph photo of thyroid tissue in the group (1) control, (2), (3, 4 and 5) groups received VAC extract at the dose of 50, 100 and 200 mg/kg -hematoxylin and eosin staining and magnification×100-**

Discussion

The results of this study showed that the VAC extract reduces thyroid hormone, TSH and increase thyroid hormones and also increase the number of follicles, the activated follicles, the height of the epithelium of follicles and reduce thyroid follicular colloid volume. Studies have shown that nerve neurotransmitter acetylcholine, serotonin, norepinephrine, epinephrine, dopamine, and some neuropeptides including somatostatin, neurotensin affect function of hormonal axis hypothalamus-pituitary-thyroid. It is known that serotonin, somatostatin, dopamine has inhibitory effects on the release of TSH are stimulated by TRH (24, 3). In addition, it has been shown that Metoclopramide as dopamine antagonist, in the

treatment of movement disorders caused increased secretion of TSH (25). Thus, according to dopaminergic compounds in the Vitex (5, 3) possibly dopaminergic substances in the plant has reduced the TSH hormone secretion. In one study has shown that in people with Hyperprolactinemia disorders Hypothyroidism syndrome can also be seen (26). Clinical studies also have shown a positive relationship between hyperprolactinemia and hypothyroidism (16). Therefore, due to the inhibitory effect of VAC extract on the secretion of the prolactin hormone (27) probably the plant by reducing levels of this hormone, increases thyroid hormone. Another possible mechanisms of the effects of VAC which needs further

studies is that this plant extract may decrease the activity of the Dopamine beta-hydroxylase enzyme that converts dopamine to norepinephrine dopamine, therefore by increasing in the process, the levels of dopamine increases. As a result of an increase in dopamine, the somatostatin hormone increases which is one of the main inhibitors of TSH, and thereby reduced TSH levels (29, 28).

In one study has shown that increased opioid compounds increase T3 hormone (30). Considering the stimulatory effect of Vitex on opioid receptors (7), in this study, may increase of thyroid hormone is applied through the stimulatory effect of this extract on opioid receptors. On the other hand due to the increase in the number of active thyroid follicles in the group receiving the VAC extract, Increase in serum levels of thyroid hormones may be due to increasing the activity of the active thyroid follicles. Flavonoids due to structural similarity with the T3 and T4 hormones, can influence by negative feedback on the performance of hypothalamic - pituitary (31). Considering the abundant flavonoid compounds in the Vitex extract Perhaps, reduction of TSH serum level in this study is also due to the presence of these compounds. Despite having follicle with squamous epithelium and high colloid volume in the thyroid gland represents the inactive follicles and follicles, with the epithelium of cubic cells and low colloid volume is indicative of active follicles. So smaller and the subsequent increase in the number of follicles is indicative of more activity the thyroid gland (26). Therefore, a significant

reduction in the volume of colloids in the group receiving the hydroalcoholic VAC extract, probably due to the increase in height of follicular epithelial cells of the thyroid tissue because overactive thyroid gland, increasing the number of active follicles But the volume is decreased, Therefore, increasing serum levels of thyroid hormones in the study due to an increase in the number of follicles with cubic epithelium and low colloid volume And thus increase the number of follicles activists. The results of the study showed that VAC extract reduces body weigh that are contrary to the results of the study Pirsavarany and colleagues (32).

According to the stimulatory effect of VAC extract on thyroid hormones secretion and the effect of this hormone on increment of body metabolism weight Loss in animals receiving the extract of this plant is not unexpected. The results of this study showed that VAC extract probably due to the increase in the number of total and active follicles in thyroid gland increases the thyroid hormones and reduces body weight and probably due to the impact of negative feedback of thyroid hormone reduces the TSH. Therefore, by doing additional research, the VAC extract can be use in hypothyroidism treatment.

Acknowledgments

Hereby, we would like to thank the Research Council of Islamic Azad University of Shiraz for financial support of this research.

References

1. Webster DE, Lu J, Chen SN, Farnsworth NR, Wang ZJ. Activation of the mu-opiate receptor by Vitex agnus castus methanol extracts: implication for its use in PMS. *J Ethnopharmacol.* 2006; 106(2): 216-21.
2. Ramezani M, Nasri S, Bahadoran H. The effects of vitex agnus castus total extract on spermatogenesis of balb/c mice. *Armaghane Danesh.* 2008;13(3):35-44.[In Persian].
3. Daniele C, Thompson Coon J, Pittler MH, Ernst E. Vitex agnus-castus: a systematic review of adverse events. *Drug Saf.* 2005;28(4): 319-32.
4. Ye Q, Zhang QY, Zheng CJ, Wang Y, Qin LP. Casticin, a flavonoid isolated from vitex rotundifolia, inhibits prolactin release in vivo and in vitro. *Acta Pharmacologica Sinica.* 2010; 31(12):1564-8.
5. Dugoua JJ, Seely D, Perri D, Koren G, Mills E. Safety and efficacy of chastetree (vitex agnus-castus) during pregnancy and lactation. *Can J Clin Pharmacol.* 2008;15(1):74-9.
6. Azadbakht M, Baheddini A, Shorideh S, Naserzadeh A. Effect of vitex agnus - castus L. leaf and fruit flavonoidal extracts on serum prolactin concentration. *J Med Plants.* 2005;4(16):56-61.[In Persian].
7. Donna EW, Ying H, Shao.-Nong C, Guido FP, Norman RF, Zaijie JW. Opioidergic mechanisms underlying the actions of vitex agnus-castus L. *Biochem Pharmacol.* 2011;81(1):170-7.
8. Jelodar G, Karami E. Effect of Hydroalcoholic extract of vitex agnus-castus fruit on ovarian histology in rat with induced polycystic ovary syndrome (PCOS). *J Babol Univ Med Sci.* 2013;15(3):96-102.
9. Zamani M, Neghab N, Torabian S. Therapeutic effect of vitex agnus castus in patients with premenstrual syndrome. *Acta Medica Iranica.* 2012;50(2):101-06.
10. Azarnia M, Ejtemaei-Mehr S, Shakoor A, Ansari A. Effects of vitex agnus castus on mice fetus development. *Acta Med Iranica.* 2007;45(4):263-70.
11. Honari N, Pourabolli I, Hakimizadeh E, Roohbakhsh A, Shamsizadeh A, Vazirinejad R, et al. Effect of vitex agnus castus extraction on anxiety-like behaviors in ovariectomized rats. *J Babol Univ Med Sci.* 2012; 14 (5):29-35.[In Persian]
12. Alimohamadi R, Naderi S, Imani E, Shamsizadeh A, Mobini M, Rezazadeh H, et al. The effects of the ethanolic extract of vitex agnus castus on stroke outcomes in ovariectomized mice. *J Babol Univ Med Sci.* 2015;17(3):20-7.[In Persian].
13. Hoermann R, Eckl W, Hoermann C, Larisch R. Complex relationship between free thyroxine and TSH in the regulation of thyroid function". *Eur J Endocrinol.* 2010;162(6):1123-29.
14. Bruel-Jungerman E, Davis S, Laroche S. Brain plasticity mechanisms and memory: a party of four. *Neuroscientist.* 2007; 13(5): 492-05.
15. Zhang L, Blomgren K, Kuhn HG. Effects of postnatal thyroid hormone deficiency on neurogenesis in the juvenile and adult rat. *Neurobiol Dis.* 2009;34(2):366-74.
16. Rodondi N, Aujesky D, Vittinghoff E, Cornuz J, Bauer DC. Subclinical hypothyroidism and the risk of coronary heart disease: a meta-analysis. *Am J Med.* 2006;119(7):541-51.
17. Cooper DS, Kilbanski A, Chester, Ridgway E. Dopamine modulation of TSH and its subunits in vitro a prospective, randomized, double-blind, placebo-controlled, crossover study. *J Herb Pharmacol.* 2005;5(4):1-11.
18. Hossini E, Sadeghi H, Daneshi A. Evaluation of Hydro-alcoholic extract of peganum harmala on Pituitary thyroid hormones in adult male rats. *J Yasoj Univ Med Sci.* 2010;14(4):23-30.
19. Mirazi N, Abdolmaleki N, Mahmoodi M. Study of salvia officinalis hydroethanolic extract on serum thyroid hormone levels in hypothyroid male rat. *Sci J Hamadan Univ Med Sci.* 2013; 19 (4):27-35.
20. Hosseini SE. The effect of disulfiram on serum levels of hormones in the pituitary-thyroid in adult male rats. *Sci J Hamadan Univ Med Sci.* 2013; 19(4):43-47.
21. Louei Monfared A, Hamoun Navard S. The effect of ethanol extracts of vitex on histomorphological placenta in the rat model. *Armaghane danesh.* 2014;19(7):614-24.[In Persian].
22. Abercrombie M, Johnson ML. Quantitative histology of wallerian degeneration: I. Nuclear population in rabbit sciatic nerve. *J Anat.* 1946;80(1): 37-50.
23. Kot BC, Lau TY, Cheng SC. Stereology of the thyroid gland in indo-pacific bottlenose dolphin (*Tursiops aduncus*) in comparison with human (*Homo sapiens*): quantitative and functional implications. *J PLoS One.* 2013;8(5):1-7.

24. Kitaichi Y, Inoue T, Izumi T, Nakagawa S, Tanaka T, Masui T. Effect of co-administration of a serotonin, noradrenaline reuptake inhibitor and a dopamine agonist on extracellular monoamine concentrations in rats. *Eur J Pharmacol.* 2008;584(2-3): 285-90.
25. Radetti G, Bernasconi S, Bozzola M, Volta C, Tonini G, Gentili L. Pyridostigmine and metoclopramide do not restore the TSH response to TRH inhibited by L-thyroxine treatment in children with goiter. *J Endocrinol Investigation.* 2000;23(11):744-7.
26. Bahar A, Akha O, Kashi Z, Vesgari Z. Hyperprolactinemia in association with subclinical hypothyroidism. *Caspian J Intern Med.* 2011; 2(2): 229–33.
27. Ye Q, Zhang QY, Zheng CJ, Wang Y, Qin LP. Casticin, a flavonoid isolated from *Vitex rotundifolia*, inhibits prolactin release in vivo and in vitro. *Acta Pharmacologica Sinica.* 2010;31(12):1564–68.
28. Lisboa PC, Oliveira KJ, Cabanelas A, Ortiga Carvalho TM, Pazos-Moura CC. Acute cold exposure, leptin, and somatostatin analog (octreotide) modulate thyroid 5'-deiodinase activity. *Am J Physiol Endocrinol Metab.* 2003;284(6):1172-6.
29. Grosicka E, Cieczot H, Skrzycki M, Szumiło M, Podsiad M, Rahden-Staron I. Effect of thiuram and disulfiram on the redox state of the cell fibroblasts, Chinese hamster lung. *Bromat Chem Toksykol.* 2006;4(1):383-90.
30. Gozashti MH, Mohammadzadeh E, Divsalar K, Shokoohi M. The effect of opium addiction on thyroid function tests. *J Diabet Metabolic Disorders.* 2014;13(1):5-10.
31. InKa H, Seidlova W, Wuttke W, Kohrle H. Effects of isoflavonoids and other plant-derived compounds on the hypothalamus pituitary thyroid hormone axis. *J Mathoritas.* 2006;55(1):14-25.
32. Pirsavarany M, Shiravy AH, Hydary nasrabady M. The Effects of aqueous extract of *vitex agnus castus* and *foeniculum vulgare* on HPG axis and spermatogenesis of male NMRI rat. *J Animal Biol.* 2011;4(1):7-18. [In Persian]