

The Effects of Tricyclazole on Hepatic Enzyme Changes and Tissue Damage in the Fetus of Laboratory Mice

T. Rowshanaie (MSc)¹, M. Sadoughi (PhD)¹, E. Fattahi (PhD)^{*2}

1. Department of biology, North Tehran Branch, Islamic Azad University, Tehran, I.R.Iran

2. Department of biology, Ayatollah Amoli Branch, Islamic Azad University, Amol, I.R.Iran

Received: Dec1st 2014, Revised: Feb4th 2015, Accepted: May 6th 2015

ABSTRACT

BACKGROUND AND OBJECTIVE: Tricyclazole is a popular Triazole pesticide used in agriculture to control rice blast disease. Due to the high consumption and stability of tricyclazole, as well as the digestive, nervous and hepatic disorders it may cause, this study aimed to investigate the effects of tricyclazole on hepatic enzyme changes and tissue damage in the fetus of laboratory mice.

METHODS: For this experimental study, 30 mice (10 male, 20 female) with the age range of 10-12 weeks were purchased from Pasteur Institute, Northern branch, Iran. After mating and confirmation of pregnancy using a vaginal plaque, the mice were randomly divided into three groups of control (N=6), experiment I (N=7) and experiment II (N=7). In the experimental groups, the mice received tricyclazole via intraperitoneal injection at doses of 0.5 and 1.5 mg/kg, respectively, while the control group received no toxins. All the animals were preserved under optimum conditions, and at day 17 of gestation, they were killed, and the fetuses were removed from the body of the mothers. Sampling of hepatic tissues was performed to count fetal hepatocytes and evaluate tissue damage. In addition, enzyme levels of Alanine aminotransferase (ALT), Aspartate aminotransferase (AST) and Alkaline phosphatase (ALP) were measured via the colorimetric method using the enzyme kit made by Cayman company.

FINDINGS: In this study, microscopic evaluation showed a significant increase in the number of hepatocytes in experimental group I (21.35 ± 0.85) and experimental group II (23.1 ± 1.16) compared to the control group (16.9 ± 1.2) ($p < 0.05$). Moreover, levels of ALT and AST were higher in the experimental groups compared to the control group, while the level of ALP was observed to decrease in both groups ($p < 0.05$). According to histopathological studies, concentrations of tricyclazole in the liver could lead to necrosis, inflammatory cell infiltration, hyperplasia, watery degeneration of hepatocytes and severe hepatomegaly.

CONCLUSION: According to the results of this study, enzymatic changes and hepatic tissue damage are dose-dependent processes, and tricyclazole could irreversibly disrupt the metabolic system of the body.

KEY WORDS: Tricyclazole, Hepatic Enzymes, Hepatocyte.

Please cite this article as follows:

Rowshanaie T, Sadoughi M, Fattahi E. The Effects of Tricyclazole on Hepatic Enzyme Changes and Tissue Damage in the Fetus of Laboratory Mice. J Babol Univ Med Sci. 2015;17(7):51-7.

*Corresponding Author: E. Fattahi (PhD)

Address: Ayatollah Amoli Branch, Islamic Azad University, Amol to Babol Ave, Amol, I.R.Iran

Tel: +98 11 43217320

E-mail: esmail_fattahi@yahoo.com

Introduction

In recent years, various pesticides have been used in agriculture in order to eliminate plant diseases, as well as to increase products. However, there are major concerns about the environmental and health hazards caused by these pesticides. Due to the aberrant and unreasonable use of pesticides by farmers, and because of the stability of these substances in the environment, different side effects have been attributed to pesticides. The adverse effects of these toxins could be a result of long-term or short-term exposure, which mostly affect agricultural producers and consumers, such as farmers and orchard owners (1-3).

Tricyclazole is a popular pesticide, which is widely used in the northern regions of Iran. Tricyclazole is a systemic fungicide of the Triazole family, and is normally used to control rice blast disease (4, 5). This toxin is known as a major contaminator of the environment, water and food, and has a high stability in the environment. According to several studies, tricyclazole could remain in soil for more than 11 months, and is immediately absorbed by skin and mucous membranes upon exposure (6).

Severity of the damage caused by pesticides depends on the type of absorption, metabolites and cellular structure the compounds (7). Tricyclazole fungicides could disrupt the function of different body organs, such as the liver, through the inhibition of cytochrome CYP450 and cholesterol synthesis (8). Several studies have confirmed the adverse effects of these toxins on hepatic enzymes, such as cytochromes, which could lead to changes in the activity of these enzymes causing cellular irritation and proliferation (9).

In a study by Sancho et al., it was reported that tricyclazole could increase the serum levels of triglyceride, glucose and lactate, while causing no changes in serum total protein. Furthermore, this toxin was observed to increase the activity of other enzymes including alanine aminotransferase (ALT), aspartate aminotransferase (AST), and lactate dehydrogenase (LDH), and decrease the levels of alkaline phosphatase (ALP) (10).

Tricyclazole affects other tissues as well, including the testicles; the toxins could increase testosterone levels, weight of the testicles, diameters of seminiferous tubules, number of blood vessels and the lumen space (11).

A number of reports have noted that tricyclazole could break chemical bonds and cause cell damage by producing free radicals and reactive oxygen species with lipids, proteins and nucleic acids. Moreover, membrane lipid peroxidation and cell death induction are among other complications caused by these toxic components (12). As the largest gland in the body, the liver plays a pivotal role in the metabolism of drugs, toxins and harmful compounds (13).

Although such compounds are converted into harmless materials in the liver and are mostly excreted from the body, the remnants of these toxins could have several adverse effects on the function and structure of body tissues, including the liver. Given the importance of liver in the conversion of potentially toxic compounds, this study aimed to investigate the effects of tricyclazole on hepatic tissue damages and enzymatic changes.

Methods

Animals under Experiment: In this experimental study, 30 laboratory mice (10 male, 20 female) weighing between 30-35 grams (age: 10-12 weeks), were purchased from Pasteur Institute, Northern branch, Iran. The animals were kept in standard cages at the temperature of $23 \pm 2^\circ\text{C}$ with the humidity of 50-55%, within a photocycle of 12 hours of light and 12 hours of darkness. The mice had free access to adequate food and water.

For mating, each of the male animals was placed in a cage with two females, and after the confirmation of pregnancy using a vaginal plaque, the mice were randomly divided into three groups of control (N=6), experimental group I (N=7) and experimental group II (N=7).

In this study, tricyclazole was used with 95% purity, produced by Gorgan Gol-Sam Company. Desired concentrations of the pesticide were prepared from tricyclazole in distilled water, and the animals received daily injections at a specific time.

Experimental groups I and II received frequent doses of tricyclazole (0.5 and 1.5 mg/kg, respectively) via intraperitoneal injections, while the control group received none. All the animals were preserved under optimum conditions and were killed at day 17 of gestation. Afterwards, the fetuses were removed from the body of the mothers, and samples were obtained. For the histological evaluation, parts

of the liver were removed from the fetuses, and were fixated in 10% formalin. Following that, serial histologic sections (thickness: 5 microns) were prepared and stained using Hematoxylin and Eosin (H & E) method. In each group, 100 sections, consisting of all parts of the liver, were evaluated, and hepatocytes were counted using Zeiss optical microscope, equipped with a rectangular, graded page (dimensions: 25 × 15 mm, surface: 375 mm²).

In addition, histopathological evaluations were performed on the prepared tissue sections. In order to measure the enzymatic activities of ALT, AST and ALP, parts of the hepatic tissues were homogenized with 17 mM phosphate buffer solution at 14,000 rpm and were measured using the colorimetric method and kit enzyme made by Cayman Company, America. Moreover, ANOVA test was used to evaluate the research hypothesis, and Tukey’s test was used for the comparison of the mean differences between the study groups. In this study, p<0.05 was considered significant.

Findings

Number of Hepatocytes: Microscopic examinations of the hepatic sections were indicative of a significant increase in the number of hepatocytes in both experimental groups compared to the control group, and the increase in experimental group II was considered to be statistically significant (p<0.05) (table 1).

Table 1. Comparison of Mean Hepatic Enzymes and Hepatocytes in the Experimental and Control Groups

Groups Parameter	Control Mean±SE	Experimental I(0.5mg/kg) Mean±SE	Experimental II(1.5mg/kg) Mean±SE
ALT(IU/L)	221±72c	258b±610	1401±265a
AST(IU/L)	262.3±12a	303.3±59.5b	892±225a
ALP(IU/L)	188±8a	108±22b	92±5.1b
Number of Hepatocytes (mm ²)	9.16±2.1a	35.21±85b	16.1a±1.23

The mean values in each row, with at least one letter in common, had no significant difference (p<0.05).

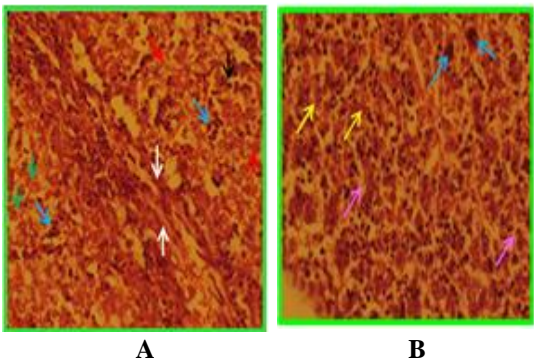
Measurement of Hepatic Enzymes: After the experiments, assessment of hepatic enzyme factors indicated that tricyclazole could cause changes in

enzymatic activities of the liver. In this study, ALT had a significant increase in the experimental groups compared to the control group (p<0.05).

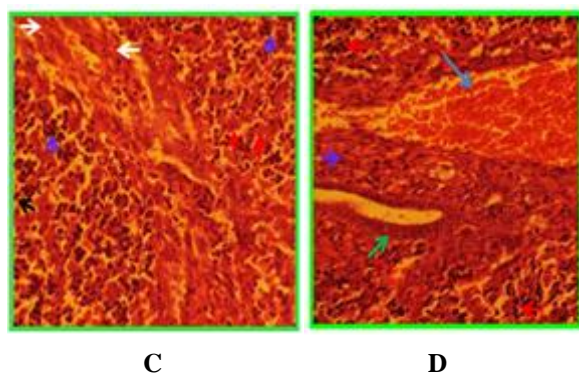
The increase in experimental group II (dose: 1.5 mg/kg) was more significant than experimental group I (0.5 mg/kg). In addition, AST levels in the experimental groups had a significant increase compared to the control group (p<0.05), while ALP had a significant decrease in the experimental groups compared to the control group (p<0.05) (table 1).

Evaluation of Hepatic Tissue Damage:

Histopathological changes were observed during the assessment of hepatic tissues of the fetuses treated with 0.5 mg/kg of tricyclazole (experimental group I). Moreover, changes in the number of hepatocytes were manifested as necrosis and watery type of degeneration. Among other damages caused by tricyclazole injection was the infiltration of inflammatory cells and fibrosis in the hepatic tissues (fig 1). Furthermore, an increase was observed in the number of Kupffer cells within the structure of tissues. Evaluation of the tissue sections in experimental group II, which received 1.5 mg/kg of the toxin intraperitoneally, was indicative of extensive hepatic damages (e.g. necrosis and watery degeneration of hepatocytes) (fig 1), and fibrosis in the triad. One of the most important changes in the fetuses was bile duct hyperplasia, which was detected in the experimental group receiving 1.5 mg/kg of the toxin. Regarding the destructive effects of tricyclazole at high doses, the number of Kupffer cells in the hepatic tissues of experimental group II had a more significant increase compared to group I (fig 1).



A) Control Group: Normal tissues, Hepatocytes (yellow arrow), Sinusoids (pink arrow), Megakaryocyte (blue arrow); B) Experimental Group I: Fibrosis (white arrow), Mononuclear inflammatory cell infiltration (blue arrow), Watery cell degeneration (green arrow), Necrosis of hepatocytes (red arrow), Kupffer cells (black arrow);



C) Experimental Group II: Fibrosis of hepatic tissues (purple arrow), Bile duct hyperplasia (green arrow), Hyperemia (blue arrow), Inflammatory cell infiltration (orange arrow); D) Experimental Group II: Severe fibrosis in hepatic tissues (white arrow), Inflammatory mononuclear cell infiltration (purple arrow), Necrosis in hepatocytes (red arrow), Kupffer cells (black arrow).

Figure 1. Photo Micrographs of Hepatic Sections in 17-day Fetuses, stained by H & E Method (magnification: 400)

Discussion

In the present study, administration of tricyclazole caused a significant increase in the levels of ALT and AST in both experimental groups compared to the control group. However, the level of ALP decreased in the experimental groups, which received the toxin, compared to the control group. In addition, the number of hepatocytes was observed to increase in the experimental groups compared to the control group, and hepatic tissue damages were detected after the injection of tricyclazole.

These hepatic changes were manifested as necrosis, watery degeneration of hepatocytes, fibrosis in the triad, bile duct hyperplasia, and increased number of Kupffer cells, especially in the mice receiving higher doses of the toxin. According to several studies, azole antifungal agents could enter the fetus by causing damage to the placenta, and bring about birth defects, death or tissue damages. Apparently, tricyclazole is able to harm the fetus through crossing the same pathway in the placenta (14, 15).

Although tricyclazole is converted into active metabolites in hepatic tissues, it should be noted that the liver has limited function in the transformation of these compounds. Therefore, structural and

functional disorders are expected in hepatic tissues in case of severe exposure to these toxins (13). According to several reports, triazoles are able to increase the proliferation and number of cells through the activation of anti-apoptotic growth arrest and DNA damage inducible genes, and nuclear receptors of CAR-regulated genes, such as CYP2B2. Furthermore, these toxins could cause hepatic damages and hepatomegaly; therefore, these compounds are considered to have several hepatotoxic properties (16-18).

In this study, the increase observed in the number of hepatocytes could be due to the toxic effects of tricyclazole on the activation of these genes, which resulted in the induction of cell division and increased number of hepatocytes. On the other hand, the results of the present study showed a significant increase in the levels of ALT and AST, which is compatible with the findings of Sancho et al. (10); several studies have confirmed that triazole compounds could increase the levels of ALT and AST, while causing considerable hepatic damages (19, 20). A number of studies have suggested that hepatic tissue damages are caused without oxidative stress. Another important finding of the current study was the reduction observed in the level of ALP, which was indicative of the dose-dependent negative effects of tricyclazole. Accordingly, by increasing the concentration of this toxin, ALP enzyme levels could decrease more significantly. There are conflicting results on the changes in ALP levels; while some researchers believe that triazoles reduce the levels of this enzyme (10), others claim that these toxins could increase ALP levels (19-21).

The decrease in the levels of ALP could be due to the hyperplasia of bile ducts. On the other hand, increased levels of transaminases resulted in hepatic tissue damages in the current study. Moreover, the occurrence of histopathological changes in hepatic tissues after the use of tricyclazole are indicative of the degeneration of hepatic cells, caused by necrosis and membrane damage in these cells, which lead to the release of AST and ALT, as well as a significant increase in the levels of these enzymes. These enzymes are naturally found in hepatic cells and are considered as proper criteria for the assessment of hepatic damages. ALT and AST are released due to the damage of cell membranes and necrosis of hepatic cells, and their levels are likely to increase in

the plasma; this process signifies the vulnerability of hepatic tissues (13). Increased levels of transaminase enzymes in the present study could be due to tissue damages, necrosis and watery degeneration of hepatocytes. Furthermore, administration of tricyclazole was observed to increase the number of Kupffer cells. These cells are the mature macrophages found in hepatic sinusoids, and given the key role of these cells in phagocytosis (22), increased number of Kupffer cells might be associated with the digestion of necrotic cells, which is caused by the injection of this toxin.

In conclusion, the results of the present study indicated that changes of hepatic enzymes, as well as hepatic damages, are dose-dependent processes. Moreover, tricyclazole could lead to irreversible disruptions in the metabolic system of the body.

Acknowledgements

Hereby, we extend our gratitude to Pasteur Institute of Amol, Iran for supporting this study. We would also like to thank Dr. Assuri and Dr. Ahmadi for their cooperation in this research project.

References

1. Fattahi E, Parivar K, Jorsaraei SGhA, Moghadamnia AA. The effects of diazinon on testosterone, FSH and LH levels and testicular tissue in mice. *Iran J Reprod Med*. 2009; 7(2):59-64.
2. Fattahi E, Jorsaraei Gh, Gardaneh M. The effect of Carbaryl on the pituitary-gonad axis in male rats. *Iran J Reprod Med*. 2012; 10(5):419-24.
3. Vittozzi L, Fabrizi L, Di Consiglio E, Testai E. Mechanistic aspects of organophosphorothionate toxicity in fish and humans. *Environ Int*. 2001; 26(3):125-129.
4. Georgopapadakou NH, Walsh TJ. Antifungal agents: chemotherapeutic targets and immunologic strategies. *Antimicrob Agents Chemother*. 1996;40(2):279-91.
5. Padovani L, Capri E, Padovani C, Puglisi E, Trevisan M. Monitoring tricyclazole residues in rice paddy watersheds. *Chemosphere*. 2006;62(2):303-14.
6. Jeong SA, Thapa SP, Park HR, Choi NG, Hur JH. Distribution and Persistence of Tricyclazole in Agricultural Field Soils. *Bull Environ Contam Toxicol*. 2012;89:1181-1185
7. Fattahi E, Mosavi Moghaddam M, Khanbabaei RA. The effect of tricyclazole on testosterone changes and testicular structure in mice. *J Babol Univ Med Sci*. 2015;17(2):43-9.[In Persian]
8. Iglesias J, Gibbons GF. Regulation of hepatic cholesterol biosynthesis. Effects of a cytochrome P-450 inhibitor on the formation and metabolism of oxygenated sterol products of lanosterol. *Biochem J*. 1989;264(2):495-502.
9. Butterworth BE, Conolly RB, Morgan KT. A strategy forestablishing mode of action of chemical carcinogens as a guide for approachesto risk assessments. *Cancer Lett*. 1995;93(1):129-46.
10. Sancho E, Fernández-Vega C, Villarroel MJ, Andreu-Moliner E, Ferrando MD. Physiological effects of tricyclazole on zebrafish (*Danio rerio*) and post-exposure recovery. *Comp Biochem Physiol C Toxicol Pharmacol*. 2009;150(1):25-32.
11. Fattahi E. Sublethal effects of tricyclazole fungicide in male mice, the structure of the testis and testosterone levels studies. *Int J Biosci*. 2015;6(4):92-8.
12. Bagchi D, Bagchi M, Hassoun EA, Stohs SJ. In vitro and in vivo generation of reactive oxygen species, DNA damage and lactate dehydrogenase leakage by selected pesticides. *Toxicology*. 1995;104(1-3):129-40.
13. Fattahi E, Forozanfar M, Bagheri Haghighi A. Effect of 3,4 methylendioxy meth amphetamine on hepatocyte and liver enzymes Wistar Rats. *J Gorgan Univ Med Sci*. 2013;14(4):24-9.[In Persian]
14. Rey Moreno MC, Fussell KC, Gröters S, Schneider S, Strauss V, Stinchcombe S, et al. Epoxiconazole-induced degeneration in rat placenta and the effects of estradiol supplementation. *Birth Defects Res B Dev Reprod Toxicol*. 2013;98(3):208-21
15. Lee VCY, Gao J, Lee KF, Ng EHY, Yeung WSB, Ho PC. The effect of letrozole with misoprostol for medical termination of pregnancy on the expression of steroid receptors in the placenta. *Human Reprod*. 2013;28(11):2912-9.
16. Goetz AK, Bao W, Ren H, Schmid HE, Tully DB, Wood C, et al. Gene expression profiling in the liver of cd-1 mice to characterize the hepatotoxicity of conazole fungicides. *Toxicol Appl Pharmacol*. 2006;215(3):274-84.
17. Allen JW, Wolf DC, George MH, Hester SD, Sun G, Thai SF, et al. Toxicity profiles in mice treated with hepatotumorigenic and non-hepatotumorigenic triazoleconazole fungicides: propiconazole, triadimefon, and myclobutanil. *Toxicol Pathol*. 2006;34(7):853-62.
18. Hurley PM. Mode of carcinogenic action of pesticides inducing thyroid follicular cell tumors in rodents. *Environ Health Perspect*. 1998;106(8):437-45.

19. Kimura M, Yamagishi Y, Kawasumi N, Hagihara M, Hasegawa T, Mikamo H. [Clinical implication of therapeutic drug monitoring on voriconazole from the aspect of the analysis for CYP2C19 gene]. *Jpn J Antibiot.* 2010;63(3):255-64.
20. Aydin M, Oktar S, Ozkan OV, Alçin E, Oztürk OH, Nacar A. Letrozole induces hepatotoxicity without causing oxidative stress: the protective effect of melatonin. *Gynecol Endocrinol.* 2011;27(4):209-15.
21. Somchit N, Norshahida AR, Hasiah AH, Zuraini A, Sulaiman MR, Noordin MM. Hepatotoxicity induced by antifungal drugs itraconazole and fluconazole in rats: a comparative in vivo study. *Hum Exp Toxicol.* 2004;23(11):519-25.
22. Bagheri Haghighi A, Fattahi E, Forozanfar M, Hemayatkah Jahromi V. Effects of 3,4-methylenedioxy methamphetamine (ecstasy) on rat liver structure. *Koomesh.* 2012;13(3):368-74. [In Persian]