Journal of
Babol University of Medical Sciences
JBUMS
e-ISSN: 2251-7170 p-ISSN: 1561-4107

The Frequency of Odontogenic Cysts and Tumors and Their Association with Impacted Teeth

N. Effatizadeh (DDS)[1], Z. Zolfaghari Saravi (DDS, MS)[2], S. Seyedmajidi (PhD)[3], M. Seyedmajidi (DDS, MS)[*3]

1.Student Research Committee, Babol University of Medical Science, Babol, I.R.Iran.
2.Oral Health Research Center, Health Research Institute, Babol University of Medical Science, Babol, I.R.Iran.
3.Dental Materials Research Center, Health Research Institute, Babol University of Medical Sciences, Babol, I.R.Iran.

[*]Corresponding Author: M. Seyedmajidi (DDS, MS)
Address: Dental Materials Research Center, Health Research Institute, Babol University of Medical Sciences, Babol, I.R.Iran.
Tel: +98 (11) 32291408. **E-mail:** ms_majidi79@yahoo.com

Article Type
Research Paper

ABSTRACT

Background and Objective: Odontogenic cysts and tumors are common and complex lesions of the jaw that are occasionally associated with impacted teeth and possess the potential to cause serious complications. The present study was conducted with the aim of investigating the frequency of odontogenic cysts and tumors and their association with impacted teeth over an 11-year period.

Methods: In this cross-sectional study, all medical records of the Department of Oral and Maxillofacial Pathology of Babol Dental School from 2012 to 2022 were reviewed. Patients' demographic characteristics, lesion location, involved impacted tooth, clinical and radiographic features of the lesion, clinical and radiological differential diagnosis, histopathological diagnosis, type of biopsy, and macroscopic characteristics of the lesions were extracted from the records and evaluated.

Findings: Of the 1512 samples examined, 428 cases (28.3%) were diagnosed as odontogenic lesions (85% odontogenic cysts and 15% odontogenic tumors). The majority of patients (54.4%) were male. The mean age of patients with cysts was 33.02±15.31 years, and that of patients with tumors was 32.53±16.08 years (p=0.819). Most lesions (27.1%) were observed in the third decade of life, and the majority of lesions (92.3%) exhibited a radiolucent appearance. Seventy-five percent of odontogenic tumors and 61.8% of odontogenic cysts were found in the mandible (p=0.043). The most common odontogenic cysts were radicular cyst, dentigerous cyst, and odontogenic keratocyst, and the most common odontogenic tumors were ameloblastoma and complex odontoma. The most common lesion in the age group under 20 years was dentigerous cyst, and in the age group 21 years and older, it was radicular cyst. 31.5% of the lesions were associated with impacted teeth, and the most common impacted tooth was the third molar, with a frequency of 58.2%. The clinical and radiological diagnosis was consistent with the histopathological diagnosis in 292 cases (68.2%).

Conclusion: The results of the present study showed that odontogenic lesions have a considerable frequency, and many lesions were observed in association with impacted teeth. Therefore, the presence of an impacted tooth can be considered a potential risk factor for the presence of odontogenic lesions.

Received:
Apr 30th 2025
Revised:
Jun 21st 2025
Accepted:
Jul 29th 2025

Keywords: *Odontogenic Cyst, Odontogenic Tumor, Impacted Tooth, Frequency*.

Cite this article: Effatizadeh N, Zolfaghari Saravi Z, Seyedmajidi S, Seyedmajidi M. The Frequency of Odontogenic Cysts and Tumors and Their Association with Impacted Teeth. *Journal of Babol University of Medical Sciences*. 2026; 28: e54.

Copyright © 2024 Babol University of Medical Sciences. Published by Babol University of Medical Sciences. This work is licensed under a Creative Commons Attribution-NonCommercial 4.0 International license (https://creativecommons.org/licenses/by-nc/4.0/). Noncommercial uses of the work are permitted, provided the original work is properly cited.

Introduction

The human jaw is a common site for the occurrence of a wide range of cysts and tumors (1). Odontogenic cysts are recognized as important and relatively common lesions of the oral cavity and comprise 90% of jaw cysts (2). Therefore, awareness of their clinical, radiographic, and histopathological features, characteristics, and differential diagnosis from other pathological lesions of the mouth is of great importance (3). Despite similar histopathological appearances, odontogenic cysts exhibit different clinical behaviors (4, 5). They arise from the odontogenic epithelial component or its remnants trapped within the jawbones or gingival tissue (6, 7). Odontogenic cysts can cause bone expansion, tooth mobility, fistula formation, pain, and paresthesia (2).

Some odontogenic cysts, such as odontogenic keratocyst, calcifying odontogenic cyst, and glandular odontogenic cyst, exhibit aggressive behavior and a tendency to recur, and some cysts, such as odontogenic keratocyst, even exhibit tumor-like behavior (8). The incidence rate of malignancy in odontogenic cysts ranges from 0.13% to 3%. The most common symptoms in these malignant tumors are pain and swelling; however, in some cases, the patient may be asymptomatic, and the lesion may be discovered incidentally through a panoramic dental radiograph. Unfortunately, the absence of symptoms leads to a delay in clinical diagnosis, which complicates the prognosis of malignancy (9). Treatment of cysts in the jaw involves one of four fundamental methods: enucleation, marsupialization, a combination of enucleation and marsupialization, or resection (10). Treatment of patients with carcinoma originating from a cyst varies from local surgery to extensive surgery, with or without radiotherapy and chemotherapy (11).

Odontogenic tumors are a group of odontogenic lesions with diverse histopathological features and clinical manifestations that comprise only about 1% of all jaw lesions (12). Some of them are true neoplasms that may rarely be malignant, and some may be tumor-like malformations or hamartomas (11). Most odontogenic tumors are benign and arise primarily. Malignant odontogenic cysts and tumors may also arise primarily, but they often develop from their benign precursors (13). Diagnostic challenges of malignant odontogenic tumors arise due to histopathological similarities with their benign counterparts and limitations in the type of biopsy incisions that do not represent the entire tumor, which leads to misdiagnosis in the initial histopathological sample (14). The treatment of choice for odontogenic tumors is surgery; for the benign type, complete tumor removal and curettage, and for the malignant type, radical surgery including partial bone resection. If these lesions are left untreated, they can lead to death within a few months after diagnosis (15). The frequency of odontogenic lesions has been reported in various studies as approximately 10–20% of all lesions (1, 12, 13).

Odontogenic lesions are sometimes associated with impacted teeth, and the prophylactic removal of impacted teeth, particularly impacted third molars, remains a subject of debate in dentistry (16). Intraoperative and postoperative complications of impacted third molar surgery are among the primary reasons for surgeons' hesitation to extract asymptomatic impacted teeth (17). Due to their proximity to anatomical structures, impacted teeth have the potential to cause serious problems, including the development of pathological lesions (18). The follicle surrounding the crown of an impacted tooth may lead to the formation of cysts and tumors such as dentigerous cyst, keratocystic odontogenic tumor, and ameloblastoma (19). Histopathological examination is the gold standard for the diagnosis of lesions, and studies have shown that the most common odontogenic lesion associated with impacted teeth is dentigerous cyst (18-20).

In several studies, the highest prevalence of cysts and tumors associated with impacted teeth has been observed in the third decade; however, a strong relationship has been observed between increasing age and the presence of significant pathological lesions associated with impacted teeth (20). Therefore, informing dentists about this phenomenon and emphasizing the importance of early diagnosis and intervention to prevent possible harmful consequences is of great importance.

Given the varying frequency of odontogenic lesions across different studies and the importance of the association of odontogenic lesions with impacted teeth in terms of causing various complications for patients, the aim of the present study is to investigate the frequency of odontogenic cysts and tumors and their association with impacted teeth in the Department of Oral and Maxillofacial Pathology of Babol Dental School during the years 2012 to 2022.

Methods

After approval by the Ethics Committee of Babol University of Medical Sciences under code IR.MUBABOL.REC.1402.085, this cross-sectional study was conducted on all patient records referred to the Department of Oral and Maxillofacial Pathology of Babol Dental School from 2012 to 2022. Data collection was performed using a data sheet. Patients with a definitive diagnosis of odontogenic lesion were included in this study. Patient records were extracted from their files. The necessary information, including patients' age and sex, lesion location, involved impacted tooth, clinical and radiographic features of the lesion, clinical and radiological differential diagnosis, histopathological diagnosis, type of biopsy, macroscopic characteristics of the lesion including size (largest dimension of the lesion), color and consistency of the lesion, color and type of cross-sectional surface of the lesion on macroscopic view, referring center for biopsy, and specialty of the referring individual, was extracted from the records. The obtained data were statistically analyzed using SPSS version 26 and T-test, chi-square, and Fisher's exact test, and $p<0.05$ was considered significant.

Results

In the present study, 1512 records from 2012 to 2022 were examined to investigate the frequency of odontogenic cysts and tumors, of which 428 records (28.3%) were diagnosed as odontogenic lesions. Of these lesions, 364 cases (85%) were odontogenic cysts and 64 cases (15%) were odontogenic tumors. The mean age of patients was 32.96±15.5 years, and 233 cases (54.4%) of the lesions were related to male patients. The mean age of patients with cysts was 33.02±15.31 years, while the mean age of patients with tumors was 32.53 ± 16.08 years; based on the results, no significant difference was observed between the mean ages of the two groups. Furthermore, the most frequent age group presenting was the third decade, with a frequency of 116 cases (27.1%). The third decade of life accounted for the highest number of patients with odontogenic cysts, while odontogenic tumors had the highest number of patients equally in the third and fourth decades of life. 225 records (52.6%) were referred from various departments of Babol Dental School, 117 records (27.3%) from private offices, and 86 records (20.1%) from hospitals. 422 cases (98.6%) of the records were referred by specialist dentists. Of the 225 records referred from the Dental School, 168 were from the Surgery Department, 14 from the Endodontics Department, 2 from the Oral and Maxillofacial Diseases Department, and 41 from other departments.

312 cases (72.9%) of the lesions were biopsied as excisional and 116 cases (27.1%) as incisional. Of the 353 odontogenic cysts, 51% were of the developmental type and 49% were of the inflammatory type (11 odontogenic cysts were not included in this classification due to the lack of a definitive diagnosis of the cyst type). The most common odontogenic cysts were, in order, radicular cyst, dentigerous cyst, and odontogenic keratocyst (Table 1). 61.5% (56 cases) of the dentigerous cysts were inflammatory, of which 42.8% (24 cases) were reported around the permanent successor tooth at the site of a non-vital primary tooth.

Of the 64 odontogenic tumors, 55% were epithelial odontogenic tumors, 36% were mixed odontogenic tumors, and 9% were tumors of odontogenic ectomesenchymal origin. The most common odontogenic tumors in this study were, in order, ameloblastoma with all its variants and complex odontoma (Table 2). 50% (10 cases) of the complex odontoma samples were reported as tumors surrounded by a dentigerous cyst.

Table 1. Frequency of odontogenic cysts and tumors according to lesion type

Lesion type	Lesion name	Number(%)
Odontogenic cyst type (n=364)	Radicular cyst	156(42.9)
	Dentigerous cyst	91(25)
	Odontogenic keratocyst	73(20.1)
	Residual cyst	16(4.4)
	Glandular odontogenic cyst	8(2.2)
	Calcifying odontogenic cyst	5(1.4)
	Lateral periodontal cyst	3(0.8)
	Orthokeratinized odontogenic cyst	1(0.3)
	Odontogenic cyst*	11(3)
Odontogenic tumor type (n=64)	Solid ameloblastoma	10(15.6)
	Unicystic ameloblastoma	16(25)
	Peripheral ameloblastoma	1(1.6)
	Complex odontoma	20(31.3)
	Adenomatoid odontogenic tumor	4(6.3)
	Calcifying epithelial odontogenic tumor	4(6.3)
	Odontogenic myxoma	4(6.3)
	Ameloblastic fibroma	3(4.7)
	Cementoblastoma	2(3.1)

***An odontogenic cyst that lacks a definitive diagnosis due to insufficient sample volume or failure to submit supplementary characteristics of the lesion.**

Table 2. Frequency of odontogenic cysts and tumors according to lesion type in the age group under 20 years

Lesion type	Lesion name	Number(%)
Odontogenic cyst (n=72)	Dentigerous cyst	38(52.8)
	Radicular cyst	20(27.8)
	Odontogenic keratocyst	8(11.1)
	Calcifying odontogenic cyst	3(4.2)
	Lateral periodontal cyst	1(1.4)
	Odontogenic cyst	2(2.8)
Odontogenic tumor (n=14)	Complex odontoma	8(57.1)
	Unicystic ameloblastoma	4(28.6)
	Ameloblastic fibroma	2(14.3)

Based on the findings, the clinical and radiological diagnosis was consistent with the histopathological diagnosis in 292 records (68.2%). Furthermore, the consistency of the pathological diagnosis with the clinical and radiological diagnosis did not differ between cysts and tumors. 282 records (71.8%) were consistent with the first or second clinical and radiological diagnosis, and 10 records (2.3%) were consistent with the third or other clinical and radiological diagnoses.

Ameloblastic changes were reported in 4 odontogenic cysts, and dysplastic changes were found in 2 odontogenic cysts (one case of residual cyst and one case of odontogenic cyst whose definitive diagnosis was not possible due to insufficient sample volume and lack of access to clinical and radiographic information). Carcinomatous changes were reported in three odontogenic lesions, which were related to two cysts (one case of dentigerous cyst and one case of odontogenic cyst whose type could not be determined) and one odontogenic tumor (ameloblastoma, due to the presence of foci of malignant cells within it). 86 odontogenic lesions were observed in the age group under 20 years, which included 72 odontogenic cysts and 14 odontogenic tumors, and 342 odontogenic lesions were reported in the age group 21 years and older, which included 292 odontogenic cysts and 50 odontogenic tumors. Based on the findings, there was no statistically significant difference between the frequency of odontogenic cysts and tumors when stratified by age group under 20 years and 21 years and older.

The most common odontogenic cyst in the age group under 20 years was dentigerous cyst, and the most common odontogenic tumor was complex odontoma (Tables 3 and 4).

Table 3. Frequency of odontogenic cysts and tumors according to the involved jaw, involved side, and involved region

Variable	Cyst Number(%)	Tumor Number(%)	p-value*
Involved jaw			
Maxilla	139(89.7)	16(10.3)	*0.04
Mandible	225(82.4)	48(17.8)	
Involved side			
Right	168(85.7)	28(14.3)	
Left	162(85.7)	27(14.3)	*0.511
Both	34(79.1)	9(20.9)	
Involved region			
Anterior	97(90.7)	10(9.3)	
Posterior	231(83.4)	46(16.6)	*0.16
Both	36(81.8)	8(18.2)	

***Chi-square test**

Table 4. Frequency of lesion type according to clinical characteristics

Variable	Cyst Number(%)	Tumor Number(%)	p-value*
Pain	64(17.6)	7(15)	0.188*
Soft tissue swelling	73(20.1)	20(31.3)	0.045*
Bony swelling	85(23.4)	30(46.9)	<0.001*
Mucosal erythema	3(0.8)	1(1.6)	0.478**
Purulent discharge	55(15.1)	2(3.1)	0.008**
Fluid discharge	81(22.3)	13(20.3)	0.730*
Tooth mobility	7(1.9)	5(7.8)	0.008*
Displacement of erupted teeth	14(3.8)	6(9.4)	0.053

***Chi-square test, **Fisher's exact test**

The most common odontogenic cysts in the age group 21 years and older were, in order, radicular cyst with a frequency of 136 cases (46.6%), odontogenic keratocyst with a frequency of 65 cases (22.3%), and dentigerous cyst with a frequency of 53 cases (18.2%). Based on the results, there was a statistically significant difference between the frequency of odontogenic cysts when stratified by age group under 20 years and 21 years and older, with odontogenic cysts being more frequent in the age group 21 years and older ($p<0.001$). The most common odontogenic tumors in the age group 21 years and older were, in order, ameloblastoma with all its variants with a frequency of 23 cases (46%) and complex odontoma with a frequency of 12 cases (24%). Based on the results, there was no statistically significant difference between the frequency of odontogenic tumors when stratified by age group under 20 years and 21 years and older.

There was a significant relationship between the frequency of odontogenic cysts and tumors and the involved jaw, such that 75% of odontogenic tumors arose in the mandible, whereas 61.8% of odontogenic cysts were found in the mandible ($p=0.04$). Based on the results, the most common location of odontogenic cysts and tumors was reported to be the posterior mandible. The findings showed that the most common location of radicular cyst, dentigerous cyst, odontogenic keratocyst, ameloblastoma, and complex odontoma was the posterior mandible. After the posterior mandible, the most common location of radicular cyst was the anterior maxilla. Figures 1 and 2 show the relative distribution of the location of the most common lesions.

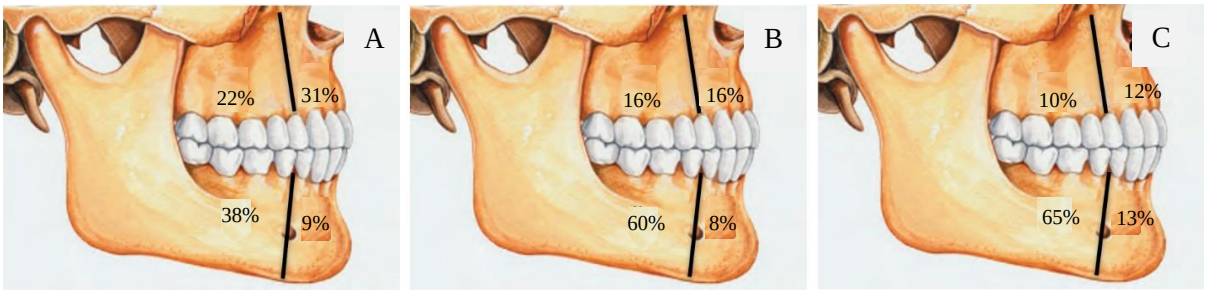

Figure 1. Relative distribution of the location of the most common odontogenic cysts in the jaws: (A) radicular cyst; (B) dentigerous cyst; (C) odontogenic keratocyst

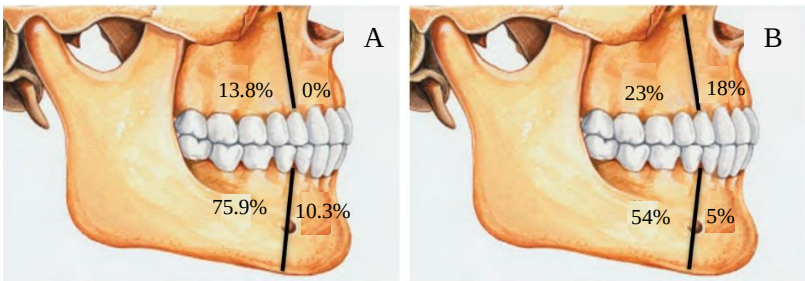

Figure 2. Relative distribution of the location of the most common odontogenic tumors in the jaws: (A) ameloblastoma; (B) complex odontoma

Soft tissue swelling, bony swelling, and tooth mobility were observed more frequently in association with odontogenic tumors than with odontogenic cysts. Conversely, purulent discharge was associated more frequently with odontogenic cysts than with tumors. Chart 1 presents the frequency of impacted teeth associated with lesions, stratified by impacted tooth number.

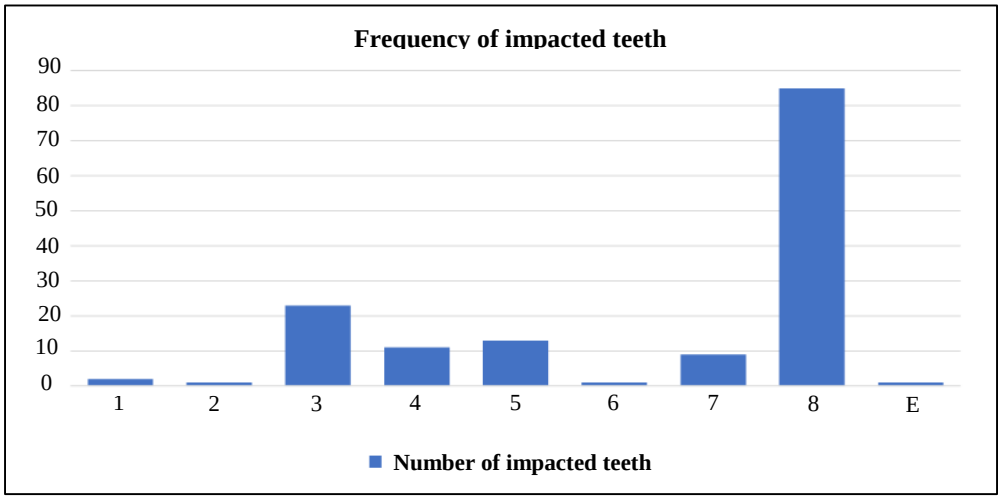

Chart 1. Frequency of impacted teeth associated with lesions according to tooth number

According to Chart 1, the most common impacted tooth associated with the examined lesions was the third molar, with a frequency of 85 cases (58.2%). 135 cases (31.5%) of the lesions (including 114 cases (84.4%) of odontogenic cysts and 21 cases (15.6%) of odontogenic tumors) were associated with impacted teeth. There was no statistically significant difference between the frequency of odontogenic cysts and tumors in terms of association with impacted teeth or lack of association with impacted teeth.

The most common lesions associated with impacted teeth were, in order: 91 dentigerous cysts (67.4%) associated with 98 impacted teeth, 20 odontogenic keratocysts (14.8%) associated with 21 impacted teeth, and 13 complex odontomas (9.6%) associated with 15 impacted teeth (10.4%). Based on the results, 100% (91 cases) of dentigerous cysts and 27.4% (20 cases) of odontogenic keratocysts were associated with impacted teeth. The most common tumors associated with impacted teeth were, in order: 65% (13 cases) complex odontoma with a frequency of 15 impacted teeth and 25% (4 cases) unicystic ameloblastoma with a frequency of 5 impacted teeth. The most common impacted teeth in complex odontoma were, in order: third molar (8 cases, 53.3%), second molar (3 cases, 20%), and central incisor (2 cases, 13.3%).

Radiographically, a radiolucent appearance was observed in 395 cases (92.3%) of the lesions, which corresponded to 359 odontogenic cysts and 36 odontogenic tumors. A mixed appearance was observed in 14 cases (3.3%) of the lesions, which corresponded to 4 odontogenic cysts and 10 odontogenic tumors. An opaque appearance was observed in 19 cases (4.4%) of the lesions, of which 18 cases were related to odontogenic tumors.

In the macroscopic examination of the lesions, the results showed that the mean largest diameter of the lesion on macroscopic view was 17.8±8.65 mm in cysts and 26.1±23.65 mm in tumors, and the largest lesion size in tumor samples was approximately greater than the lesion size in cyst samples (p=0.059). The majority of cysts and tumors (356 cases, 83.2%) had elastic consistency and cystic cross-sectional surface (380 cases, 88.8%). The most common color of the cross-sectional surface was cream-brown, with a frequency of 313 cases (73.1%).

Discussion

In the present study, 428 records (28.3% of all referred lesions) were diagnosed as odontogenic lesions. This rate was 17.9% in the study by Ribeiro et al. over a 7-year period (21), 16.9% in the study by Baghaei

et al. over a 13-year period (1), 10.3% in the study by Niranjan et al. over a 20-year period (12), and 9.9% in the study by Singh et al. over a 4-year period (13). In the present study, the frequency of odontogenic cysts was 85% and the prevalence of odontogenic tumors was 15% of all odontogenic lesions. The prevalence rate of odontogenic cysts was 90.3% in the study by Izgi et al. (22), 86.4% in the study by Baghaei et al. (1), 76.8% in the study by Singh et al. (15), 82.5% in the study by Niranjan et al. (12), and 58.1% in the study by Ribeiro et al. (21), which in some cases is similar to the present study and in some cases is somewhat different from the present results. Nevertheless, in the study by Singh et al., a prevalence of 37% was reported for odontogenic cysts, which is lower than the present study, representing results different from those of other studies (13).

In the present study, 54.4% of the lesions were related to male patients. This rate was 63% in the study by Niranjan et al. (12) and 63.7% in the study by Ribeiro et al. (21). However, in the study by Baghaei et al., 35.6% of the lesions were related to male patients, which is contrary to the result of the present study, in which the number of men was greater than that of women (1). In our study, the mean age of patients with cysts was 33.02±15.31 years, and the mean age of patients with tumors was 32.53±16.08 years. Niranjan et al. reported a mean age of 27.78±13.4 years for patients with odontogenic cysts and a mean age of 29.8±14.3 years for patients with odontogenic tumors (12). Additionally, in the study by Baghaei et al., the mean age of patients with odontogenic cysts was 27.88 years, and the mean age of patients with odontogenic tumors was 23.09 years, both of which were somewhat lower than the ages of patients in the present study (1).

In the results of our study, the third decade of life accounted for the highest number of patients with odontogenic cysts. These results were similar to the studies by Almazyad et al. (23), Vaez et al. (24), Sargolzaei et al. (5), Ansari et al. (7), and Baghaei et al. (1). However, in the study by Khosravi et al. (2) and Ribeiro et al. (21), the second decade of life, and in the study by Dezfuli et al. (25) and Izgi et al. (22), the fourth and fifth decades of life accounted for the highest number of patients with odontogenic cysts, which differed from the results of our study.

In the present study, odontogenic tumors had the highest number of patients in the third and fourth decades of life. This finding is consistent with the results of other reported studies, such as the study by Vaez et al. (24), Ribeiro et al. (21), and Baghaei et al. (1). However, in the study by Almazyad et al. (26) and the study by de Medeiros et al. (27), the second decade of life, and in the study by Izgi et al., the sixth decade of life accounted for the highest number of patients with odontogenic tumors (22). In this study, the most common cyst in the age group under 20 years was dentigerous cyst, and the most common cyst in the age group 21 years and older was radicular cyst. These results were similar to the study by Khosravi et al. (2). However, Buaoud et al. reported radicular cyst as the most common odontogenic cyst across all age groups (28).

In the study by Siadati et al., 15.2% of the lesions in patients under twenty years of age consisted of cystic lesions. Additionally, radicular cyst was the most common of these lesions, with a frequency of 37.9% (29). In the present study, the most common odontogenic tumor in the age group under 20 years was odontoma, and the most common odontogenic tumor in the age group 21 years and older was ameloblastoma, which was similar to the study by Ribeiro et al. (21). However, Singh et al. reported ameloblastoma and adenomatoid odontogenic tumor as the most common odontogenic tumors in the age group under 20 years and ameloblastoma as the most common odontogenic tumor in the age group 21 years and older (13).

In the present study, the most common odontogenic cysts were, in order, radicular cyst, dentigerous cyst, and odontogenic keratocyst. These results were similar to the results of the study by Izgi et al. (22), the study by Singh et al. (15), Ansari et al. (7), Khosravi et al. (2), Sargolzaei et al. (5), Dezfuli et al. (25), Almazyad et al. (23), and Buaoud et al. (28). However, Baghaei et al. reported that dentigerous cyst was the most common type of odontogenic cyst and radicular cyst was the second most common cyst in Hamadan, Iran (1). Additionally, in the study by Siadati et al., among the cysts, the most common cyst was radicular (30). Furthermore, in the study by Ribeiro et al. (21) and the study by Singh et al., odontogenic keratocyst was reported as the most common odontogenic cyst (13), which was contrary to the results of the present study.

In the present study, the most common odontogenic tumors were, in order, ameloblastoma with all its variants and complex odontoma. These results were similar to the results of the study by de Medeiros et al. (27), Ribeiro et al. (21), and Almazyad et al. (26), although Izgi et al. reported odontoma as the most common odontogenic tumor (22). Additionally, in other studies, the most common odontogenic tumor was ameloblastoma, but adenomatoid odontogenic tumor was reported as the second most common tumor (13, 15). In the present study, the most common location of odontogenic cysts and tumors was reported in the posterior mandible. These results were similar to the study by Khosravi et al. (2), the study by de Medeiros et al. (27), the study by Singh et al. (13), the study by Singh et al. (15), the study by Izgi et al. (22), the study by Ribeiro et al. (21), and Laksmitarani et al. (10). However, the study by Niranjan et al. (12) and the study by Buaoud et al. reported the anterior maxilla as the most common location of odontogenic cysts (28).

In this study, the most common location of radicular cyst was reported in the posterior mandible. This finding was similar only to the study by Izgi et al. (22). In other studies, the anterior maxilla was reported as the most common location of radicular cyst (2, 5, 7, 12, 15, 21, 24). However, it should be noted that the anterior maxilla was the second most common location of radicular cyst in the present study. In other studies, the most common location of ameloblastoma was reported in the posterior mandible, which was similar to the result of the present study (12, 13, 15, 21, 27).

In this study, 31.5% of the lesions were associated with impacted teeth, which included 84.4% of cases of odontogenic cysts and 15.6% of cases of odontogenic tumors. This rate was reported as 44.4% in the study by Vaez et al., of which 69.1% was related to cysts and 30.9% to odontogenic tumors (24). In the present study, the most common lesions associated with impacted teeth were, in order, dentigerous cyst and odontogenic keratocyst, which was similar to the studies by Vaez et al. (24), Khalesi et al. (31), Stathopoulos et al. (20), and Shoaee et al. (18). In the study by Mohammed et al. and the study by Seyedmajidi et al. regarding the frequency of odontogenic cysts and tumors associated with impacted teeth in Iran (Babol), dentigerous cyst was also the most common lesion associated with impacted teeth (19, 32); however, ameloblastoma was reported as the second most common lesion associated with impacted teeth (19). In the present study, complex odontoma was the most common odontogenic tumor associated with impacted teeth. These results were similar only to the study by Khalesi et al. (31). In other studies, ameloblastoma was reported as the most common odontogenic tumor associated with impacted teeth (17, 19, 20, 24). Given the high prevalence of lesions associated with impacted teeth (approximately one-third of cases), follow-up of the cause of non-eruption of teeth after the expected eruption time in the oral cavity is very important. Furthermore, due to the possibility of association with various odontogenic lesions that have different clinical behaviors, sometimes with aggressive characteristics and high recurrence, definitive diagnosis of the lesion and its histopathological examination are essential for appropriate treatment.

The present study provides valuable information regarding the frequency of odontogenic cysts and tumors at Babol Dental School as a referral center for maxillofacial lesions in Babol. However, considering that most odontogenic lesions grow slowly and, if not diagnosed in a timely manner and treated appropriately, tend to expand within the jaw, and also considering the possibility of malignancy in these lesions and their associated complications, follow-up and treatment are essential. The reasons for the overall difference between this study and other studies include the years examined, the number of cases reviewed, and the study center (a referral center for head and neck lesions). Given the high frequency of odontogenic lesions and their association with impacted teeth, future research could include a more comprehensive evaluation encompassing treatment, patient follow-up, and malignancy in these lesions.

According to the results of the present study, the frequency of odontogenic lesions was reported to be higher than in other studies, and a considerable association of lesions with impacted teeth was observed. Therefore, the presence of an impacted tooth can be considered a potential risk factor for the presence of odontogenic lesions.

Acknowledgment

We hereby express our gratitude to the Vice-Chancellor for Research and Technology of Babol University of Medical Sciences for supporting this study.

References

1.Baghaei F, Zargaran M, Najmi H, Moghimbeigi A. A clinicopathological study of odontogenic cysts and tumors in hamadan, iran. J Dent (Shiraz). 2014;15(4):167-72.

2.Khosravi N, Razavi SM, Kowkabi M, Navabi AA. Demographic distribution of odontogenic cysts in Isfahan (Iran) over a 23-year period (1988-2010). Dent Res J (Isfahan). 2013;10(2):162-7.

3.Zolfaghari R, Bijani F, Seyedmajidi S, Seyedmajidi M. Lymphangiogenesis in Odontogenic Keratocysts Compared with Dentigerous Cysts. J Dent (Shiraz). 2024;25(2):118-24.

4.Seyedmajidi M, Nafarzadeh S, Siadati S, Shafaee S, Bijani A, Keshmiri N. p53 and PCNA Expression in Keratocystic Odontogenic Tumors Compared with Selected Odontogenic Cysts. Int J Mol Cell Med. 2013;2(4):185-93.

5.Sargolzaei S, Hassanzadeh M, Eshghyar N, Taghavi N, Akbarzadeh A. Odontogenic Cysts: A 10-Year Retrospective Study in an Iranian Population. J Dent Sch. 2016;34(3):147-56.

6.Seyedmajidi M, Shafaee S, Shafigh E, Bijani A, Hamidi H. p63 expression in randomized odontogenic cysts. Saudi Med J. 2011;32(5):463-6.

7.Ansari MK, Alam S, Meraj F, Ahmed SS, Munir SA. Clinicopathological analysis of 847 odontogenic cysts in North Indian population examined over 10 years' period: A retrospective study. Indian J Oral Health Res. 2020;6(2):50.

8.Seyedmajidi M, Shafaee S, Siadati S, Moghaddam EA, Ghasemi N, Bijani A, et al. Immunohistochemical analysis of COX-2 expression in dentigerous cyst, keratocystic odontogenic tumor and ameloblastoma: A comparative study. Dent Res J (Isfahan). 2015;12(3):278-84.

9.Borrás-Ferreres J, Sánchez-Torres A, Gay-Escoda C. Malignant changes developing from odontogenic cysts: A systematic review. J Clin Exp Dent. 2016;8(5):e622-8.

10.Laksmitarani N, Yusuf HY, Adiantoro S. Prevalence of odontogenic cysts in oral and maxillofacial surgery department of hasan sadikin general hospital: 2 years retrospective study. Odonto Dent J. 2022;9(2): 290-8.

11.Neville BW, Damm DD, Allen CM, Chi AC. Oral and Maxillofacial Pathology, 5th ed. Elsevier; 2023. p.126-7, 685-746.

12.Niranjan KC, Shaikh Z. Clinicopathological correlation of odontogenic cysts and tumours in a South Indian population over a 20-year period. Int J Dent Res. 2014;2(2):32-6.

13.Singh J, Singh S, Chandra S, Samadi FM. Prevalence and Distribution of Odontogenic Cysts and Tumors in North Indian Population: A Database Study with Systematic Review Int J Appl Biol Pharm Technol. 2020;11(2):46-59.

14.Marin C, Dave M, Hunter KD. Malignant Odontogenic Tumours: A Systematic Review of Cases Reported in Literature. Front Oral Health. 2021;2:775707.

15.Singh CK, Chandra A, Kumar P, Rakhee, Singh AK, Kumar A. To determine the prevalence of odontogenic cysts and tumors in a rural area. J Adv Med Dent Scie Res 2020;8(10):210-3. Available from: https://jamdsr.com/uploadfiles/48odontogeniccystsandtumorsvol8issue10p210-213.20201102042902.pdf

16.Pakravan A, Nabizadeh MM, Nafarzadeh S, Jafari S, Bamdadian T. Evaluation of impact teeth prevalence and related pathologic lesions in patients in Northern part of Iran (2014-2016). J Contemp Med Sci. 2018;4(1):30-2.

17.Sarica I, Derindag G, Kurtuldu E, Naralan ME, Caglayan F. A retrospective study: Do all impacted teeth cause pathology?. Niger J Clin Pract. 2019;22(4):527-33.

18.Shoaee S, Khazaei P, Mashhadiabbas F, Varshosaz M, Sharifi F, HessarI H. Association between tooth impaction and odontogenic lesions: A matched case-control study. Med J Islam Repub Iran. 2018;32:57.

19.Mohammed M, Mahomed F, Ngwenya S. A survey of pathology specimens associated with impacted teeth over a 21-year period. Med Oral Patol Oral Cir Bucal. 2019;24(5):e571-6.

20.Stathopoulos P, Mezitis M, Kappatos C, Titsinides S, Stylogianni E. Cysts and tumors associated with impacted third molars: is prophylactic removal justified?. J Oral Maxillofac Surg. 2011;69(2):405-8.
21.Ribeiro LN, dos Anjos RS, de Barros AV, Rocha JC, de Aquino AA, e Silva ED, et al. Evaluation of cysts and odontogenic tumors over a period of 8 years in a reference medical hospital in Brazil. Res Soc Dev. 2021;10(12):e169101220140.
22.Izgi E, Mollaoglu N, Simsek MB. Prevalence of odontogenic cysts and tumors on turkish sample according to latest classification of world health organization: A 10-year retrospective study. Niger J Clin Pract. 2021;24(3):355-61.
23.Almazyad A, Almutairi M, Almadan N, Alamro M, Maki F, AlQuwayz TS, et al. Frequency and Demographic Profile of Odontogenic Cysts in Riyadh, Saudi Arabia: Retrospective Multicenter Study. Diagnostics (Basel). 2023;13(3):355.
24.Vaez R, Moradzadeh Khiavi M, Abdal Kh, Borhani H. Odontogenic lesions associated with impacted teeth: A 5-year retrospective institutional study. J Craniomax Res. 2023;10(3):99-106.
25.Dezfuli MK, Zamanzade M, Rezaei SF, Karimpour M, Moaddabi A. Prevalence of Odontogenic and Non-Odontogenic Cysts at Sari Bu Ali Sina Hospital: A 10-Year Retrospective Analysis. J Mazandaran Univ Med Sci. 2023;33(221):117-25. [In Persian]
26.Almazyad A, Alamro M, Almadan N, Almutairi M, AlQuwayz TS. Frequency and Demographic Analysis of Odontogenic Tumors in Three Tertiary Institutions: An 11-Year Retrospective Study. Diagnostics (Basel). 2024;14(9):910.
27.de Medeiros WK, da Silva LP, Santos PP, Pinto LP, de Souza LB. Clinicopathological analysis of odontogenic tumors over 22 years period: Experience of a single center in northeastern Brazil. Med Oral Patol Oral Cir Bucal. 2018;23(6):e664-71.
28.Buaoud MM, Musrati A, Hagstrom J. Prevalence of odontogenic cysts in a group of Libyan population: A retrospective study. Niger J Clin Pract. 2023;26(8):1152-6.
29.Siadati S, Seyedmajidi M, Sharbatdaran M. Frequency of different oral lesions in children and adolescents in Babol, Northern Iran. Caspian J Intern Med. 2013;4(4):773-6.
30.Siadati S, Seyedmajidi M, Naderi K. The Prevalence of Odontogenic Cysts and Tumors in Babol, North of Iran. J Babol Univ Med Sci. 2015;17(3):83-8. [In Persian]
31.Khalesi S, Kargahi N, Shekarian S. Frequency of jaw pathologic lesions related to impacted teeth in Isfahan Dental School, Iran. J Oral Health Oral Epidemiol. 2021;10(4):218-24.
32.Seyedmajidi M, Nafarzadeh Sh. Frequency of odontogenic cysts and tumors associated with the impacted teeth in Babol dental faculty (2003-2010). J Inflamm Dis. 2013:17(1):95-8. [In Persian]