



## The Effect of Ultraviolet Light Exposure on the Titanium Screw Implants Osseointegration in Different Time Intervals

M. Shakir Mahmood (DDS, MS)<sup>\*1</sup> , Y. Mohammed Haider (DDS, MS)<sup>1</sup> ,  
H. K. Alalwan (DDS, MS)<sup>1</sup> , A. Fatalla (DDS, MS)<sup>1</sup> , N. Mokhtar (DDS, MS)<sup>2</sup> 

1. Department of Prosthodontics, College of Dentistry, University of Baghdad, Baghdad, Iraq.

2. Department of Dental Science, Advanced Medical and Dental Institute, Universiti Sains Malaysia, Penang, Malaysia.

\*Corresponding Author: M. Shakir Mahmood (DDS, MS)

Address: Department of Prosthodontics, College of Dentistry, University of Baghdad, Baghdad, Iraq.

Tel: +964 (771) 2354521. E-mail: mustafa.shakir@codental.uobaghdad.edu.iq

### Article Type

### ABSTRACT

#### Research Paper

**Background and Objective:** The effect of ultraviolet light on the osseointegration of titanium screw implants is scarcely discussed in literature. The present research was performed to study the effect of Ultraviolet (UV) light exposure on the osseointegration of titanium dental implants in different time intervals.

**Methods:** In this in vivo experimental-qualitative study including UV exposure and mechanical and histological tests, 48 implant screws were implanted in the tibia of 48 rabbits for histological and torque removal tests. The rabbits were divided into two groups (mechanical n=36 and histological n=12). A bone-cutting process was performed 5 mm from an implant screw. Block was preserved in 10% formalin, decalcified in 8% formic acid, and the screw was carefully removed. Bone dehydration was performed using alcohol, heated for 30 minutes, and infiltrated with xylene and paraffin wax before embedding. Each of the mechanical and histological tests contained three groups (Control, UV 30, and UV 60) for each healing period, 2 and 6 weeks.

**Findings:** The mean value for torque removal test for screws in the UV60 group in 2 weeks significantly increased compared to the control group ( $7.48 \pm 1.64$  vs.  $2.41 \pm 0.70$ ). The mean value of new bone formation percentage (NBFP) for the UV60 implanted rabbits was 5.76%, compared to the control group 3.65% in the second time interval (6 weeks after implantation). Histological examination showed that bone formation, mineralization, and maturation have been increased with the rabbits exposed to UV light for 30 ( $4.71 \pm 0.85$ ) and 60 minutes ( $5.76 \pm 0.85$ ) compared with the control group ( $3.65 \pm 0.55$ ).

**Conclusion:** The results of this study showed that UV light exposure can effectively reduce the period of rabbit implants osseointegration.

**Keywords:** *Osseointegration, Histological Examination, Bone Formation, Histomorphometric, Ultraviolet Light Exposure.*

Received:

Jul 2<sup>nd</sup> 2024

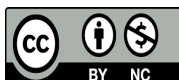
Revised:

Sep 23<sup>rd</sup> 2024

Accepted:

Oct 12<sup>nd</sup> 2024

**Cite this article:** Shakir Mahmood M, Mohammed Haider Y, Alalwan HK, Fatalla A, Mokhtar N. The Effect of Ultraviolet Light Exposure on the Titanium Screw Implants Osseointegration in Different Time Intervals. *Journal of Babol University of Medical Sciences*. 2025; 27: e9.



## Introduction

Bone metabolism involves a dynamic process of forming and resorbing bone tissue. Interestingly, this complicated swing is influenced by exposure to ultraviolet (UV) light. Low dose of UV light potentially plays a dual role: it could stimulate bone formation while simultaneously reducing bone resorption. It achieves this remarkably without adverse effects to the skin (1).

UV light belongs to the electromagnetic radiation spectrum. Its wavelength is shorter than visible light, but appears long when compared to X-rays. UV light is classified into distinct categories based on wavelength, Vacuum UV (100-200 nm), UVC (200-280 nm), UVB (280-315 nm), and UVA (315-400 nm) (2).

UV Light shows a biological impact and each UV category has unique effects on biological tissues. UVC (a microcidal composition that can be harnessed for sterilization), UVB (a healing assistant that promotes wound healing and activates the immune system), UVA (a director of cell signalling pathways; it modulates crucial cellular responses) (3).

Using UV Light in modification of dental implants increases the direct contact between living bone and implant surface, which is vital for long-term implant success. Via irradiating implant surfaces, osseointegration was improved, where factors like surface roughness, hydrophilicity, and composition all play a role in this complicated relationship between tissue and implant (4).

Dental implant material plays a vital role in the success of osseointegration. Titanium (particularly Ti-6Al-4V) reigns supreme. Its biocompatibility owes much to the stable oxide layer that forms on the titanium surface, providing corrosion resistance (5, 6).

When it comes to the stability of dental implants, we encounter a fascinating interplay of materials. Screws, abutments, and attachments, all these components contribute to the intricate structure. However, the use of dissimilar metals in this combination can potentially lead to galvanic action, resulting in corrosion and discomfort. Oxide layer's condition played a critical role in determining implant success. Specifically, the chemical purity and surface cleanliness of this oxide layer are pivotal for successful osseointegration. Any contamination during production or sterilization can adversely affect cellular responses and overall morphology (7, 8).

Metrics of stability and osseointegration that have been used in literature are primary and secondary stability measurements. The primary refers to the mechanical fixation of implants within cortical bone. It is like ensuring a solid anchor for the implant. However, the secondary measurement observes the formation of new bone around the implants. It is a sign that the bone is embracing the implant, creating a stable environment (9).

Stability transition of dental implants is a crucial point where primary stability transitions to secondary stability. This occurs approximately 4 weeks after implant placement. Studies hypothesize that UV light irradiation of implants can significantly impact the rate and quality of osseointegration (10, 11). Impact of exposure to UV light on osseointegration was rarely investigated in literature.

Accordingly, the researcher found it necessary to further study the effect of UV light effect on the osseointegration of dental implant. Generally, it is necessary to wait for several months after implant placement to allow for adequate osseointegration. With the exposure of UV light, the titanium dental implant is supposed to attain earlier osseointegration, decrease the possibility of dental implant failure, increase the bone to implant contact, and shorten the osseointegration time period compared with the general duration of time for the osseointegration to be achieved (12). This process is supposed to avoid implant mobility or pain and other time-consuming situations, such as an edentulous area with limited bone quantity, or problems in patients with osteoporosis, diabetes, cancer, irradiation, old age, and heavy smokers (13).

## Methods

**Screw Preparation:** A lathe machine was used to produce 48 screw-shaped implants from a CpTi bar. The screws were 8 mm long (3 mm flat shank and 5 mm threaded) and 3 mm in diameter. The height and width of the drive slot was 1 mm to allow the use of a screwdriver for insertion and removal (14).

**UV Light Sample Treatment:** This qualitative in vivo experimental study includes UV light exposure, mechanical and histological tests. This experimental study was conducted under the approval of ethics committee of the University of Bagdad, College of Dentistry (Code 791223). Implant sample grouping of this study was divided as follows: 48 implants and healthy rabbits were used (one implant per rabbit); the rabbits were divided into two groups (mechanical test groups [n=36] and histological test groups [n=12]). The UV groups were exposed to UV supplemented under a white light LED (320 nm):

Mechanical test (torque removal test): 36 implant screws were divided into:

**-Control group:** 12 implant screws were implanted (6 implants were used for each healing period, 2 and 6 weeks).

**-Experimental group 1:** The rabbits were exposed to UV light (ultraviolet A 320) for 30 minutes per day, 12 implant screws (6 implant screws for each healing period, 2 and 6 weeks).

**-Experimental group 2:** The rabbits were exposed to UV light (ultraviolet A 320) for 60 minutes per day, 12 implant screws (6 implant screws for each healing period, 2 and 6 weeks).

12 implant screw samples were used for the histological testing:

**-Control group:** implant screws were implanted (2 implant screws for each healing period, 2 and 6 weeks).

**-Experimental group 1:** The rabbits were exposed to UV light (ultraviolet A 320) for 30 minutes per day, 4 implant screws (in each healing period, 2 and 6 weeks, 2 implant screws were used).

**-Experimental group 2:** The rabbits were exposed to UV light (ultraviolet A 320) for 60 minutes per day, 4 implant screws (in each healing period, 2 and 6 weeks, 2 implant screws were used).

The determination of sample size was based on the ethical considerations and adhered to the specific requirements of the experiment, ensuring an adequate and appropriate sample size for the study.

**Removal Torque Analysis:** Measurement of removal torque value (RTV) was performed in Newton centimetres (Ncm) to assess the interfacial shear strength between the implant and bone tissue. Rabbits were anaesthetised under sterile conditions.

**1. Mechanical Test (Torque removal test):** After 2- and 6-week healing intervals, torque measurement was conducted via a digital torque meter (TQ-8800, Taiwan). Before that, the bone had been secured so as not to move during the test and to keep the test accurate. The screwdriver of the torque meter was engaged in the drive slot and a torsional force was applied to unscrew the implant and record the maximum value.

**2. Histological Test:** The histological test was performed in the Lab of Histology, Oral Diagnosis Department, College of Dentistry, in the University of Bagdad. On the day of animal scarification, A cutting process was performed on the bone around the implant (5 mm away from the screw) using a disc cutter (with a slow rotation and continuous saline water irrigation) via a prosthetic engine (Marathon motor, Korea) provided by a straight handpiece. To obtain the block of bone implant, a 0.5 cm incision was performed near the implant screw. The blocks were initially preserved in 10% formalin and then decalcified in 8% formic acid with daily changes. The implant screw was carefully removed from the bone bed and the bone was sectioned. The specimen was gradually dehydrated by immersing it in a series of alcohol solutions with an increasing concentration. After three hours, the samples were heated at 60°C for 30 minutes in an oven. The tissue was infiltrated with xylene and paraffin wax and embedded in the centre of the paraffin blocks. The slide was stained with haematoxylin and eosin for 10 minutes and then observed under a light microscope at 4X and 20X magnifications.

**3. Histomorphometric Analysis:** Histomorphometric analysis (new bone formation percentage measurement) was performed after six weeks of the implanting process via Fiji ImageJ program, version 1.50 b. Measurement of the section diameter was first performed, and the mean value and the diameter of the screw were then entered in a set scale box. Values were collected from the program, which represents the area measured.

The new bone formation percentage (NBFP) was calculated according to the following formula according to Ott and Baek et al. (15, 16).

$$\text{NBFP \%} = \frac{\text{Area of newly formed bone}}{\text{Total tissue area}} \times 100$$

The mean, SD and SE for the NBFP were calculated and the data were analyzed statistically by unpaired t-test.

Statistical analysis of the current study was conducted using SPSS version 21. One way ANOVA test was used followed by Tukey post hoc test.  $P < 0.05$  is considered statistically significant.

## Results

**Mechanical Test Results:** After the first interval (2 weeks), rabbits treated with UV60 min light needed the highest torque value for the implant removal (mean value 7.483 N.cm) in comparison to UV30 light group (mean value 4.500 N.cm) and the control group (mean value 2.417 N.cm). For the second interval (6 weeks), same superiority for the UV60 min treated group in torque removal values were observed in comparison to the other tested groups as shown in table 1.

**Table 1. Description statistics of torque removal values for all tested groups (N.cm)**

Types and Time	N	Mean±SD	Comparison
Control			
2 Weeks	6	2.417±0.703	a
6 Weeks	6	9.700±1.475	
UV 30 min			
2 Weeks	6	4.500±1.293	b
6 Weeks	6	13.717±1.229	
UV 60 min			
2 Weeks	6	7.483±1.643	c
6 Weeks	6	15.217±1.262	

One way ANOVA table showed presence of statistical differences between the tested groups. Both treated groups (30 and 60 min) showed a significant difference with control group at both healing intervals (2 and 6 weeks) as shown in (Table 2).

Least Significant Difference (LSD) was used in the multiple comparisons of subgroups and within groups. When the comparison was made between the control group and the other groups, a highly significant difference was found at  $p < 0.01$  for both time intervals (2 and 6 weeks). On the other hand, when the UV30 experimental group was compared with the UV60 group, a significant difference was found at  $p < 0.05$  for both time intervals (two and six weeks) of the healing periods. (Table 2).

**Table 2. ANOVA statistics and LSD Multiple Comparisons test of torque removal values for all tested groups**

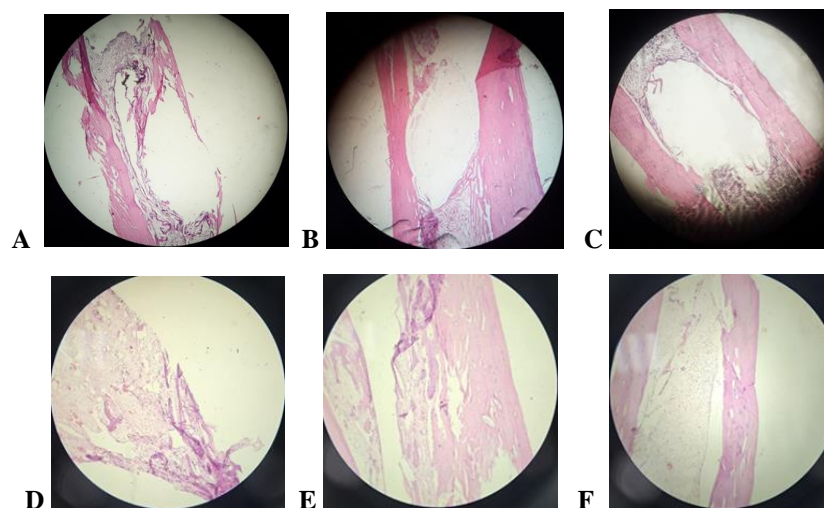
Period of healing	Test group and UV test	MD	Sig.	ANOVA statistics		
				F	df	Sig.
2 Weeks	<b>Control</b>					
	UV 30 min	-2.083	0.013			
	UV 60 min	-5.067	0.000			
	<b>UV 30 min</b>					
	UV 60 min	-2.983	0.001	1.582	1	0.001
	<b>Control</b>					
6 Weeks	UV 30 min	-4.017	0.000	1.407	1	0.0001
	UV 60 min	-5.517	0.000	1.171	1	0.0001
	<b>UV 30 min</b>					
	UV 60 min	-1.500	0.069			

**Histological Features after 2 Weeks of Implantation:**

**-Control Group Specimens:** The histological feature of specimens of the control group implants in Figure 1 (A) and (D) shows osteoid tissue with numerous osteoblasts, with new bone formation (hematopoietic tissues) highlighting the formation of active osteoid tissue (AOT).

**-UV 30 min Specimens of the Experimental Group Implants:** The specimens of the UV 30 min experimental group implants showed similar histological features as in control group with more evident features. Figure 1 (B) and (E) shows new bone trabeculae lined by a rim of osteoblast on the bone surface (active osteoid tissue) and the presence of new bone trabeculae (BT). These trabeculae are surrounded by osteoblast cells (OBC), and there is evident formation of AOT.

**-UV 60 min Implants Specimens:** The histological feature of specimens in UV 60 min group are shown in figure 1 (C) and (F), where bone trabeculae with osteoblast are arranged on the periphery and osteoclast occupying their large lacunae, revealing the presence of new BT. These trabeculae are accompanied by osteoblast cells (OBC).



**Figure 1. Microscopic images display a cross-sectional view of rabbit's tibia specimens after two weeks of implantation. A&D of the control group. B&E of UV 30 min. C&F of UV 60 min. The upper panels were magnified at 4KX and the lower panel were magnified at 10KX.**

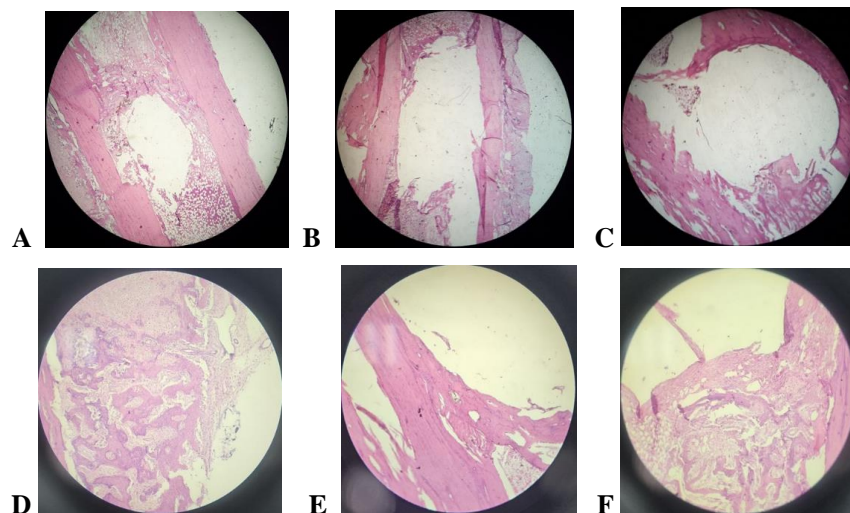


### Histological Feature After 6 Weeks of Implantation:

**-Control Group Specimens:** The histological feature of control group specimens in Figure 2 (A) and (D) shows bone formation, indicated by osteoid tissue and mature bone with osteocytes. Higher magnification photomicrograph shows osteocytes within trabeculae bone, revealing the presence of new BT. These trabeculae are accompanied by osteoblast cells (OBC).

**-UV 30 min Implants Specimens:** The experimental group specimens also showed the same histological features. Figures 2 (B) and (E) showed mature bone with osteocytes scattered within it and a reversal line separated between the old and new bone.

**-UV 60 min Experimental Group Specimens:** Figure 2 (C) and (F) showed thick bone trabeculae with fibroreticular tissue scattered between them and a large number and size of osteocytes embedded within trabeculae, raw of osteoblasts and other osteoclast arranged in the periphery of trabeculae indicating the presence of new BT.



**Figure 2.** Microscopic images display a cross-sectional view of rabbit's tibia specimens after six weeks of implantation. A&D of the control group. B&E of UV 30 min. C&F of UV 60 min. The upper panel were magnified at 4KX and the lower panel were magnified at 10KX.

**Histomorphometry Analysis:** After 6 weeks of implantation, there was a greater percentage of bone formation in implants exposed to 60 min of UV light compared to the control group, as seen in Tables (3 and 4). The increased bone formation over this period could be due to the early activation of UV light, influencing the tissue at the implant bone interface. This activation process appears to persist throughout the 6 weeks of implantation.

**Table 3. Descriptive analysis of new bone formation (NBFP) for control, UV30 and UV 60 groups after six weeks**

Types	Mean±SD
CONTROL	3.65±0.55 <sup>a</sup>
UV 30 MIN	4.71±0.85 <sup>b</sup>
UV 60 MIN	5.76±0.93 <sup>c</sup>

**Table 4. Difference in the mean values of new bone formation (NBFP) for control, UV 30 and UV 60 groups after six weeks. Multiple one-way ANOVA with Multiple Comparisons**

Groups	Mean Difference	Sig.
Control	UV30	-1.05*
	UV60	-2.11*
UV30	UV60	-1.05*

## Discussion

In the present study, the torque removal values were higher for the UV light-treated implant groups compared to the control group. This is possible because the newly formed bone around the implanted screw in the UV light-treated groups was higher in range. The newly formed bone in the first healing interval (2 weeks) has been developed to mature bone at the second healing interval (6 weeks), and bond strength between the implant and bone has increased. The effect of UV light treatment on bond strength between the bone and the implant was obvious, which resulted in higher values of torque removal. This could be attributed to the increased bone density due to exposure to UV light, which agrees with other studies (1, 17).

Several methods have been applied to stimulate osseointegration to achieve excellent implant bone bonds for obtaining long-term stable implants (18). Previous research investigations have demonstrated a direct correlation between the resistance to removal torque of implants and the extent of osseointegration, which refers to the level of bone contact with the implant (19).

In this research, removal torque was employed to assess both the existence and extent of osseointegration, serving as a method to evaluate the mechanical characteristics of bone-implant interface, with a primary focus on probing the mechanics of this interface through torsional forces. This methodology has been extensively applied in various experimental investigations. When it comes to the examination and comparison of screw-shaped implants, the removal torque emerges as a valuable parameter (11).

The screw implants that had been placed in the femur bone of rabbits recorded a higher mean value of torque removal in the UV60 group than control screw implants 2 weeks after the implantation process. This means UV60 enhanced bone formation, and bond strength was increased at bone-to-implant contact. Different mean torque values have been observed in previous studies. These differences could be due to the different screw designs, primary stability (uni-cortical or bi-cortical), implantation sites (tibia or femur), or different torque meter devices used. The torque meter device used in this study is the digital torque meter TQ-8800 (20-23).

**Histological Findings:** Osteointegration happens when the implantation process is performed on a living bone with an appropriate biological environment for the growth of new bone tissues. This has been approved by histological analysis, which showed bone maturation and deposition in all groups. The current study found that new bone trabeculae formed around the implant screws in both (UV30, UV60) and control groups, with activation of osteoblasts and osteocytes.

In this study, it was found that after two weeks screw insertion, the formation of new bone trabeculae was very noticeable in the area around the screw implants in all UV light experimental groups. This confirms that bone formation process had started. The experimental groups showed more evidence of new bone deposition, with osteoblasts surrounding many osteocytes and blood vessels at the interface region. This indicates that bone formation was more active in the experimental groups than in the control group.

The control group showed a few thin bone trabeculae in the area around the implant. On the other hand, the experimental groups showed thick and numerous new bone trabeculae lined by active osteoblasts with numerous osteocytes. These findings are consistent with the findings of other studies, which found that the insertion of an implant in rabbit cortical bone led to rapid and organized bone growth, although it was not detected specifically on the implant surface (24, 25).

**Histomorphometry Analysis:** Histomorphometry analysis is a method used for both evaluation and quantification of osseointegration parameters around the surface of implant. The bone-implant contact (BIC) is a measure of osseointegration degree that is derived from primary stability. It is calculated by percentage measurement for bone contacted with a perimeter of the implant surface (26).

The percentage of newly formed bone after 6 weeks of screw implant placement is higher in the UV60 group of implanted rabbits than in the control group of implanted rabbits that may be attributed to the exposure of UV light at an early stage, which continued to activate bone formation throughout 6 weeks of implantation.

The results of the current research exhibited that exposure to UV light augment the rate and degree of osseointegration in the rabbit model. This agrees with other studies that showed the positive impact of exposure to UV light on bone metabolism in rats, where an increase in bone mass and mineral density with no negative effects on the skin with potential positive effect on 1, 25-dihydroxy-vitamin D3 (1, 24, 27). The increase in stability is an indication of improved osseointegration at the bone-implant interface. Analysis of removal torque and histomorphometry parameters of BIC indicated higher values at each time interval for UV-treated models (20, 28).

Accordingly, the results of the current study showed that there is increase in torque removal value, and the indications of histological and histomorphometry tests confirm that the bone formation was more active in the UV light experimental groups than in the control group.

The study concluded that exposure of rabbit model to UV 60-minute and UV 30-minute light were effective in low doses in reducing the time for osseointegration of titanium implants.

**Conflicts of Interest:** The authors declare that there are no conflicts of interest regarding this manuscript..

## Acknowledgment

This research was supported by the internal funds of the College of Dentistry, University of Baghdad. The authors wish to acknowledge Zubaida T. Najim for her help in data entry.



## References

1. Guo R, Du Y, Zhang S, Liu H, Fu Y. The effects of ultraviolet supplementation to the artificial lighting on rats' bone metabolism, bone mineral density, and skin. *J Photochem Photobiol B*. 2018;188:12-8.
2. Vázquez M, Hanslmeier A. *Ultraviolet Radiation in the Solar System*. Dordrecht, the Netherlands: Springer; 2006. p. 47-54.
3. Sanchez-Perez A, Cachazo-Jiménez C, Sánchez-Matás C, Martín-de-Llano JJ, Davis S, Carda-Batalla C. Effects of Ultraviolet Photoactivation on Osseointegration of Commercial Pure Titanium Dental Implant After 8 Weeks in a Rabbit Model. *J Oral Implantol*. 2020;46(2):101-7.
4. Paul V, Mathew TA, Rasheed N, Thomas AS, George N. Photofunctionalization of Dental Implant Surfaces - A Histomorphometric Animal Study. *J Pharm Bioallied Sci*. 2023;15(Suppl 1):S646-S50.
5. Le Guéhennec L, Soueidan A, Layrolle P, Amouriq Y. Surface treatments of titanium dental implants for rapid osseointegration. *Dent Mater*. 2007;23(7):844-54.
6. Sykaras N, Iacopino AM, Marker VA, Triplett RG, Woody RD. Implant materials, designs, and surface topographies: their effect on osseointegration. A literature review. *Int J Oral Maxillofac Implants*. 2000;15(5):675-90.
7. Jun SH, Park CJ, Hwang SH, Lee YK, Zhou C, Jang HS, et al. The influence of bone graft procedures on primary stability and bone change of implants placed in fresh extraction sockets. *Maxillofac Plast Reconstr Surg*. 2018;40(1):8.
8. Javed F, Ahmed HB, Crespi R, Romanos GE. Role of primary stability for successful osseointegration of dental implants: Factors of influence and evaluation. *Interv Med Appl Sci*. 2013;5(4):162-7.
9. Abdullah ZS, Mahmood MS, Abdul-Ameer FMA, Fatalla AA. Effect of commercially pure titanium implant coated with calcium carbonate and nanohydroxyapatite mixture on osseointegration. *J Med Life*. 2023;16(1):52-61.
10. Choi YJ, Jun SH, Song YD, Chang MW, Kwon JJ. CT Scanning and Dental Implant. In: Subburaj K, editor. *CT Scanning - Techniques and Applications*. InTech; 2011. p. 231.
11. Lang X, Qiao B, Ge Z, Yan J, Zhang Y. Clinical Effects of Photofunctionalization on Implant Stability and Marginal Bone Loss: Systematic Review and Meta-Analysis. *J Clin Med*. 2022;11(23):7042.
12. Jun JH, Oh KC, Park KH, Jung N, Li J, Moon HS. Improvement of Osseointegration by Ultraviolet and/or Simvastatin Treatment on Titanium Implants with or without Bone Graft Materials. *Materials (Basel)*. 2021;14(13):3707.
13. Ghambaryan N. Impact of Dental Implant Surface UV-Photofunctionalization on Osseointegration and Antibacterial Properties: Systematic Review. *Bull Stomatol Maxillofac Surg*. 2024;20(2):152-60.
14. Aita H, Hori N, Takeuchi M, Suzuki T, Yamada M, Anpo M, et al. The effect of ultraviolet functionalization of titanium on integration with bone. *Biomaterials*. 2009;30(6):1015-25.
15. Ott SM. Histomorphometric measurements of bone turnover, mineralization, and volume. *Clin J Am Soc Nephrol*. 2008;3(Suppl 3):S151-6.
16. Baek SM, Kim SG, Lim SC. Histomorphometric Evaluation of New Bone Formation around a Magnetic Implant in Dogs. *Implantology*. 2011;15(1):22-30.
17. Ochiai S, Nishida Y, Higuchi Y, Morita D, Makida K, Seki T, et al. Short-range UV-LED irradiation in postmenopausal osteoporosis using ovariectomized mice. *Sci Rep*. 2021;11(1):7875.
18. Issmaeel SA, Abbas AH. The effect of low-level laser on osseointegration of dental implants. *J Bagh College Dentistry*. 2011;23(3):112-6.
19. Huang Y, Zhang H, Chen Z, Wang Y, Yang X, Yu H. Improvement in Osseointegration of Titanium Dental Implants After Exposure to Ultraviolet-C Light for Varied Durations: An Experimental Study in Beagle Dogs. *J Oral Maxillofac Surg*. 2022;80(8):1389-97.

20. Alnajar SSA, Mohammed SA. Mechanical and histological significance of Nigella Sativa Oil extract on bone-implant interface. *J Bagh Coll Dent*. 2009;21(4):39-43.
21. Rabinowitz J, Lin JJ, Greenhouse A, Rao MV, Provencher M, Parada S, et al. The Effect of Screw Design and Cortical Augmentation on Insertional Torque and Compression in Coracoid-Glenoid Fixation in a Sawbones Model. *Arthroscopy*. 2020;36(3):689-95.
22. Gandhi Y, Padhye N. Comparison of insertion torque, implant stability quotient and removal torque, in two different implant designs with and without osseodensification. - An ex vivo bench top study. *J Oral Biol Craniofac Res*. 2023;13(2):249-52.
23. Wu W, Wang SR, Zhang W. [Effect of ultraviolet irradiation through glass on the level of 25-hydroxy vitamin D and bone metabolism in rats]. *Zhongguo Dang Dai Er Ke Za Zhi*. 2009;11(2):138-41. [Chinese].
24. Cochran DL, Jones AA, Sugita R, Brown MC, Prasad H, Kay GW. Twelve-month evaluation of a novel mineral-organic adhesive material used to stabilize dental implants placed in oversized osteotomies in vivo in an animal model. *Clin Oral Implants Res*. 2022;33(4):391-404.
25. Musadaq YM, Khalaf BS, Ghani BA. In Vivo Mechanical and Histological Evaluation of the Effect of Vacuum Storage and Ultra Violet Light Treatment of Titanium Implants on Osseointegration. *Int J Sci Res*. 2018;7(3):266-72.
26. Habibovic P, Li J, Van Der Valk CM, Meijer G, Layrolle P, Van Blitterswijk CA, et al. Biological performance of uncoated and octacalcium phosphate-coated Ti6Al4V. *Biomaterials*. 2005;26(1):23-36.
27. Zhuo ZZ, Liu L, Ma WJ, Zhao Q, Zhao X, Wang YZ, et al. [Comparison of ultraviolet A and ultraviolet B on 1,25-dihydroxy-vitamin D3 and bone metabolism in ovariectomized rats]. *Beijing Da Xue Xue Bao Yi Xue Ban*. 2013;45(3):392-7. [Chinese]
28. Júnior JAG, Nóbrega F, Oliveira PG, Bergamo ET, Cadore U, Gomes MZDV, et al. Evaluation of Implant Surface Modification with Nanohydroxyapatite Associated with the Use of L-PRF: In Vivo Study in Rats. *J Funct Biomater*. 2023;14(7):370.