

Piriform Sinus Neurofibroma in a Patient with Neurofibromatosis Type 1: A Case Report

S. Mirfendereski (MD)¹, S. Shahhosseini (MD)², S. Rezaei (MD)³, M. Soltan (MD)^{*4}

1. Department of Radiology, School of Medicine, Isfahan University of Medical Sciences, Isfahan, I.R.Iran.

2. Department of Anesthesiology, School of Medicine, Isfahan University of Medical Sciences, Isfahan, I.R.Iran.

3. Imam Hossein Hospital, Isfahan University of Medical Sciences, Isfahan, I.R.Iran.

4. Department of Pathology, School of Medicine, Isfahan University of Medical Sciences, Isfahan, I.R.Iran.

*Corresponding Author: M. Soltan (MD)

Address: Department of Pathology, School of Medicine, Isfahan University of Medical Sciences, Isfahan, I.R.Iran.

Tel: +98 (81) 31310835. E-mail: maryam.soltan1367@gmail.com

Article Type

ABSTRACT

Case Report

Background and Objective: Neurofibromatosis is a medical disorder associated with nerve and skin tumors. These tumors can affect the brain, spinal cord and peripheral nerves. The present study was conducted to introduce a rare case of piriform sinus neurofibroma in a patient with neurofibromatosis type 1.

Case Report: The patient is an 11-year-old boy who had a history of surgery for neurofibroma on the right side of the neck and was referred for mass removal surgery due to a palpable mass on the left side of the neck, with no other specific symptoms. During the preparation for the surgery, the anesthesiologist noticed a mass in the larynx area, which led to surgery cancellation and the MRI images were reviewed again. After two weeks, the patient returned to the hospital to have the laryngeal mass removed. During laryngoscopy, the surgeon identified and removed a submucosal mass in the larynx area. After examination of the lesion by a pathologist, asymptomatic neurofibroma was diagnosed. The primary treatment for this patient included surgery to remove the neurofibromatosis-associated tumors. The result of the treatment was successful, and a one-year follow-up treatment was carried out, which included post-surgery care, periodical imaging, evaluation of the nervous system and examination of other symptoms of neurofibromatosis along with close monitoring.

Conclusion: Based on the results of this study, the identification of neurofibromatosis-associated masses in uncommon places such as the larynx requires precision in imaging and surgical evaluations.

Keywords: *Neurofibroma, Piriform Sinus, Case Report, Genetic Disorders.*

Received:

Apr 10th 2024

Revised:

Jun 9th 2024

Accepted:

Jul 13rd 2024

Cite this article: Mirfendereski S, Shahhosseini S, Rezaei S, Soltan M. Piriform Sinus Neurofibroma in a Patient with Neurofibromatosis Type 1: A Case Report. *Journal of Babol University of Medical Sciences*. 2025; 27: e7.

Introduction

Neurofibromatosis is a genetic disease with neurocutaneous manifestations that can lead to nerve tumors in the brain, spinal cord and peripheral nerves. Peripheral nerve tumors are often benign; however, there is a possibility of turning into a malignant tumor (1). This tumor is primarily composed of Schwann cells (SCs) arising from a peripheral nerve and usually affects the skin or subcutaneous tissue (2). One area that is rarely affected by this disease is the larynx, the most common presenting symptom of which is stridor, and the most common tumor location in the larynx is the aryepiglottic fold (3).

In this regard, Kasapoglu et al presented a case report in which a 5-year-old boy had hoarseness and gradual increase in shortness of breath and snoring during sleep. At the beginning of the physical examination, he had a hoarse voice and stridor, and computed tomography of the neck showed a cystic lesion of 2×3 cm in the posterior part of the piriform sinus, at the level of the glottis and supraglottis (4). Varela-Goodall et al. also presented a 3-month-old boy with a medical history of prematurity and gastroesophageal reflux, who had persistent inspiratory stridor since he was a one-month-old baby and it was aggravated after crying (5). Chinn et al. also reported an 8-year-old boy with neurofibromatosis type 1 who had no history of airway obstruction and was asymptomatic without dyspnea, dysphagia, or dysphonia. Laryngoscopy showed a submucosal mass that extended in the center of the left aryepiglottic fold to the bottom of the laryngeal ventricle and the inner wall of the piriform sinus (3).

Therefore, studying piriform sinus neurofibroma in patients with neurofibromatosis is of great importance because this disease can lead to the formation of nerve tumors in rare areas of the body that require special treatment and management facilities. The study of such tumors can help to improve diagnosis, more accurate treatment planning and better prediction of results, and can also lead to progress in understanding the underlying mechanisms of this disease and the development of new treatment strategies. The aim of this report is to introduce a rare case of piriform sinus neurofibroma in a patient with neurofibromatosis type 1.

Case Report

This study was approved by the ethics committee of Isfahan University of Medical Sciences with the code IR.ARI.MUI.REC.1403.036. The patient is an 11-year-old boy who had a history of neurofibroma surgery on the right side of the neck. He was referred for the removal of the mass due to a palpable mass on the left side of the neck, and at the time of the visit, he did not have any other specific symptoms. After performing ultrasound and MRI, he was referred to Imam Hossein Hospital in Isfahan for mass removal surgery (Figure 1).

During the intubation, the anesthesiologist noticed a lump in the larynx area, so the surgery was canceled and the MRI images which were taken at another center were sent for review. In the re-examination of the MRI images, a mass was seen in the right piriform sinus area with the involvement of the aryepiglottic fold, which caused partial airway obstruction (Figure 2).

After two weeks, the patient returned to the hospital for laryngeal tumor surgery. During a difficult laryngoscopy, the surgeon noticed the submucosal mass of the larynx and removed it. Finally, after examining the lesion, the pathologist diagnosed the patient with neurofibroma (Figure 3).

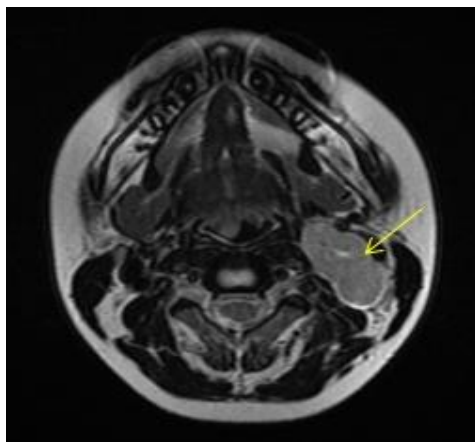


Figure 1. Axial T2 section of a hypersignal lesion on the left side of the neck

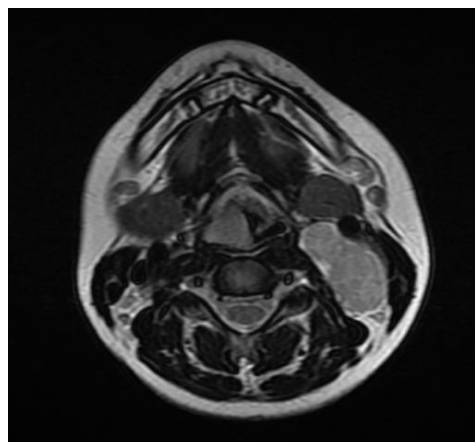


Figure 2. Axial T2-section image of a lesion on the right side of the larynx in the piriform sinus region

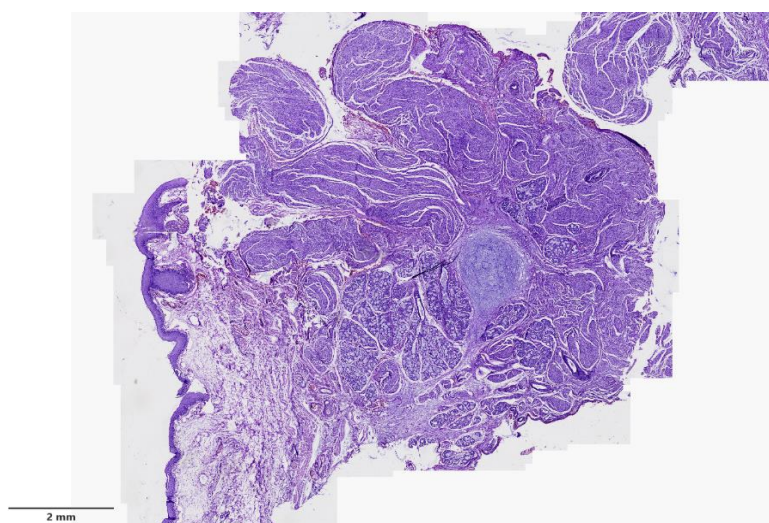


Figure 3. Neoplastic islands of spindle cells in the mucosa and submucosa of the pharynx at 20x magnification

The patient underwent regular physical and imaging examinations for one year, the condition of the patient's nervous and respiratory systems was checked to ensure that the tumor did not affect their function; there was no evidence of recurrence in the one-year follow-up.

Discussion

The findings of this study showed that neurofibroma in the piriform sinus region of patients with neurofibromatosis can appear as a mass, which may reveal airway obstruction symptoms. These masses may not be detected in initial imaging and require special attention in imaging evaluations such as MRI as well as attention to the patient's clinical symptoms. The follow-up of piriform sinus neurofibroma in patients with neurofibromatosis requires special attention in imaging and surgical evaluations so that possible complications and airway obstructions can be identified and treated in time.

Mahdoufi et al. reported a 4-year-old girl with obstructive respiratory symptoms who had a history of laryngeal stridor since birth that worsened during physical activity and screaming, with progressive dyspnea and nocturnal snoring. During her examination, laryngoscopy showed a mass that completely blocked the laryngeal vestibule. Pathological examination of the removed tissue showed plexiform neurofibroma after immunohistochemical examination. The patient was followed up regularly and remained asymptomatic (6). The difference between other reported cases and the present study was that in the present study, the patient did not show any specific diagnostic symptoms during the examination or in patient history. In their study, Voss-Hoynes et al. also incidentally noticed a unique, large retropharyngeal plexiform neurofibroma in a 17-year-old man. They state that our report simultaneously highlights the inherent variability of neurofibroma type I and suggests that imaging may be important in patients with a family history of neurofibroma type I in second-degree relatives who are asymptomatic (7). The findings of this study are in line with the findings of the present study and show that neurofibroma type 1 patients can sometimes be diagnosed accidentally without specific symptoms during other medical procedures.

Chinnu et al. reported an 8-year-old boy with neurofibromatosis type 1 who was evaluated for a supraglottic mass identified during intubation for a surgery unrelated to this disease. He had no history of airway obstruction and was free of dyspnea or dysphagia and it was asymptomatic. Physical examination revealed no stridor, retraction, or hoarseness. Laryngoscopy revealed a submucosal mass that extended in the center of the left aryepiglottic fold to the bottom of the laryngeal ventricle and the inner wall of the piriform sinus (3). This finding also confirms the findings of the present study regarding the nature of neurofibromatosis type 1 being asymptomatic. Mohd Ramli et al. reported a two-year-old girl who was presented with worsening stridor since birth and later progressive swelling of the left neck at 10 months of age. During the follow-up, ultrasound and MRI showed a lobulated solid mass in the deep space of the left neck, which extended to the midline and affected the airway by involving the supraglottic area (8).

In their study, Naik et al. reported a 59-year-old case with progressive hoarseness for 5 years, who showed a smooth submucosal spherical mass in the glottis and supraglottis on the left side. Histopathology showed neurofibroma. After confirming the findings in CT scan with contrast, the lateral thyrotomy method was used to remove the tumor. The authors stated that the lateral thyrotomy method is the ideal method to remove the mass and improve the voice quality (9). Skalias et al. reported a case of a 61-year-old woman

with sinonasal neurofibroma. According to the CT scan findings, the patient had a large invasive lesion originating from the left sinus and spreading to the adjacent structures. The patient underwent endoscopic tumor resection. The authors stated that open or endoscopic resection of the mass appears to provide satisfactory results (10).

This report shows the importance of accuracy in imaging evaluations and paying attention to the clinical symptoms of patients with neurofibromatosis. Consequently, the management of patients with neurofibromatosis who have unusual masses in complex areas such as the piriform sinus requires multidisciplinary collaboration between surgeons, radiologists, and anesthesiologists. Regular follow-up after surgery and the use of accurate imaging methods are necessary to evaluate changes in masses and prevent airway obstructions. This approach can help to improve treatment results and quality of life of patients.

Financial support: The costs of this article have been personally funded.

Conflict of interest: The authors deny any conflict of interest.

Acknowledgment

We would like to express our gratitude to the respected Vice President of Research and Technology of Isfahan University of Medical Sciences, the patient and his family, the surgical team and all the people who contributed in any way to the study.

References

1. Barkovich AJ, Koch BL, Moore KR. Diagnostic imaging: pediatric neuroradiology, 2nd ed. Elsevier; 2015. p.35.
2. Sakaguchi Y, Ikeda O, Ohgaki K, Oki E, Chinen Y, Sakamoto Y, et al. Totally Laparoscopic Gastrectomy for Gastric Cancer Associated with Recklinghausen's Disease. *Diagn Ther Endosc.* 2010;2010:682401.
3. Chinn SB, Collar RM, McHugh JB, Hogikyan ND, Thorne MC. Pediatric laryngeal neurofibroma: case report and review of the literature. *Int J Pediatr Otorhinolaryngol.* 2014;78(1):142-7.
4. Kasapoglu F, Özdemircan T, Erisen L. Laryngeal plexiform neurofibroma in a child. *Ear Nose Throat J.* 2013;92(6):E31-3.
5. Varela-Goodall N, Acosta MB, Scatolini ML, Cocciaglia A. Pediatric neurofibromatosis of the larynx: report of atypical location. *Arch Argent Pediatr.* 2023;121(3):e202202782.
6. Mahdoufi R, Barhmi I, Tazi N, Sami R, Abada R, Roubal M, et al. Plexiform Neurofibroma of the Larynx in Children: About an Unusual Case Report. *Arch Otolaryngol Rhinol.* 2016;2(1):035-7.
7. Voss-Hoynes HA, Mahfooz N, Ostwani W. A 17-Year-Old Male with Large Retropharyngeal Neurofibroma as the Only Symptom of Neurofibromatosis Type 1 (NF1): A Case Report and Review of Literature. *J Pediatr Neurol.* 2021;19(01):024-7.
8. Mohd Ramli SS, See GB, Zaki FM, Md Pauzi SH, Bin Amri MF. A Rare Tumor in the Neck of a Child: Plexiform Neurofibroma. *Turk Arch Otorhinolaryngol.* 2021;59(4):297-301.
9. Naik AD, Lambor D, Shetgaunkar R. Isolated paraglottic neurofibroma; lateral thyrotomy approach: a case report. *Int J Otorhinolaryngol Head Neck Surg.* 2018;4(4):1104-7.
10. Skalias A, Karamitsou P, Poutoglidis A, Skliris JP, Gougousis S. A Rare Case of a Large Sinonasal Neurofibroma. *Cureus.* 2022;14(12):e32202.