



The Effect of Dorzolamide Ophthalmic Drops in the Treatment of Patients with Central Serous Chorioretinopathy

R. Ebrahimi (MD)¹ , A. Moradi (PhD)² , B. Heydari (MD)³ , Gh. Yaghoobi (MD)³ ,
MA. Yaghoubi (MD)^{*4}

1.Department of Radiology, School of Medicine, Birjand University of Medical Sciences, Birjand, I.R.Iran.

2.Clinical Research Development Unit, Ghaem Hospital, Mashhad University of Medical Sciences, Mashhad, I.R.Iran.

3.Department of Ophthalmology, School of Medicine, Birjand University of Medical Sciences, Birjand, I.R.Iran.

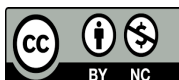
4.Metabolic Syndrome Research Center, Mashhad University of Medical Sciences, Mashhad, I.R.Iran.

*Corresponding Author: MA. Yaghoubi (MD)

Address: Department of Internal Medicine, Ghaem Hospital, Ahmad-Abad Street, Mashhad, I.R.Iran.

Tel: +98 (51) 38012742. E-mail: yaghoubima@mums.ac.ir

Article Type	ABSTRACT
Research Paper	<p>Background and Objective: Central Serous Chorioretinopathy (CSCR) is a common retinal disorder. The aim of this study was to evaluate the effectiveness of 2% dorzolamide eye drops in accelerating the recovery from acute CSCR.</p> <p>Methods: This single-blind non-randomized clinical trial included a total of 45 patients with acute CSCR. The case group (26 people who received 2% Dorzolamide eye drops twice a day for three weeks) and the control group (19 people) were studied. CSCR improvement rates were evaluated and compared by fundoscopic examination and Optical Coherence Tomography (OCT) images before and three weeks after the intervention.</p> <p>Findings: The two groups were homogeneous in terms of age, sex, and baseline visual acuity. Patients in Dorzolamide group showed a significant reduction in central macular thickness as measured by OCT for both the right ($-180.36 \pm 152.74 \mu\text{m}$, $p < 0.001$) and left ($-161.87 \pm 144.08 \mu\text{m}$, $p = 0.004$) eyes compared to control group. Moreover, 84.6% of patients in Dorzolamide group and 21% in the control group recovered from CSCR. CSCR recurred in two male patients in the control group, while no relapse was observed in Dorzolamide group within one month following treatment.</p> <p>Conclusion: Our findings suggest that the use of 2% Dorzolamide eye drops twice daily for three weeks significantly reduces central macular thickness, disease duration, one-month recurrence, and the need for laser treatment in patients with CSCR.</p> <p>Keywords: <i>Central Serous Chorioretinopathy, Dorzolamide, Optical Coherence Tomography.</i></p>
Received: Jun 18 th 2023	
Revised: Aug 20 th 2023	
Accepted: Dec 18 th 2023	
Cite this article: Ebrahimi R, Moradi A, Heydari B, Yaghoobi Gh, Yaghoubi MA. The Effect of Dorzolamide Ophthalmic Drops in the Treatment of Patients with Central Serous Chorioretinopathy. <i>Journal of Babol University of Medical Sciences</i> . 2024; 26: e65.	



Introduction

Central serous chorioretinopathy (CSCR) is a common visual disorder characterized by detachment of the retinal serous sensory layer as a result of local fluid leakage from the choroidal capillaries into the subretinal pigment epithelium cleft. However, the hypothesis of venous overload choroidopathy and genetic variants has also been proposed although (1-3). Although the disease pathogenesis is not fully understood, several risk factors have been identified including age, sex, smoking, race, high blood pressure, personality type A, psychological stress, corticosteroid use, serum cortisol levels, pregnancy, and helicobacter pylori infection (1, 4-8).

CSCR patients commonly exhibit several visual symptoms, including decreased visual acuity, micropsia, metamorphosis, color vision impairment, and dark spots in the center of the visual field (1, 9). Although CSCR is often self-limited and resolves within two to three months, it does not typically result in complete vision restoration (10, 11). Studies have shown that without treatment, approximately 50% of patients with persistent CSCR experience recurrence (9, 10). Moreover, over a 15-year follow-up period, around 10% of patients have had more than three recurrences, indicating a poor prognosis including retinal dysfunction and permanent vision loss (5, 12-14).

Several treatment options have been found to be effective for central serous chorioretinopathy (CSCR), including photodynamic therapy, oral mineralocorticoid antagonists, and MicroPulse laser treatment (2, 15). One of the available treatment modalities for CSCR is laser therapy. However, its use is currently restricted to certain conditions, such as bilateral disease or residual symptoms from a previous eye disease attack, due to side effects like central vision scotoma (15, 16). Carbonic anhydrase inhibitors (CAIs) are believed to enhance the absorption of subretinal fluid through the retinal pigment epithelium (RPE) (17-19). Two studies have demonstrated that oral administration of CAIs can accelerate the reduction of subretinal fluid in cases of CSCR (20, 21). It has been found that topical ophthalmic Dorzolamide is more effective than oral acetazolamide in inhibiting carbonic anhydrase activity in rat eye tissues (22). Additionally, there is evidence to suggest that Dorzolamide may be involved in resolving subretinal fluid (SRF) in cases of CSCR (23).

Based on current evidence, half-dose photodynamic therapy is considered the preferred treatment for CSCR, whereas observation may be appropriate for acute CSCR (15). However, it should be noted that predicting the prognosis of CSCR can be challenging and some cases may experience progressive visual loss despite treatment (18).

Given the potential therapeutic benefits of Dorzolamide drops in treating central serous chorioretinopathy (CSCR) and the limited research available in this area, the present study aimed to investigate the impact of Dorzolamide drops on accelerating the recovery from acute CSCR.

Methods

The study was approved by the ethics committee at Birjand University of Medical Sciences, Birjand, Iran (IR.BUMS.REC.1396.142). Furthermore, this study was registered at the Iranian Registry of Clinical Trials [IRCT20180703040323N1]. All patients with active files and confirmed acute CSCR (symptoms starting within the last three months) through ophthalmoscopy and optical coherence tomography (OCT) typical findings at Valiasr Hospital ophthalmology clinic were recruited in this single-blind non-randomized clinical trial. Patients with any other type of retinopathy rather than CSCR or lack of consent to participate in the study were excluded from the study. Comprehensive medical history with particular attention to steroids was recorded to identify any potential drug-induced acute CSCR.

Finally, the data of 45 available patients were analyzed. In this study, 26 patients received 2% Dorzolamide eye drops (Sina-Daru, Tehran, Iran) twice a day for three weeks. 19 patients were monitored in the control group. Demographic data, as well as OCT and fundoscopic findings, were compared between the two groups before and three weeks after the intervention. Recovery was defined as the complete resolution of fundoscopic findings and a reduction in central macular thickness in OCT to less than 300 μm (24).

Data analysis was performed using SPSS-22 software (Chicago, IL, USA). Comparisons between the two groups were made using Chi-square, Fisher's exact test, and independent and paired t-tests. The significance level was set at $p < 0.05$.

Results

This study was conducted on 45 patients with acute CSCR (33 men [73.3%]) in intervention ($n=26$) and control ($n=19$) groups. The mean age of all patients was 38.6 ± 6.4 years (from 23 to 51 years). The mean ages in the intervention and control groups were 39.6 ± 6.7 and 37.5 ± 5.9 years, respectively ($p=0.299$). Gender distribution was homogeneous between the two groups (80.8% and 63.2% in the intervention and control groups were respectively male). No significant difference was also observed for mean of baseline visual acuity between two study groups.

Most patients had only one eye involvement (22 patients in the right eye and 20 patients in the left eye), while only three patients had both eyes involvement. The baseline mean visual acuity for the affected right and left eyes were 8.36 ± 1.32 and 7.4 ± 1.8 , respectively.

Before the intervention, no significant difference was seen in the average OCT level between the two groups ($p=0.45$), while after the intervention, the Dorzolamide group had a significantly lower OCT compared to the control group ($p=0.005$) and in the intervention group, a significant decrease in the amount of OCT was observed after the intervention ($p < 0.001$) (Table 1).

Table 1. Comparison of OCT levels (μm) in Dorzolamide and control group before and after treatment

Group	Before Mean \pm SD	After Mean \pm SD	p-value*
Dorzolamide	487.98 ± 126.88	286.35 ± 61.07	<0.001
Control	409.84 ± 123.67	377.79 ± 119.76	0.13
p-value**	0.45	0.005	

*Paired t-test, **Independent t-test

Out of 26 patients with CSCR who received 2% Dorzolamide eye drops, 22 (84.6%) recovered and 4 (15.4%) did not respond to treatment; only four patients (21%) in the control group were cured and 15 patients (79%) did not recover (Figure 1). However, none of the patients in Dorzolamide group experienced a relapse of CSCR within one months after treatment, whereas in control group, two patients (both were male) had a recurrence of the disease. Although 21 out of 33 men and seven out of 12 women were recovered, gender distribution between the cured and uncured patients was non-significantly different.

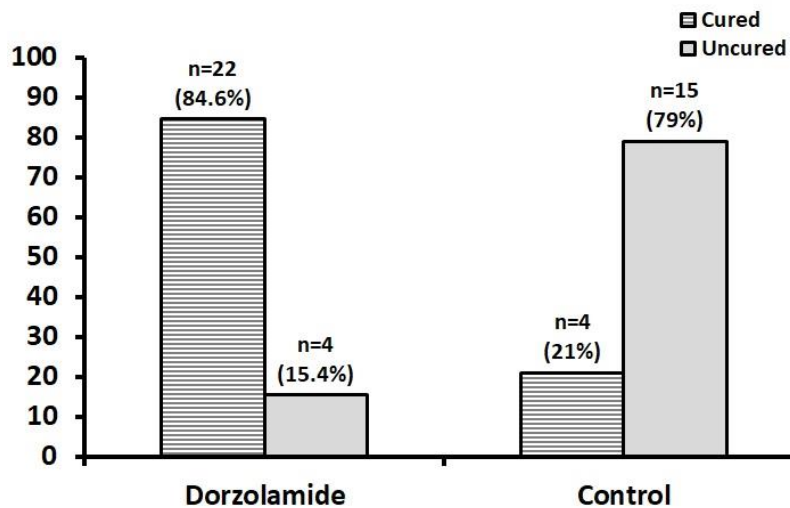


Figure 1. Comparison of the recovery rate between Dorzolamide and control groups

Discussion

The study results revealed a significant association between the use of Dorzolamide eye drops and OCT findings among CSCR patients. Patients who received Dorzolamide drops showed a noticeable improvement in central macular thickness and fundoscopic findings.

In a pilot study involving only four patients, it was found that using Dorzolamide eye drops (administered twice daily) was more effective than Nepafenac eye drops (a non-steroidal anti-inflammatory drug administered thrice daily) over the course of one month in quickly resolving acute central serous chorioretinopathy, as determined through fundoscopy and OCT results (25). In our previous case series study, we showed that topical Dorzolamide may improve best-corrected visual acuity and decrease subretinal fluid in patients with CSCR. This case series study demonstrated that topical Dorzolamide might be effective in the treatment of chronic central serous chorioretinopathy (26). According to Liew et al. topical CAI resulted in more rapid reduction of CMT compared to observation and may be a potential treatment in patients with chronic CSCR (23).

As a limitation of the present study, this sample size may not be sufficient to generalize the conclusions. Randomized clinical trials with reasonably bigger sample sizes with longer follow-up times are needed to confirm our findings.

According to the results of this study, there is a significant association between taking Dorzolamide eye drops and recovery from CSCR, and hence, patients who took the Dorzolamide drops had a greater response to treatment in OCT findings.

Acknowledgment

We would like to thank the Vice-Chancellor of Research and Technology of Birjand University of Medical Sciences for financial support, as well as the efforts of Mrs. Yazdani, the staff of eye clinic of Valiasr Hospital, and Mr. Gholamreza Sharifzadeh who collaborated in this study.

References

- 1.Liu B, Deng T, Zhang J. Risk Factors for Central Serous Chorioretinopathy: A Systematic Review and Meta-Analysis. *Retina*. 2016;36(1):9-19.
- 2.Zhang X, Lim CZF, Chhablani J, Wong YM. Central serous chorioretinopathy: updates in the pathogenesis, diagnosis and therapeutic strategies. *Eye Vis (Lond)*. 2023;10(1):33.
- 3.Wang M, Munch IC, Hasler PW, Prunte C, Larsen M. Central serous chorioretinopathy. *Acta Ophthalmol*. 2008;86(2):126-45.
- 4.Carvalho-Recchia CA, Yannuzzi LA, Negrão S, Spaide RF, Freund KB, Rodriguez-Coleman H, et al. Corticosteroids and central serous chorioretinopathy. *Ophthalmology*. 2002;109(10):1834-7.
- 5.Haimovici R, Koh S, Gagnon DR, Leherfeld T, Wellik S; Central Serous Chorioretinopathy Case-Control Study Group. Risk factors for central serous chorioretinopathy: a case-control study. *Ophthalmology*. 2004;111(2):244-9.
- 6.Bousquet E, Dhundass M, Lehmann M, Rothschild PR, Bayon V, Leger D, et al. Shift Work: A Risk Factor for Central Serous Chorioretinopathy. *Am J Ophthalmol*. 2016;165:23-8.
- 7.Venkatesh P, Gadia R, Tewari HK, Kumar D, Garg S. Prehypertension may be common in patients with central serous chorioretinopathy. *Graefes Arch Clin Exp Ophthalmol*. 2006;244(9):1101-3.
- 8.Bazzazi N, Ahmadpanah M, Akbarzadeh S, Seif Rabiei MA, Holsboer-Trachsler E, Brand S. In patients suffering from idiopathic central serous chorioretinopathy, anxiety scores are higher than in healthy controls, but do not vary according to sex or repeated central serous chorioretinopathy. *Neuropsychiatr Dis Treat*. 2015;11:1131-6.
- 9.Wang M, Sander B, la Cour M, Larsen M. Clinical characteristics of subretinal deposits in central serous chorioretinopathy. *Acta Ophthalmol Scand*. 2005;83(6):691-6.
- 10.Yannuzzi LA. Central serous chorioretinopathy: a personal perspective. *Am J Ophthalmol*. 2010;149(3):361-3.
- 11.Baran NV, Gürlü VP, Esgin H. Long-term macular function in eyes with central serous chorioretinopathy. *Clin Exp Ophthalmol*. 2005;33(4):369-72.
- 12.Liegl R, Ulbig MW. Central serous chorioretinopathy. *Ophthalmologica*. 2014;232(2):65-76.
- 13.Yap EY, Robertson DM. The long-term outcome of central serous chorioretinopathy. *Arch Ophthalmol*. 1996;114(6):689-92.
- 14.Ficker L, Vafidis G, While A, Leaver P. Long-term follow-up of a prospective trial of argon laser photocoagulation in the treatment of central serous retinopathy. *Br J Ophthalmol*. 1988;72(11):829-34.
- 15.Van Rijssen TJ, van Dijk EHC, Yzer S, Ohno-Matsui K, Keunen JEE, Schlingemann RO, et al. Central serous chorioretinopathy: Towards an evidence-based treatment guideline. *Prog Retin Eye Res*. 2019;73:100770.
- 16.Battaglia Parodi M, Arrigo A, Iacono P, Falcomatà B, Bandello F. Central Serous Chorioretinopathy: Treatment with Laser. *Pharmaceuticals (Basel)*. 2020;13(11):359.
- 17.Wolfensberger TJ, Mahieu I, Jarvis-Evans J, Boulton M, Carter ND, Nógrádi A, et al. Membrane-bound carbonic anhydrase in human retinal pigment epithelium. *Invest Ophthalmol Vis Sci*. 1994;35(9):3401-7.
- 18.Wolfensberger TJ. The role of carbonic anhydrase inhibitors in the management of macular edema. *Doc Ophthalmol*. 1999;97(3-4):387-97.
- 19.Cox SN, Hay E, Bird AC. Treatment of chronic macular edema with acetazolamide. *Arch Ophthalmol*. 1988;106(9):1190-5.
- 20.Pikkel J, Beiran I, Ophir A, Miller B. Acetazolamide for central serous retinopathy. *Ophthalmology*. 2002;109(9):1723-5.

- 21.Wuarin R, Kakkassery V, Consigli A, Roquelaure D, Papanastasiou A, Schutz JS, et al. Combined Topical Anti-inflammatory and Oral Acetazolamide in the Treatment of Central Serous Chorioretinopathy. *Optom Vis Sci*. 2019;96(7):500-6.
- 22.Terashima H, Suzuki K, Kato K, Sugai N. Membrane-bound carbonic anhydrase activity in the rat corneal endothelium and retina. *Jpn J Ophthalmol*. 1996;40(2):142-53.
- 23.Liew G, Ho IV, Ong S, Gopinath B, Mitchell P. Efficacy of Topical Carbonic Anhydrase Inhibitors in Reducing Duration of Chronic Central Serous Chorioretinopathy. *Transl Vis Sci Technol*. 2020;9(13):6.
- 24.Sabouri MR, Kazemnezhad E, Hafezi V. Assessment of Macular Thickness in Healthy Eyes Using Cirrus HD-OCT: A Cross-Sectional Study. *Med Hypothesis Discov Innov Ophthalmol*. 2016;5(3):104-11.
- 25.Shiv Sagar N, Ananthanag E, Sravani G, Usha Kiran R, Narayan M. A comparative study on efficacy of topical dorzolamide and topical nevanac in central serous retinopathy. *Int J Med Ophthalmol*. 2021;3(1):20-2.
- 26.Yaghoobi GH, Hosseinirad SA, Heydari S. Central serous chorioretinopathy treated with topical dorzolamide: A case series study. *J Surg Trauma*. 2018;6(4):141-4.