



Evaluation of Epithelial Cells of Oral Mucosae in Patients with Fixed Orthodontic Appliance

A. Shiva (DDS, MS)¹, F. Moaddabi (DDS)², S. Arab (PhD)³, M. Khatami (DDS, MS)⁴,
M. Zamanzadeh (DDS, MS)¹, M. Koochek Dezfouli (DDS, MS)¹,
A. Hossein Nataj (PhD)², P. Namdar (DDS, MS)^{*5}

1.Department of Oral and Maxillofacial Pathology, Faculty of Dentistry, Mazandaran University of Medical Sciences, Sari, I.R.Iran.

2.Dental Research Center, Mazandaran University of Medical Sciences, Sari, I.R.Iran.

3.Clinical Biochemist, Mazandaran, Sari, I.R.Iran.

4.Periodontist, Mazandaran, Sari, I.R.Iran.

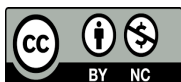
5.Department of Orthodontics, Faculty of Dentistry, Mazandaran University of Medical Sciences, Sari, I.R.Iran.

*Corresponding Author: P. Namdar (DDS, MS)

Address: Department of Orthodontics, Faculty of Dentistry, Mazandaran University of Medical Sciences, Sari, I.R.Iran.

Tel: +98 (11) 33241314. E-mail: dds.pnamdar@gmail.com

Article Type	ABSTRACT
Research Paper	<p>Background and Objective: Orthodontic appliances are usually in contact with the oral mucosa for a long time due to the length of the long-term treatment and are associated with problems due to the continuous contact and friction created. This study was conducted to investigate the epithelial cells of the mucosa of patients with fixed orthodontic appliances.</p> <p>Methods: In this cross-sectional study, smears were collected from three separate areas in 150 patients referred to the dental clinic of Mazandaran University: Area A (slide A): oral mucosa exposed to friction caused by orthodontic brackets, area B (slide B): oral mucosa exposed to friction with the tube on the orthodontic tape and Area C (slide C): oral mucosa without friction, i.e., the lower area of the oral cavity (control area). For histomorphometric analysis, each slide was evaluated with Papanicolaou staining using a light microscope, and the nuclear area (NA), cytoplasmic area (CA), and the ratio of nuclear area to cytoplasmic area (NA/CA) were recorded in square micrometers.</p> <p>Findings: The mean NA was 65.66 ± 22.11, CA was 717.37 ± 1846.53, and NA/CA was 0.037 ± 0.010 square meters. The difference in NA and CA between slides was significant ($p < 0.001$) (slide A < slide B < slide C) and NA/CA in slide A was significantly higher than the others. The only normal smear (class 1) and normal smear with inflammatory cells (class 2) were observed, and in terms of both NA and CA, slide C (control) had the highest amount. In terms of NA/CA in a normal smear, slide number 1 had the highest value.</p> <p>Conclusion: The findings of the study indicate that fixed orthodontic treatment has a significant impact on the nuclear and cytoplasmic area of affected areas compared to non-affected areas. Only some degree of inflammation may be seen in the areas exposed to the orthodontic appliance.</p> <p>Keywords: <i>Epithelial Cells, Oral Mucosa, Fixed Orthodontics, Histomorphometry, Papanicolaou Staining, Orthodontic Appliances, Cytotoxicity.</i></p>
Received: Jun 2 nd 2023 Revised: Jul 7 th 2023 Accepted: Sep 17 th 2023	
Cite this article: Shiva A, Moaddabi F, Arab S, Khatami M, Zamanzadeh M, Koochek Dezfouli M, et al. Evaluation of Epithelial Cells of Oral Mucosae in Patients with Fixed Orthodontic Appliance. <i>Journal of Babol University of Medical Sciences</i> . 2024; 26: e44.	



Introduction

Dental malformation represents an aberration from the natural course of growth and development, leading to a departure from the societal standards of beauty. Its onset during adolescence and youth has a significant impact on the musculoskeletal system (1, 2). The presence of irregular teeth can cause mental and social problems, thereby substantially affecting the individual's quality of life. Moreover, functional disorders of the teeth, such as chewing and speaking, and an increased risk of accidents and periodontal problems are common consequences of malocclusion (3). The oral cavity is lined with a mucous membrane that envelops all structures present inside the mouth, except the teeth. Epithelial cells of the oral cavity may undergo morphological changes in response to various pathological, infectious, traumatic, or metabolic factors, ultimately leading to mucosal lesions (4). Sometimes, the presence of such lesions may indicate serious medical conditions, such as malignant neoplasms or acute traumatic injuries. Nonetheless, a majority of these lesions are attributed to local stimulation. Prolonged exposure to low-intensity stimuli frequently precedes chronic conditions, commonly known as reactive lesions (5). The preservation of the mucous membrane's integrity is crucial for ensuring oral health. However, various factors, such as oral diseases, infections, trauma, or metabolic factors, may cause epithelial cells to undergo changes (6, 7). Fixed orthodontic appliances currently employed for the correction of dental malocclusion consist of brackets, braces, and archwires, composed of nickel, chromium, and cobalt alloys with varying proportions (8-10).

Studies indicate that fixed orthodontic devices result in the emission of metal ions due to electro galvanic currents generated by the presence of saliva (as an intermediate environment) or owing to metal corrosion. The oral milieu, particularly due to its heat, microbiological, and enzymatic characteristics, presents a conducive setting for metallic decomposition (11). Fixed orthodontic appliances may engender circumstances that lead to clinical modifications and neoplasms in the mucosal membrane and epithelial cells of the oral cavity. Orthodontic devices (ligatures, braces, wires, etc.) represent a significant source of trauma in the oral cavity (12). Friction occurring between brackets and mucosal tissue represents a form of chronic trauma with the potential to elicit buccal mucosa ulceration, a frequently encountered patient complaint during the course of orthodontic treatment. In addition, the existence of orthodontic devices within a healthy oral cavity leads to an increased accumulation of plaque and an alteration in the microbial flora, which can exacerbate the customary periodontal and mucosal biology (13).

The majority of oral lesions are responses to localized irritation and do not cause any threat. Infrequently, oral lesions may serve as an early indication of severe oral diseases. Generally, the most prevalent oral lesions are linked to trauma. Patients undergoing orthodontic treatment are frequently associated with various oral complications such as tongue inflammation or glossitis, gingivitis, gingival hyperplasia, etc. (14, 15). In the course of orthodontic treatment, orthodontic devices remain in the patient's oral cavity for approximately one and a half to two years, thus creating a potentially opportune environment for the gradual release of metal ions, which can cause DNA damage through direct incorporation of these ions with DNA (16). An orthodontic appliance or removable denture that is ill-fitting, rough, or broken, or a tooth surface that is broken or irregular can have an impact on the surrounding soft tissues. Additionally, acute or severe trauma to oral tissues can result in deeper involvement and consequently cause hematoma, erosion, or wound (17).

Normally, the trauma agent acts gradually and induces a reactive lesion in the oral cavity with low tissue intensity. Pain and discomfort are common during orthodontic treatment as a result of trauma caused by devices and increased friction between the mucosal tissue and the surface of the brackets and tubes (18). Although such lesions are temporary and may be insignificant to orthodontists, they can decrease patient

compliance to treatment and cooperation. Each of the oral lesions has clinical features and characteristics and a history that makes it possible for clinicians and orthodontists to identify these lesions with these clinical characteristics (19). These symptoms make accurate diagnosis difficult and may explain the frequent delay in early treatment (20).

However, epidemiological and histological studies on this issue in orthodontic patients are very rare. Some studies have reported the existence of genotoxic effect of orthodontic alloys, and the decrease in the size of the nucleus of buccal mucosa cells in response to orthodontic bracket placement has been shown (14). In addition, orthodontic appliances have a significant effect on periodontal tissue, oral environment and oral microfilm (21). Considering the small number of studies in this field and also the lack of accurate information about the effect of fixed and mobile orthodontic devices on oral mucosa and epithelial cells, this study was conducted with the aim of investigating oral mucosa epithelial cells in patients with fixed orthodontics.

Methods

In this cross-sectional study, after being approved by the ethics committee of Mazandaran University of Medical Sciences with the code IR.MAZUMS.REC.1401.255, the study population was selected from among the patients referred to the dental clinic of Mazandaran University using simple random sampling in the years 2022-2023. In the initial stages of this study, the primary purpose of the investigation and its individual steps were thoroughly explicated to each and every participant involved in the study, and after obtaining written consent, the subjects were included in the study. To evaluate the objectives of the study utilizing the following formula, as well as the incidence of oral mucosal lesions in compliance with previous studies (22) ($p=0.15$) and with a confidence interval of 0.95, in addition to an error value (d) of 10%, 50 samples were allotted to each of the case and control groups, resulting in a total of 150 samples considered for the sample size.

The inclusion criteria encompassed patients who had a fixed orthodontic appliance in at least one jaw and had a minimum of one month elapsed since its fixation. Moreover, the duration of employing the appliance was restricted to a maximum of three months. Additionally, periodontal health status was assessed prior to initiating orthodontic treatment. Patients with a tendency for smoking, consumption of antibiotics within the last three months, and affliction with systemic illnesses were excluded from the study. Furthermore, homogeneity in terms of the type and brand of all brackets was mandated for the study, and anomalous and non-uniform cases were excluded.

At the beginning of the test, the demographic details of the patients, including their age and gender, were noted down. Subsequently, to scrutinize the epithelial cells, the exfoliation of the mouth cells of the buccal mucous membrane was executed. The patient's mouth was primarily rinsed with water to eliminate extraneous matter and bacteria inside the mouth. Then, smears were acquired from three distinct areas:

Area A (slide A): Oral mucosa exposed to friction caused by orthodontic brackets

Area B (slide B): Oral mucosa exposed to friction with the tube on the orthodontic band

Area C (slide C): Non-frictional oral mucosa, i.e., the lower area of the oral cavity (control area).

Squamous epithelial cells were obtained using a cytobrush (14) and filtered using Universal Collection Medium through filterogen polycarbonate membrane filters with a pore size of 5 μm and a diameter of 25 mm that were firmly attached to glass slides. The glass slides were immediately treated with absolute alcohol for 20 minutes, and then the smears were exposed to normal Papanicolaou stain. In order to enable histomorphometric analysis, every slide was assessed by three pathologists making use of an Olympus BX41 light microscope (Camerolucida plotting microscope), which was connected to a computer.

A systematic approach was utilized to randomly select and measure three areas and fifty cells within each patient in a cohort of 50 people. The cellular images were captured using a digital color video camera, with a magnification of 40 and 100, respectively. The areas of the nucleus (NA) and cytoplasm (CA) were quantified by delineating the nuclear and cell border areas in square micrometers. Analysis was conducted using the system's digital cursor in image mode, and the NA/CA ratio was subsequently obtained. In lens 4: the obtained number was $\times 25$, In lens 10: the obtained number was $\times 10$, In lens 40: the obtained number was $\times 2.5$, In lens 100: the obtained number was not multiplied by a number because it was in magnification $\times 100$ (Figure 1).

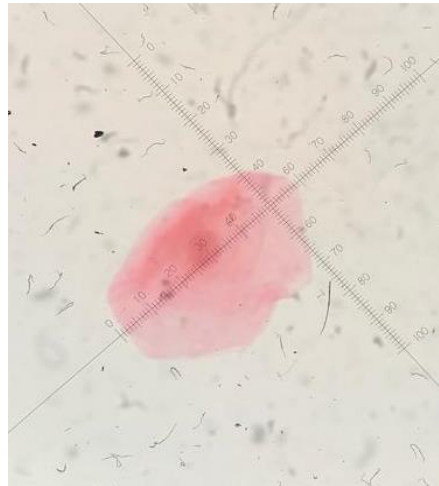

Figure 1. Oral epithelial cell with 100 magnification and with Papanicolaou staining and measurement based on micrometer

Cytomorphological examination: For cytomorphological examination of every slide using light microscopy, all cell attributes were categorized based on the Papanicolaou system classification, which includes normal, inflammatory, reactive, degenerative, and neoplastic conditions of oral epithelial cells. Additionally, the prevalent cell type or cellularity in each specimen was evaluated through enumeration. The findings were then categorized as follows: Class 0: insufficient material, Class 1: normal smear, Class 2: normal smear + inflammatory changer, Class 3: dysplastic changes, Class 4: not completely indicative, Class 5: malignant smear (14).

Mean, standard deviation, median, minimum and maximum indices were used to describe the research sample. Independent T-test, analysis of variance and Tukey's multiple comparisons were used to examine the mean values of variables in the groups. To evaluate the hypothesis of normality, Kolmogorov-Smirnoff test was used and the equality of variances were evaluated by Levene's test. SPSS 23 was used for analysis and $p < 0.05$ was considered significant.

Results

In total, the descriptive information related to the variables was recorded, revealing a mean NA of 65.66 ± 22.11 , a mean CA of 717.37 ± 1846.53 , and a mean NA/CA of 0.037 ± 0.010 . The mean values of the variables were documented and analyzed separately with respect to slide letter, as presented in Table 1. Notably, the mean NA exhibited a significant correlation with slide letter, with slide letter C exhibiting the highest value and slide A exhibiting the lowest value. Moreover, the mean CA displayed noteworthy

discrepancies across the three slides, with slide C demonstrating the highest value and slide A exhibiting the lowest value. Lastly, the mean NA/CA also exhibited a significant correlation with slide letter, with slide A demonstrating the highest value.

In Table 1, the mean values of variables were reported by class number. It was observed that there were no significant differences in the mean values of the variables in the two classes. 62% of the patients were women. Table 1 shows that the mean values of NA and CA were significantly higher in women. However, no difference was observed between the two sexes concerning NA/CA. There were significant differences between the mean CA and NA/CA in three studied age groups ($p < 0.05$).

Considering the significance of all three variables, pair-by-pair comparisons showed that in every instance of the three variables, there existed a significant distinction between the slides, with the exception of mean NA/CA in slides B and C, which did not demonstrate a significant difference.

Furthermore, the mean values of all three variables within class 1 differed significantly across different slides (Table 2). In regards with NA and CA, slide C had the highest value in class 1, whereas slide A had the highest value in terms of NA/CA. As for class 2, the mean values of NA and CA variables across different slides were significantly different, with slide C demonstrating the highest value. In both male and female subjects, there was a significant difference in the mean values of all three variables across different slides. Additionally, there was a noteworthy discrepancy in the mean values of NA and CA across all three age groups when considering different slides. Notably, in the age group below 15 years, there existed a significant distinction in mean NA/CA across the three slides, while this was not observed in other age groups.

Table 1. Comparison of variables according to slide letter, class, age group and gender

Variable	NA ^{***} Mean±SD	CA ^{***} Mean±SD	NA/CA ^{***} Mean±SD	Number(%)
Slide				
A	47.91±9.79 ^a	1238.37±265.43 ^a	0.040±0.011 ^a	50(33.3)
B	60.07±8.98 ^b	1718.03±375.47 ^b	0.036±0.008 ^b	50(33.3)
C	89.01±19.99 ^c	2583.21±635.63 ^c	0.036±0.010 ^c	50(33.3)
p-value*	<0.001	<0.001	0.001	-
Class				
1	66.00±22.24	1853.59±723.45	0.037±0.009	138(92)
2	61.68±20.51	1765.36±645.81	0.038±0.019	12(8)
p-value**	0.260	0.480	0.694	-
Gender				
Female	67.33±24.02	1903.70±735.40	0.037±0.011	31(62)
Male	62.93±18.33	1753.27±678.74	0.038±0.008	19(38)
p-value**	0.040	0.031	0.485	-
Age (year)				
<15	67.22±20.90	1852.89±679.27 ^{ab}	0.038±0.012 ^{ab}	21(42)
15-20	63.33±24.21	1691.62±646.51 ^a	0.039±0.008 ^a	17(34)
>20	66.22±20.96	2054.86±822.68 ^b	0.034±0.009 ^b	12(24)
p-value**	0.259	<0.001	0.001	-

*Analysis of variance, **Independent T-test

***Different lowercase letters indicate significant differences in slides or age groups

Table 2. Comparison of variables according to different slides by class, gender and age group

Variable	NA ** Mean±SD	CA ** Mean±SD	NA/CA ** Mean±SD	Number(%)
Class 1				
Slide A	47.28±8.54 ^a	1212.31±224.65 ^a	0.040±0.008 ^a	43(31.2)
Slide B	59.40±8.54 ^b	1686.56±364.61 ^b	0.036±0.008 ^b	46(33.3)
Slide C	88.64±19.98 ^c	2573.15±633.13 ^c	0.036±0.010 ^b	49(35.5)
p-value*	<0.001	<0.001	0.001	-
Class 2				
Slide A	351.80±15.1 ^a	1398.42±413.02 ^a	0.041±0.024	7(58.3)
Slide B	67.61±10.78 ^b	2079.86±314.17 ^b	0.033±0.008	4(33.3)
Slide C	107.08±1.43 ^c	3075.88±683.12 ^c	0.036±0.010	1(8.4)
p-value*	<0.001	<0.001	0.564	-
Female				
Slide A	49.06±10.84	1264.75±282.69	0.040±0.013	31(33.3)
Slide B	60.36±9.07	1780.78±347.43	0.035±0.007	31(33.3)
Slide C	92.58±22.64	2665.56±647.20	0.036±0.011	31(33.3)
p-value*	<0.001	<0.001	0.002	-
Male				
Slide A	46.03±7.51	1195.32±230.49	0.040±0.008	4(33.3)
Slide B	59.57±8.89	1615.65±399.49	0.038±0.009	4(33.3)
Slide C	83.18±12.84	2448.83±597.68	0.035±0.008	4(33.3)
p-value*	<0.001	<0.001	0.030	-
Age group<15				
Slide A	49.69±11.83	1228.61±220.37	0.042±0.015	21(33.3)
Slide B	62.03±10.17	1739.59±348.72	0.036±0.008	21(33.3)
Slide C	89.93±14.75	2590.47±516.83	0.0361±0.010	21(33.3)
p-value*	<0.001	<0.001	0.009	-
Age group 15-20				
Slide A	45.01±6.95	1136.21±141.90	0.040±0.007	17(33.3)
Slide B	58.41±7.19	1567.08±284.70	0.038±0.007	17(33.3)
Slide C	86.56±27.65	2371.58±606.14	0.038±0.008	17(33.3)
p-value*	<0.001	<0.001	0.382	-
Age group>20				
Slide A	48.89±8.50	1400.17±377.92	0.037±0.009	12(33.3)
Slide B	58.93±8.62	1894.12±450.59	0.033±0.008	12(33.3)
Slide C	90.84±14.46	2870.30±0.756.21	0.033±0.008	12(33.3)
p-value*	<0.001	<0.001	0.081	-

*Analysis of variance, **Different lowercase letters indicate significant differences in slides

Discussion

In this study, three slides were examined according to three different areas of the patients' mouth; Slide A corresponds to region A (oral mucosa exposed to friction caused by orthodontic brackets), slide B corresponds to region B (oral mucosa exposed to friction with the tube on the orthodontic tape) and slide C

corresponds to region C (oral mucosa without friction which was actually the lower area of the oral cavity [control area]). The results demonstrate a significant correlation between the nuclear area (NA) and the slide letter. Specifically, slide C exhibited the highest value while slide A demonstrated the lowest value. In other words, the size of the nucleus in the regions that were exposed to the tube was smaller, whereas those exposed to the bracket were larger. The largest size was observed in the control group, which can be considered as the normal size (21). In a study conducted by Rafighi et al., which investigated the changes in epithelial cells of the lower lip following the removal of fixed orthodontic appliances, it was noted that the NA values significantly increased after the removal of friction and stimulation of orthodontic appliances at 30 and 60 days after removal. The highest level was reached at 60 days after separation (22). The study conducted by Rafighi et al. has validated the findings of the current research and has established that greater contact with orthodontic devices within the oral cavity leads to a reduction in the nuclear area of epithelial cells in the oral mucosa. In the investigation conducted by Francis et al., the impact of fixed orthodontic appliances on epithelial cells of the buccal mucosa in patients undergoing orthodontic treatment was evaluated. The results of this study indicated a rise in the number of micronuclei during different stages of treatment over time (23). This observation further corroborates the decrease in nuclear area observed in our research.

The current study demonstrated a significant difference in mean cytoplasmic areas (CA) among the three distinct areas, with slide C exhibiting the highest amount and slide A having the lowest amount of CA. In other words, the cytoplasmic regions in contact with the orthodontic tube exhibited a smaller size, whereas those in contact with the bracket demonstrated a larger size. The largest cytoplasmic size was observed in the control group, which can be considered the normal size. The results of studies by Rafighi et al., Francis et al., were in line with the results of the present study and they also confirmed the reduction of cytoplasmic area in the areas in contact with orthodontic appliances, which increased towards normal after 60 days of removing the appliances (22, 23).

The results of the data analysis indicated that the mean ratio of nuclear area to cytoplasmic area (NA/CA) in slide 1 was markedly higher than that of the other two groups. However, no significant difference was observed between slide B and slide C. Consequently, the alterations in the area that were in contact with the friction caused by the orthodontic brackets were substantial. In these areas, the reduction in the area of the nucleus was comparatively less than that of the cytoplasm. In a study conducted by Rafighi et al., alterations in cell morphology in three areas of the oral mucosa, namely, the lower incisor, upper molar, and upper canine, were examined following the removal of the orthodontic appliance. The findings revealed that, except in the lower incisor area, a significant increase in the ratio of nuclear area to cytoplasmic area was evident in cells that were in contact with the device (22). This issue can occur due to the increase in cell activity after orthodontic device removal (23) and due to the difference in the method of the two studies, the results cannot be compared one to one. The study of Rafighi et al. exhibited results that were contradictory to those of the present study, as it demonstrated no significant alteration in NA/CA values up to 60 days after removing orthodontic appliances (22). The reason for the difference in the present study and the study of Rafighi et al. is that different areas were sampled; In the study of Rafighi et al., it is from the oral mucosa in the lower lip area but in the present study, it could be scattered in slide A or B, according to the location of orthodontic brackets and tubes; Therefore, the results of the two studies cannot be compared.

In the present study, each slide underwent coding in accordance with the Papanicolaou system, with particular emphasis on class 1 (normal smear) and class 2 (normal smear with inflammatory changes). Within class 1, specifically with respect to NA and CA, slide C (control) and slide A had the greatest values. Conversely, in class 2, slide C exhibited the highest NA and CA levels, although no statistically significant

differences were observed between the various slides in terms of NA/CA. The tissues that were exposed to the tubes were found to display greater inflammation, whereas the tissues exposed to the brackets exhibited less inflammation than the tubes. Finally, the tissues of the control group, which experienced less inflammation from both the tube and the bracket, were deemed normal. In the research conducted by De Arruda et al., it was observed that in classes 1 and 2 based on the Papanicolaou system, the justification for similar results is more pronounced due to the resemblance in the mucus sampling areas (24). Rafighi et al. reported that class 1 has been observed as the predominant cellularity in all areas and up to 60 days after device delivery (22). In the study of Omidkhoda et al, it was observed that orthodontic acrylic appliances may promote some transient cytometric effects. It seems that they do not cause any significant damages to the oral mucosa in the long term (25).

The dissimilarity in the observations could be attributed to the variance in the duration of the examination subsequent to the acquisition of the orthodontic appliance. Previous studies were limited to a maximum duration of two months after delivery, whereas the current study included a criterion of using the appliance for at least one month, with possible use extending beyond two months, thus increasing the likelihood of the emergence of inflammatory cells after two months.

The findings of the study indicate that fixed orthodontic treatment has a significant impact on the nuclear and cytoplasmic area of affected areas compared to non-affected areas. Specifically, areas exposed to friction caused by orthodontic brackets and tubes exhibited a significant decrease in nuclear and cytoplasmic area. Additionally, the ratio of nucleus to cytoplasm in these areas was significantly higher than in other areas, indicating a less pronounced decrease in the nuclear area compared to the cytoplasmic area. The examined slides showed only normal smear and normal smear with inflammatory cells, with slide C (control) displaying the highest levels of both NA and CA. In terms of NA/CA in normal smear, slide A had the highest amount, but in normal smear containing inflammatory cells, no significant difference was observed between the slides.

Acknowledgment

We would like to express our gratitude to the Deputy of Research and Technology and the Ethics Committee of Mazandaran University of Medical Sciences for their support and staff of Noor Laboratory (Ramezan Ghafari) who helped us in the preparation of the patient's sample, the preparation of H&E slides, and immunohistochemistry staining report.

References

1. Namdar P, Pourasghar M, Lal Alizadeh F, Shiva A. Anxiety, Depression, and Quality of Life in Caregivers of Children with Cleft Lip and Palate: A Systematic Review. *Iran J Psychiatry Behav Sci.* 2022;16(2):e113591.
2. Macey R, Thiruvengkatachari B, O'Brien K, Batista KBSL. Do malocclusion and orthodontic treatment impact oral health? A systematic review and meta-analysis. *Am J Orthod Dentofacial Orthop.* 2020;157(6):738-44.e10.
3. Prado LH, Previato K, Delgado RZR, Nelson Filho P, Bezerra Segato RA, Nakane Matsumoto MA, et al. Adolescents' perception of malocclusion, their motivations, and expectations concerning the orthodontic treatment. Is it all about attractiveness? A qualitative study. *Am J Orthod Dentofacial Orthop.* 2022;161(4):e345-52.
4. Salehabadi N, Nasirian Z, Mokhtarpour H, Bamdadian T, Ramezani A, Mousavi SJ, et al. Evaluating the Distance between Parotid Papilla and Occlusal Plane in Dentate Patients. *J Mazandaran Univ Med Sci.* 2022;32(208):102-12. [In Persian]
5. Salehabadi N, Pournasiri N, Bamdadian T, Dadgar K, Mokhtarpour H, Khalilian A, et al. Parallelism of the Occlusal Plane with the Ala-tragus Line in Various Posterior References in Dentate Patients. *J Mazandaran Univ Med Sci.* 2022;31(204):102-10. [In Persian]
6. Yi J, Lu W, Xiao J, Li X, Li Y, Zhao Z. Effect of conventional combined orthodontic-surgical treatment on oral health-related quality of life: A systematic review and meta-analysis. *Am J Orthod Dentofacial Orthop.* 2019;156(1):29-43.e5.
7. Bourzgui F, Elmoutawakil A, Diouny S, Elquars F. The impact of malocclusion on oral health related quality of life in orthodontic patients. In: Khursheed Alam M, Qamruddin I, Purmal K, editors. *Malocclusion: Causes, Complications and Treatment (Dentistry and Oral Sciences)*, 1st ed. Hauppauge, NY, USA: Nova Science Pub Inc; 2018. p. 68-72.
8. Elyashil M, Shafai NAA, Mokhtar N. Effect of malocclusion severity on oral health related quality of life in Malay adolescents. *Health Qual Life Outcomes.* 2021;19(1):71.
9. Amini F, Farhadi S, Shahbeik S, Mahvash Mohammadi M, Rakhshan V. Effects of fixed orthodontic treatment with and without chlorhexidine mouthwash on vitality of oral mucosal cells reflected by cell nuclear indexes: A preliminary 3-phase before-after clinical trial. *Int Orthod.* 2023;21(1):100722.
10. Yassir YA, McIntyre GT, Bearn DR. Orthodontic treatment and root resorption: an overview of systematic reviews. *Eur J Orthod.* 2021;43(4):442-56.
11. Apiwantanakul N, Chantarawatit PO. Cytotoxicity, genotoxicity, and cellular metal accumulation caused by professionally applied fluoride products in patients with fixed orthodontic appliances: A randomized clinical trial. *J World Fed Orthod.* 2021;10(3):98-104.
12. Primožič J, Poljšak B, Jamnik P, Kovač V, Čanadi Jurešić G, Spalj S. Risk Assessment of Oxidative Stress Induced by Metal Ions Released from Fixed Orthodontic Appliances during Treatment and Indications for Supportive Antioxidant Therapy: A Narrative Review. *Antioxidants (Basel).* 2021;10(9):1359.
13. Chantarawatit PO, Yanisarapan T. Exposure to the oral environment enhances the corrosion of metal orthodontic appliances caused by fluoride-containing products: Cytotoxicity, metal ion release, and surface roughness. *Am J Orthod Dentofacial Orthop.* 2021;160(1):101-12.
14. Pereira BR, Tanaka OM, Lima AA, Guariza-Filho O, Maruo H, Camargo ES. Metal and ceramic bracket effects on human buccal mucosa epithelial cells. *Angle Orthod.* 2009;79(2):373-9.
15. Shiva A, Sobouti F. Comparative study of histopathological reports and clinical diagnosis of oral biopsies. *J Mazandaran Univ Med Sci.* 2017;26(144):57-64. [In Persian]

16. Piñeda-Zayas A, Menendez Lopez-Mateos L, Palma-Fernández JC, Iglesias-Linares A. Assessment of metal ion accumulation in oral mucosa cells of patients with fixed orthodontic treatment and cellular DNA damage: a systematic review. *Crit Rev Toxicol.* 2021;51(7):622-33.
17. Domínguez A, Velásquez SA, Santamaría JS, Isaza GA. Effect of diode laser removal on traumatic ulcers during orthodontic treatments: a randomized controlled clinical trial. *Laser Dent Sci.* 2021;5:229-37.
18. Cruz JPP, Santos NCND, Pithon MM, de Moraes Marcílio Cerqueira E. Biomonitoring of children and adolescents using orthodontic appliances made of acrylic resins through micronucleus testing of exfoliated buccal and palatal mucosa cells. *Am J Orthod Dentofacial Orthop.* 2021;160(2):193-9.
19. Shiva A, Pakravan AH. Squamous Cell Carcinomas (SCC) of the Scalp in a Patient with History of Basal Cell Carcinoma (BCC); A Case Report. *J Babol Univ Med Sci.* 2017;19(1):55-60. [In Persian]
20. Shiva A, Nosrati K. A Calcifying Odontogenic Cyst Associated with Complex Odontoma: A Case Report. *J Babol Univ Med Sci.* 2015;17(2):57-61. [In Persian]
21. Mulimani P, Popowics T. Effect of Orthodontic Appliances on the Oral Environment and Microbiome. *Front Dent Med.* 2022;3:924835.
22. Rafighi A, Sohrabi A, Zokaee M, Moghaddam SF, Sharghi R. Evaluation of the epithelial cells of lower lip mucosa after debonding of fixed orthodontic appliances. *Minerva Stomatol.* 2020;69(4):245-50.
23. Francis PG, Thomas M, Antony V, Shaloob M, Hassan KJ, Roshan G. Cytomorphometric Analysis on the Effects of Components of Orthodontic Appliances on the Epithelial Cells of the Buccal Mucosa. *J Int Soc Prev Community Dent.* 2017;7(3):142-6.
24. de Arruda EP, Trevilatto PC, Camargo ES, Woyceichoski IE, Machado MA, Vieira I, et al. Preclinical alterations of oral epithelial cells in contact with orthodontic appliances. *Biomed Pap Med Fac Univ Palacky Olomouc Czech Repub.* 2011;155(3):299-303.
25. Omidkhoda M, Dehghani M, Mohtasham N, Sadeghian H, Malle E. Cytomorphometric Evaluation of Oral Mucosa among Children undergoing Acrylic Removable Orthodontic Appliances: An in vivo Study. *J Dent Mater Tech.* 2022;11(2):75-83.