



## Investigation of Vestibular Aqueduct in High-Resolution CT Scan in Patients with Otosclerosis

M. Pourasadegh (MD)<sup>1</sup> , R. Ahmadi (MD)<sup>1</sup> , M. Rajati (MD)<sup>1</sup> , J. Hashemi (MD)<sup>2</sup> ,  
B. Rasoulia (MD)<sup>1</sup> , M. R. Afzalzadeh (MD)<sup>\*1</sup>

1.Sinus and Surgical Endoscopic Research Center, Mashhad University of Medical Sciences, Mashhad, I.R.Iran.

2.Department of Radiology, Faculty of Medicine, Mashhad University of Medical Sciences, Mashhad, I.R.Iran.

Article Type	ABSTRACT
Research Paper	<p><b>Background and Objective:</b> Otosclerosis is caused by abnormal bone remodeling in the middle ear, which is associated with dizziness and lightheadedness. An underlying cause of dizziness in this disease can be the presence of an enlarged vestibular aqueduct. In this study, the prevalence of enlarged vestibular aqueduct in these patients compared to the normal population has been investigated.</p> <p><b>Methods:</b> In this cross-sectional study, 26 people with bilateral otosclerosis and 26 people with at least one healthy ear requiring a CT scan were compared. Vestibular aqueduct was tested by evaluating the two factors of the midpoint width between the external diaphragm and the common crus, and its width in the external diaphragm region and comparing the two groups. Bone conduction, speech detection threshold, and gap between bone conduction and air conduction were calculated and compared in otosclerosis patients with enlarged versus normal vestibular duct.</p> <p><b>Findings:</b> The median width of the vestibular aqueduct in the area of the external aperture in patients with otosclerosis (1.2 mm) was significantly greater than that of healthy subjects (1 mm) (<math>p=0.046</math>). Regarding the size of the vestibular aqueduct in otosclerosis patients, 5 patients (9.6%) were found with enlarged vestibular aqueduct in radiological findings. However, this difference was not statistically significant. In otosclerosis patients, bone conduction threshold in all frequencies was significantly higher in people with enlarged vestibular aqueduct compared to other patients (<math>p&lt;0.001</math>).</p> <p><b>Conclusion:</b> Based on the results of this study, the prevalence of enlarged vestibular aqueduct in patients with otosclerosis is considerable, and it is better to pay enough attention to the CT scan of patients before surgery to prevent possible complications.</p> <p><b>Keywords:</b> <i>Otosclerosis, Vestibular Aqueduct, Hearing Loss, CT Scan.</i></p>
Received: Aug 23 <sup>rd</sup> 2022	
Revised: Dec 31 <sup>st</sup> 2022	
Accepted: Mar 15 <sup>th</sup> 2023	

**Cite this article:** Pourasadegh M, Ahmadi R, Rajati M, Hashemi J, Rasoulia B, Afzalzadeh MR. Investigation of Vestibular Aqueduct in High-Resolution CT Scan in Patients with Otosclerosis. *Journal of Babol University of Medical Sciences*. 2023; 25(1): 327-33.



© The Author(S).

Publisher: Babol University of Medical Sciences

\*Corresponding Author: M. R. Afzalzadeh (MD)

Address: Department of Otorhinolaryngology, School of Medicine, Mashhad University of Medical Sciences, Mashhad, I.R.Iran.

Tel: +98 (51) 38413492. E-mail: Afzalzadehmr@mums.ac.ir

## Introduction

Otosclerosis is a primary focal osteodystrophy and a specific disease of the otic capsule that can cause conductive, mixed, and even sensorineural hearing loss (1). The mechanism of this phenomenon is through bone resorption, deposition of new bone and vascular proliferation (2). Clinically, otosclerosis involves both ears in 70% of cases. Conductive hearing loss, especially in low frequencies that can sometimes occur with sensorineural hearing loss, is the most common symptom of the disease and may appear gradually. Other symptoms include tinnitus, dizziness and loss of balance (3). Symptoms related to balance disorders have long been reported in otosclerosis patients and approximately 3-35% of otosclerosis patients have vestibular symptoms. It seems that vestibular symptoms in patients with otosclerosis can be caused by various causes, although opinions differ among researchers (4). One of the stated reasons is the possibility of enlarged vestibular aqueduct associated with this disease (5).

Enlarged vestibular aqueduct disease is a type of labyrinth abnormality that can result in gradual hearing loss. The hearing loss can be either sensorineural or conductive in nature. A CT scan is typically used to diagnose this abnormality, and if the width of the vestibular aqueduct is found to be larger than that of the posterior semicircular canal, the individual is often diagnosed with this disorder (6).

Cerebrospinal fluid gusher is a recognized complication of cochlear implant surgery (7). It is also a rare occurrence in stapedotomy procedures (8), and its risk is heightened in patients with an enlarged vestibular aqueduct. Notably, otosclerosis patients additionally face the potential risk of sensorineural hearing loss associated with this complication. (5).

No study has yet been conducted exclusively examining the status of the vestibular aqueduct in otosclerosis. Consequently, the present study aimed to investigate the status of the vestibular aqueduct in patients with otosclerosis in comparison to that in healthy individuals.

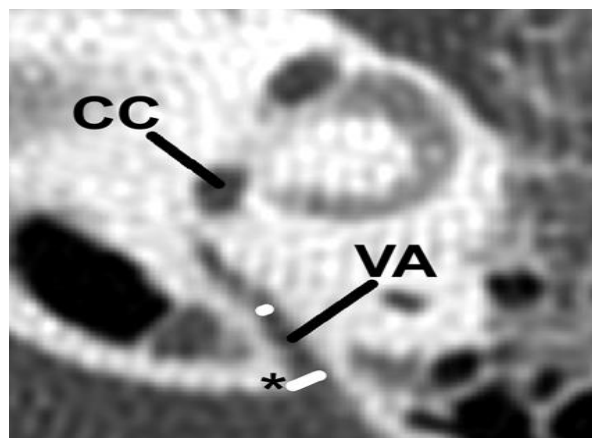
## Methods

This cross-sectional study was conducted after approval by the Ethics Committee of Mashhad University of Medical Sciences with code IR.MUMS.MEDICAL.REC.1397.449 in 2017-2018 at Imam Reza and Qaem teaching and research centers in Mashhad. In this study, 26 patients with otosclerosis and 26 people with at least one healthy ear, which was estimated by considering the possible prevalence of vestibular aqueduct anomalies in people with similar diseases and healthy people based on the findings of previous studies (2) and those who needed a CT scan for other reasons such as chronic otitis media in the opposite ear, or trauma, and so on were included in the study. Temporal CT scan (1.25 mm thickness images using 10 mm collimation and scan interval of 1.25 mm, 120 kVP, 320 mAs) was performed for all participants in the study.

Patients with conductive hearing loss with or without sensorineural component based on clinical history, normal otoscopy results, CHL>20 decibels at frequencies of 0.5-4 kHz, lack of acoustic reflex, candidates for surgery in Imam Reza and Qaem teaching and research hospitals with the diagnosis of otosclerosis, and having bilateral otosclerosis were included in the study. Patients with otosclerosis with one operated ear, unilateral otosclerosis according to audiometric criteria, history of previous ear infections, abnormal hearing in the control group and patients who were not willing to participate in the study or did not give written consent were excluded from the study.

In this study, the indices of the anatomical condition of the vestibular aqueduct of patients with otosclerosis, the morphology of the external diaphragm, bone conduction threshold and speech detection threshold, the gap between bone conduction and air conduction were measured at frequencies of 250, 500 and 1000 Hz. Imaging of the temporal bone was performed with the help of a high-quality CT scan without injection. Then reconstruction was done in several planes by Radiant DICOM Viewer (Digital imaging and communication in medicine). After that, the anatomical condition and vestibular diameter of the aqueduct were examined by a radiologist. The vestibular aqueduct was investigated by evaluating two factors: the midpoint width of vestibular aqueduct between the external aperture and the common crus and the vestibular aqueduct width at the external aperture (Figure 1). Based on the diagnostic criteria of Valvassori and Clemis, when the diameter of the vestibular aqueduct at its middle point is 1.5 mm or more or the length of the external aperture is more than 2 mm, the vestibular aqueduct is considered large (9).

The data obtained from this study were analyzed using SPSS software version 25 (SPSS Inc., Chicago, Illinois, USA). The data were described using centrality, dispersion, such as mean and standard deviation (median and interquartile range) and frequency percentage. The t-test or Mann-Whitney's non-parametric equivalent has been used to compare the mean of quantitative variables between two groups. The relationship between qualitative variables was investigated with chi-square test or Fisher's exact test, and  $p < 0.05$  was considered significant.



**Figure 1. Diameter of the midpoint of vestibular aqueduct (VA), diameter of external aperture (\*) and posterior circular vein (CC)**

## Results

A total of 26 patients with otosclerosis (52 ear cases) with a mean age of  $34.5 \pm 11.2$  years and 26 people with at least one healthy ear with a mean age of  $36.7 \pm 13.6$  years were included in the study. In terms of gender distribution, 65.4% were male and 57.7% were female, and no significant difference was observed between the two groups.

No difference was observed between the two groups in terms of the middle diameter index. However, the index of the vestibular width of the aqueduct in the area of the external aperture showed a significant difference between the two groups ( $p = 0.046$ ). These variables had higher values in the patient group. Also, in terms of vestibular aqueduct size in otosclerosis patients, 5 patients (9.6%) were found with enlarged

vestibular aqueduct in radiological findings. In the control group, no person was reported with the mentioned finding. However, this difference was not statistically significant (Table 1).

Then, the patients were categorized into two groups based on the size of the vestibular aqueduct: large size (n=5) and normal size (n=47). The bone conduction threshold and in other words sensory component in all frequencies in people with enlarged vestibular aqueduct was significantly higher than other patients ( $p<0.05$ ) (Table 2).

**Table 1. Examining the anatomical, morphological and imaging characteristics of the vestibular aqueduct among patients and healthy people**

Characteristics	Patient group (n=52) Median (interquartile range) or Number(%)	Healthy people (n=26) Median (interquartile range) or Number(%)	p-value
Median diameter of vestibular aqueduct (mm)*	0.9 (0.8-1.1)	0.9 (0.5-1.1)	0.09
The vestibular width of the aqueduct in the area of the external aperture (mm)*	1.2 (1.0-1.4)	1.0 (0.7-1.2)	0.046
<b>Vestibular aqueduct size**</b>			
Large	5(9.6)	0 (0)	0.16
Normal	47(90.4)	26 (100)	
<b>External aperture morphology**</b>			
Tubular	9(17.3)	9(34.6)	0.06
Filiform	38(73.1)	16(61.5)	
Funnel	5(9.6)	0(0)	

\*Mann-Whitney test, \*\*Fisher's exact test

**Table 2. Examination of audiometric findings in otosclerosis patients with large vestibular aqueduct and other patients**

Characteristics	Normal vestibular aqueduct (n=47) Median (interquartile range)	Enlarged vestibular aqueduct (n=5) Median (interquartile range)	p-value*
<b>Bone conduction threshold</b>			
250 Hz	10.0 (5.0-10.0)	25.0 (25.0-30.0)	<0.001
500 Hz	10.0 (10.0-10.0)	30.0 (25.0-35.0)	<0.001
1000 Hz	10.0 (10.0-20.0)	25.0 (22.5-45.0)	0.001
2000 Hz	20.0 (10.0-25.0)	32.5 (55.0-55.0)	0.001
4000 Hz	20.0 (10.0-30.0)	65.0 (45.0-65.0)	<0.001
Speech detection threshold	45.0 (40.0-50.0)	65.0 (62.5-65.0)	0.002
Gap	40.0 (28.0-35.0)	20.0 (20-30.0)	0.14

\*Mann-Whitney test

## Discussion

In the present study, the prevalence of enlarged vestibular aqueduct was estimated to be about 9.6%, which, despite being considerable, did not show a statistically significant difference compared to the normal population. The median width of the vestibular aqueduct in the area of the external aperture was significantly higher among patients with otosclerosis candidates for surgery compared to healthy subjects. In this study, the condition of the vestibular aqueduct in otosclerosis patients was investigated for the first time and all measurements were performed by an experienced radiologist. Dizziness and lightheadedness are among the common symptoms in otosclerosis patients, whose prevalence has been reported to be more than 30%. Disruption in the vestibular system is also seen in balance tests in a high percentage of patients (10). Different causes such as vestibular neuritis, reduction of Scarpa's ganglion cells (11) and also biochemical changes in endolymph have been mentioned as reasons for this problem (12). Another possible reason is the possibility of labyrinth anomalies, which has been mentioned in few studies (5, 13). This study shows the high prevalence of enlarged vestibular aqueduct in these patients, which can be helpful in explaining the cause of dizziness in some of these patients.

The considerable prevalence of enlarged vestibular aqueduct in otosclerosis patients in this study can justify CT scan before surgery. In a study by Shin et al., the prevalence of sclerotic foci was estimated at 92.2% (14). In the study of Marx et al., the diagnostic sensitivity of CT scan in otosclerosis was reported to be about 95.1%. However, due to the high clinical diagnostic accuracy of otosclerosis, some studies have recommended only CT scan in suspected cases of anomalies and other auditory conduction disorders (15). Cerebrospinal fluid gusher (CSF gusher) during cochlear implant surgery is more common in people with enlarged vestibular aqueduct (7). Stapedotomy surgery in patients with enlarged vestibular aqueduct has a higher risk of hearing loss after surgery due to the risk of cerebrospinal fluid gusher (13). Therefore, it is important to pay attention to this anomaly in the CT scan before surgery.

In the present study, the sensory component in patients with enlarged vestibular aqueduct was significantly higher than other patients with normal vestibular aqueduct. It seems that in otosclerosis patients with mixed hearing impairment, it is more important to pay attention to the CT scan and examine the condition of the vestibular aqueduct. It has been shown in many studies that in adults, due to the phenomenon of third window syndrome, the conduction component, especially in low frequencies, occurs in almost all cases of patients with enlarged vestibular aqueduct, and this disease is included in the differential diagnosis of otosclerosis and should be considered in imaging (15).

The use of modern imaging techniques such as high-resolution CT scan in diagnosis, pre-operative evaluations and post-operative follow-ups in patients with otosclerosis allows doctors to diagnose and treat the disease with more certainty and more accurately. In addition, these evaluations are very helpful in choosing the appropriate treatment approach in patients with hearing loss and specifically in patients with otosclerosis. Accurate imaging can be used even in cases of unsuccessful surgical treatment of otosclerosis or hearing loss following successful surgery, in order to better understand possible causes. Along with the advancement of technology, providing a higher resolution CT scan for accurate anatomical diagnosis can be more helpful.

One of the limitations of the study is that the study is not double-blind, especially in the case of the measuring radiologist compared to the cases of the case and control groups. Also, CT scans with higher resolution can increase the diagnostic accuracy of future studies.

Based on the results of this study, the prevalence of wide vestibular aqueduct in patients with otosclerosis is significant, and it is better to pay enough attention to the CT scan of patients before surgery to prevent possible complications.

### **Acknowledgment**

The financial support by the Research and Technology Vice-Chancellor of Mashhad University of Medical Sciences and the scientific and statistical consultation of the Clinical Research Development Unit of Qaem Hospital are hereby acknowledged.

## References

1. Kiakojori K, Monadi M, Khodadoost A, Soltanparast S, Sheykhzadeh M, Khafri S. Evaluation of the Audiological Characteristics of Patients with Otosclerosis Referring to the Ear, Nose, and Throat Clinics of Babol City, Iran. *J Babol Univ Med Sci*. 2016;18(4):67-72. [In Persian]
2. Wichova H, Alvi S, Boatright C, Ledbetter L, Staecker H, Lin J. High-Resolution Computed Tomography of the Inner Ear: Effect of Otosclerosis on Cochlear Aqueduct Dimensions. *Ann Otol Rhinol Laryngol*. 2019;128(8):749-54.
3. Amali A, Mahdi P, Karimi Yazdi A, Khorsandi Ashtiyani MT, Yazdani N, Vakili V, et al. Saccular function in otosclerosis patients: bone conducted-vestibular evoked myogenic potential analysis. *Acta Med Iran*. 2014;52(2):111-5.
4. Conway RM, Sioshansi PC, Babu SC, Tu NC, Schettino AE, Schutt CA. Audiologic comparison of classification systems of advanced otosclerosis. *Am J Otolaryngol*. 2022;43(5):103516.
5. Wieczorek SS, Anderson Jr ME, Harris DA, Mikulec AA. Enlarged vestibular aqueduct syndrome mimicking otosclerosis in adults. *Am J Otolaryngol*. 2013;34(6):619-25.
6. Gopen Q, Zhou G, Whittemore K, Kenna M. Enlarged vestibular aqueduct: review of controversial aspects. *Laryngoscope*. 2011;121(9):1971-8.
7. Alahmadi A, Abdelsamad Y, Salamah M, Alenzi S, Badr KM, Alghamdi S, et al. Cochlear implantation in adults and pediatrics with enlarged vestibular aqueduct: a systematic review on the surgical findings and patients' performance. *Eur Arch Otorhinolaryngol*. 2022;279(12):5497-509.
8. Flint PW, Haughey BH, Lund VJ, Robbins KT, Regan Thomas J, Lesperance MM, et al. Cummings otolaryngology: Head and neck surgery, 3-volume set, 7<sup>th</sup> ed. Philadelphia: Elsevier; 2020. p. 2204.
9. Spencer CR. The relationship between vestibular aqueduct diameter and sensorineural hearing loss is linear: a review and meta-analysis of large case series. *J Laryngol Otol*. 2012;126(11):1086-90.
10. Rajati M, Jafarzadeh S, Javadzadeh R, Disfani MF, Yousefi R. Comprehensive vestibular evaluation in patients with Otosclerosis: a case control study. *Indian J Otolaryngol Head Neck Surg*. 2022;74(4):582-7.
11. Saim L, Nadol Jr JB. Vestibular symptoms in otosclerosis--correlation of otosclerotic involvement of vestibular apparatus and Scarpa's ganglion cell count. *Am J Otol*. 1996;17(2):263-70.
12. Derks W, De Groot JA, Raymakers JA, Veldman JE. Fluoride therapy for cochlear otosclerosis? an audiometric and computerized tomography evaluation. *Acta Otolaryngol*. 2001;121(2):174-7.
13. Távara-Vieira D, Miller S. Misdiagnosis of otosclerosis in a patient with enlarged vestibular aqueduct syndrome: a case report. *J Med Case Rep*. 2012;6(1):178.
14. Shin YJ, Deguine O, Cognard C, Sévely A, Manelfe C, Fraysse B. [Reliability of CT scan in the diagnosis of conductive hearing loss with normal tympanic membrane]. *Rev Laryngol Otol Rhinol (Bord)*. 2001;122(2):81-4.
15. Marx M, Lagleyre S, Escudé B, Demeslay J, Elhadi T, Deguine O, et al. Correlations between CT scan findings and hearing thresholds in otosclerosis. *Acta Otolaryngol*. 2011;131(4):351-7.